AN ABSTRACT OF THE THESIS OF

Dawn Marie Alapisco for the degree of Honors Baccalaureate of Science in Anthropology presented on June 5, 2012. Title: The Skeleton in the Closet: An Historic Forensic Case from Scio, Oregon.

Abstract approved:

_____

Melissa Cheyney

Abstract Body

In August of 2011, Jenny Minten came across an old coffin, complete with a skeleton, in the Independent Order of Odd Fellows (IOOF) Scio lodge. After it was determined that the skeleton did not represent a modern forensic case, the remains were donated to the Oregon State University Anthropology Department. Utilizing a multi-disciplinary anthropological approach involving historic- and pre-historic archaeology and osteology, the analysis of this individual had many significant findings. The casket was dated to 1855-1870, the bones were preserved in an arsenic heavy solution, and the skeleton had likely been used as a medical model. This skeleton was determined to be male, over 40 years old at time of death, of European ancestry, and between 5’7” and 5’10” in height. The individual likely died of tuberculosis as determined by lytic lesions on the skeleton. An interesting aspect of this project involved learning the history of the IOOF and exploring the possible answers to the questions of how and why the remains were in a closet. The oral histories obtained state that the remains had been used in rites that are a symbolic acceptance of one’s own mortality.

Key Words: historic, forensic, osteology, pathology, tuberculosis, skeleton, coffin Independent Order of Odd Fellows, bones
alapiscd@onid.orst.edu

The Skeleton in the Closet:

An Historic Forensic Case from Scio, Oregon

By

Dawn Marie Alapisco

A PROJECT

submitted to

Oregon State University

University Honors College

in partial fulfillment of
the requirements for the
degree of

Honors Baccalaureate of Science in Anthropology (Honors Associate)

Presented June 5, 2012
Commencement June 2012

Honors Baccalaureate of Science in Anthropology project of Dawn Marie Alapisco presented on June 5, 2012.

APPROVED:

_____

Mentor, representing Anthropology

_____

Committee Member, representing Anthropology

_____

Committee Member, representing Professional Medical Examiner

_____

Director, School of Language, Culture, and Society

_____

Dean, University Honors College

I understand that my project will become part of the permanent collection of Oregon State University, University Honors College. My signature below authorizes release of my project to any reader upon request.

_____

Dawn Marie Alapisco

Acknowledgements

There are so many people that I need to thank. First my family for supporting me, even when they had no clue why I was doing what I was doing; especially Little Miss Monster (my biggest cheerleader) and Jason, who has been the solid ground beneath my feet and the soft landing spot for those nasty bumps in the road; and who took an on the job crash course in osteological photography for this project. YOU are the reason I have been able to do this.

I wish to thank Dr. Brauner for giving me the opportunity to learn archaeology in a real world setting; even when he wasn't quite sure I was really up to the challenge. I need to thank Mollie Manion and Jamie French, for teaching me the lab procedures that have enabled me to further my education in a direction that I truly love and for giving me a chance in the field. I also need to thank Jamie separately for her work in dating the coffin.

I wish to thank Dr. Cheyney for everything that she has done; all of the guidance, encouragement, lab time and resources, and gifting me with the knowledge and love of Human Osteology…I look forward to the next chapter! I also wish to thank her for introducing me to the "Lab-Ladies", because their encouragement and accomplishments have made me reach higher and try harder. Thank you all so much for your wisdom, support, role-modeling, and the Monday night writing meetings!!!

I wish to thank Jennifer Schindell for choosing OSU as the recipient of "The Skeleton in the Closet". Seriously, you made my YEAR!!! You have also given great insight and guidance throughout this project, which has been greatly appreciated!

I want to thank Alex Nyers for his help with the PXRF gun. The chemical analysis of the preservative was invaluable to this project.

To the 2011-2012 Osteology Students and Interns: Lauren C., Amy, Matthew, Jamie, Angela, Alex H., Aleks J., Lauren M., Shannah, Lindsay, and Jess; You are an amazing bunch

of capable young men and women who have enriched my life in so many ways…The candy dish will always be full!

I wish to thank the UHC for the opportunity to gain this experience, and for funding my project.

And lastly, but in many ways most importantly, I wish to thank “Amadeus” for keeping me company so many nights through this project. You suffered greatly in life, and I only hope that you feel I have treated you respectfully in death.

TABLE OF CONTENTS

TABLE OF CONTENTS

List of Figures

Figure **Page**

This thesis is dedicated to my father, Alfred Alapisco, who would have loved to have lived to see this day. You are greatly missed.

The Skeleton in the Closet: An Historic Forensic Case from Scio, Oregon

We have all heard of the proverbial skeleton in the closet. But, what happens when that phrase goes from the metaphorical to the literal? On August 23, 2011, that is exactly what happened to Lindy and Jenny Minten while cleaning the Scio, Oregon Odd-Fellows Lodge. After discovering a coffin in a closet, complete with skeleton, Jenny promptly called her mother. The coffin, a known prop in Independent Order of Odd Fellows (IOOF) ceremonies (Andrews-Lynn 2012; J. Minten 2011; L. Minten 2012), was expected to have plastic bone replicas used for initiation ceremonies. However, what was found was quite the opposite. The coffin contained an almost complete set of human remains, with evidence of an autopsy cut on the skull (J. Minten 2011). The moldy human bones were disarticulated and covered with a thick layer of dried mud that also lined the bottom and sides of the coffin. The mud resulted from the 1962 Columbus Day Storm that flooded the IOOF building.

Lindy called the local law enforcement. When reporting the find, the dispatcher did not initially take Lindy seriously, responding to her initial report of: “I have a skeleton in the closet,” with: “We all do” (L. Minten 2012). Once the dispatcher realized she was serious, a Linn County Detective came out to investigate. The Medical Examiner directed the Linn County Detective to transport the coffin and skeleton to the Sherriff’s evidence locker for further examination (see figure 1). Jennifer Schindell, Oregon State University Anthropology Department graduate student, Registered Nurse and Linn County Deputy Chief Medical Examiner (CDME), conferred with the Detective, the State Medical Examiner’s Office (ME), and a local forensic

anthropologist. Initial investigations were conducted to rule out the possibility that the case involved criminal activity, homicide, or suspicious death. Due to the fact that the remains did not appear to be of contemporary forensic significance and did not appear to be Native American, the Medical Examiner's Office released jurisdiction; and thus the case would not be investigated further (Schindell 2012).

Figure 1: The coffin in the Linn County Sherriff's Department evidence locker. ***(Photography by Mark Ylen)***

As the case was not going to be further investigated as a suspicious death case, and Oregon Health and Science University Demonstrator of Anatomy declined donation of the remains, the coffin and remains were donated to the Oregon State University (OSU) Osteology Laboratory in the Department of Anthropology. Jennifer Schindell arranged the donation with the approval of the Independent Order of Odd Fellows Grand Master of Oregon. Susan Shaw, the Director of the School of Language Culture

and Society at OSU where the Anthropology Department is housed, coordinated these efforts.

A Short History of The Independent Order of Odd Fellows

The Independent Order of Odd Fellows (IOOF) is a secretive fraternal organization that began in England at the turn of the 18th century as a group of men wanting to contribute to the "benefit of mankind" (Independent Order of Odd Fellows 2012). They took their name from the moniker given to them for their philanthropic selflessness that was often seen as impractical: "an odd bunch of fellows". Also known as the "Three Link Fraternity" -- named for their logo of three intertwined rings -- their philosophies are steeped in the values of friendship, love, and truth (Independent Order of Odd Fellows 2012).

In 1819, the first American lodge opened in Baltimore, Maryland. The foundation of the Odd Fellows' ideology was to come together as a community to help each other in times of need. Because Baltimore was in the midst of a yellow fever epidemic and was also suffering the effects of high unemployment, the American lodge decided to dedicate the organization to "visit the sick, relieve distress, bury the dead, and educate the orphans" (Independent Order of Odd Fellows 2012). This dedication to ensuring that the deceased were buried lead to them being known as "keepers of the dead" (L. Minten 2012). In 1848 a lodge was set to be opened in Oregon City, Oregon, though that lodge actually ended up opening in Hawaii after a miscommunication regarding travel arrangements occurred. In 1852, the organization opened its first permanent lodge in the Pacific Northwest in Salem, Oregon, the Chemeketa Lodge No.1. The Salem lodge became known as the "mother lodge" and furthered the

objectives of the organization, offering aid and assistance to its members in times of need (Salem Public Library 2012).

The Portland Lodge, or "Grand Lodge", was formed in 1856 and became the parent lodge to Scio, which was created in the late 19th century. A *Democrat-Herald* news story states that the Scio lodge was formed in 1856 (Knepper 2011), though the exact date is unknown. No records providing details or confirming the formation date have been found, and oral histories do not contain this information. Oral histories of the IOOF organization do discuss the gifting of initiation regalia and paraphernalia to new lodges from their parent lodge as they opened, or received their charter, and the Portland Grand Lodge was likely to have perpetuated this tradition to the Scio lodge (L. Minten 2012). The original Scio Lodge building was destroyed in the flooding produced by the 1962 Columbus Day Storm, and according to the oral history of lodge members, was "rebuilt on the same spot immediately" (Knepper 2011). The coffin in question had been rescued, placed in the new building, and promptly forgotten (Knepper 2011). Skeletons and coffins are used in initiation rites by the lodge, though the coffin and bones found by Lindy Minten had not been employed for such purposes in living memory. Odd Fellows' rituals of initiation are designed to communicate the acceptance of one's own mortality along with the desire to rise above the reality of impending death and to do something good for the community and for humankind (Andrews-Lynn 2012; J. Minten 2011; L. Minten 2012). While the initiation rites involving the use of human skeletons are still considered secret within the IOOF organization, the IOOF members in no way contribute to or engage in destruction of human remains. The Odd Fellows continue to pursue many philanthropic activities and projects including

providing scholarships, summer camps for diabetic children, homes for abuse survivors, international medical aid, and a host of other worthwhile causes (Oregon IOOF 2012).

Osteological Methods and Analyses

Cleaning and Initial Evaluation

My involvement with this case as part of my Honors College research began with the recruitment and supervision of laboratory interns from a recent Human Osteology class who aided in the cleaning of skeletal remains. The method used in cleaning the remains was dependent on the integrity of the bone (see figure 2). The initial methods were determined according to guidelines provided by White and Bass -- standards in the field (Bass 2005; White et al. 2012).

All of the long bones and most of the irregular bones were cleaned using water and soft toothbrushes. The more fragile bones of the skull, scapulae, and innominates were in no condition to be submerged in water, and were thus, surface cleaned with a washcloth and warm water. The remains were then recorded using forms from the Arizona State Museum Human Skeletal Remains Forms (Bioarchaeology Lab of the Arizona State Museum 2004), a condensed version of the industry benchmark *Standards for Data Collection in Human Skeletal Remains (Standards)* (Buikstra and Ubelaker 1994). After the initial recording, it was determined that the remains displayed many pathologies and a more thorough write up was needed. Following cleaning and a comprehensive analysis of the remains and accompanying casket (described below), the remains have been curated in a set of locked drawers in OSU's Osteological Laboratory. Photography of all remains was performed using a digital camera, tripod, black velvet backdrops, and bone pillows, following guidelines provided by White et al. (2012).

Figure 2: The skeletal remains as they were removed from the coffin and laid out on trays in preparation for cleaning in the OSU Biocultural Lab. ***(Photography by Jason Neiss)***

Skeletal Inventory

Minimum Number of Individuals or MNI was determined to be one individual. There are no duplicate bones, all bones found correspond or articulate with the other bones of this individual, and there are no developmental differences in the bones (White et al. 2012). See appendix B for an inventory of all bones present.

Missing Bones

This individual is over 90% complete with a relatively small number of missing elements. All of the missing bones are small bones, and it is likely that they are absent postmortem in connection with the 1962 Columbus Day storm and flood

that also introduced the mud and debris found within the coffin. Absent elements include:

Ear ossicles (the right malleus and right and left stapes)

Inferior nasal conchae

Hyoid

Manubrium

Sternum

Xyphoid

Right and Left 12th rib

Right and Left lunates, trapezia, trapezoids

Left triquetral

Right pisiform

3 intermediate phalanges (hand)

9 distal phalanges (hand)

Coccyx

2 proximal phalanges (foot)

8 intermediate phalanges (foot)

8 distal phalanges (foot)

Context and Condition

The remains found were fully skeletonized and disarticulated, covered in a thick layer of mold and mud. They were in the coffin with no semblance of

organization, just a “set of bones in a box” (Knepper 2011). Most of the skeleton is present (see list of missing bones above) with many bones being fully intact, while others show significant damage (see appendices B, J - AC). The skull is complete with a complete, anteroposterior, postmortem section creating a calotte. The cut appears to be relatively rudimentary, as it did not completely slice the frontal at the right sinus or at the left parietal just posterior to the coronal suture. The cut is also crooked. The right zygomatic was found with a long piece of twine attached and looped through the zygomatic arch. The twine was removed to clean the skull and to allow for complete analysis. The right nasal bone has a 2 x 8 mm anterosuperior, postmortem slit in it.

The manubrium, sternum, and xyphoid are absent postmortem. There were 22 of the 24 expected ribs in the coffin (12th rib on each side missing). The ribs on both sides have significant damage; many having been cut, with the right, fourth rib showing incomplete cut marks. None of the cut portions from the left ribs were found, but there are five fragments from the right ribs that were identified, matched to their rib of origin, and numbered. An Odd Fellows skeleton found in Houston, Missouri in June of 2004, under similar circumstances, also had many sternal end fragments missing (Lakey and Walker 2007). With two skeletons used in the same manner displaying this trait, this begs the question of “Why?” Autopsy seems to be the most likely answer as the orientation of the cuts on the ribs are consistent with at least one common method of autopsy (Valdes 2012) and although the Lakey and Walker skeleton likely was not used as a medical model (Lakey and Walker 2007), it likely had a postmortem autopsy that would have produced the sternal end cuts.

The vertebrae show significant damage (see appendix J). The cervical vertebrae are missing most of the transverse foramina, but otherwise display minimal loss of cortical bone. The thoracic vertebrae exhibit moderate transverse process, spinous process, and vertebral body cortical bone loss, and all five of the lumbar vertebrae are missing both transverse processes and have minor cortical bone flaking associated with postmortem damage.

All of the arm and shoulder girdle bones were present. The clavicles have mild cortical damage. The scapulae have pieces broken out of the subscapular fossae and damaged inferior angles, the right having the most damage (see appendix M). The most significant finding upon examination is that the right distal humerus, proximal radius, and proximal ulna evidence significant pathological bone development (discussed in more detail below). The only significant finding from the carpals, metacarpals, and phalanges is that the base of the right fifth metacarpal (RMC 5) has significant pathological lesions. As noted above, several carpals and phalanges are absent (See appendices Z and AA).

The most fragile of the remains are the innominates; both have severe damage to the pubic symphyses, ischiopubic rami, and auricular surfaces with the left having significant damage to the iliac crest as well (see figure 11, and appendices L and M). The sacrum is missing most of the auricular surface on both sides, as well as the spinous processes (see figure 12). The femurs, tibiae, and fibulae all have excellent cortical bone integrity. The patellae, tarsals, metatarsals, and most of the phalanges were present. The right fibula has pathological lesions on the shaft at the distal end.

The left calcaneus, left intermediate cuneiform, and right hallux have minor cortical bone flaking. The right first distal phalange has significant damage to the distal phalangeal tubercle, and all of the inferior cortical bone is missing.

Associated Funerary Objects

There were only two associated funerary goods: the coffin the remains were found in and the twine found tied to the right zygomatic. Utilizing data from the Alpowa Village Cemetery, the coffin hardware (screws and finials only) was dated from 1855 to 1870 (French 2012). Coffins, as opposed to caskets, are six or eight sided and conform to the contours of the human form; caskets are rectangular (Lundgreen 2012). The coffin was built in three parts, a base with walls and two lid portions: a small upper lid and a longer lower lid. The coffin, while sustaining significant water damage from the 1962 Columbus Day Storm, is otherwise in fair condition. There is obvious mold staining on the exterior, which has affected the finish, and due to age and the conditions in which it had been kept, the finish has other imperfections. The interior has significant water damage to the cloth and lace lining, and still contains a significant amount dirt and mold from the flood (see figure 3). The longer lid portion has a crack in the top, but the overall structural integrity of the vessel is intact. There is some rust and oxidation on the metal hardware and caked dirt on the external base of the coffin, but the coffin exhibits no signs of having ever been buried. The majority of the metal embellishments still have a shiny silver patina, the wood is structurally intact, and the finish retains some of its sheen.

The dimensions of the coffin at the largest portions of the external base are 54” long x 16“ wide x 9” deep. Internally, the dimensions at the largest aspects are 52.5” long x 13.25” wide x 8.25” deep. Upon consulting with a funeral home, the coffin was assessed to be child-sized with a modern adult casket having standardized, internal dimensions of 84” long x 28” wide x 23” high. A modern coffin would have the same maximum dimensions, although coffins are rarely used in the United States today. The largest child-sized casket made by a local company has an internal length of 60”; this coffin, being 7.5 inches shorter, even accounting for changes in population height, would almost certainly have been intended for a child (Lundgreen 2012).

Figure 3: Image of the inside of the coffin showing the conditions the skeletal remains had been kept in. ***(Photography by Jason Neiss)***

The twine found tied to the right zygomatic has been speculated to have been used for ceremonial masks in previously analyzed Odd-Fellows skeletons (Lakey and Walker 2007), and the *DeMoulin Bros. & Co.* (Phoenixmasonry Masonic Museum and Library 2011) catalog contains a section for masks of various types that could be purchased for ritual use (see figure 4). Interestingly, an initiate into the Canby, Oregon Odd Fellows Lodge remembers a mask being used on the skeleton presented to him during their initiation ceremony (Andrews-Lynn 2012).

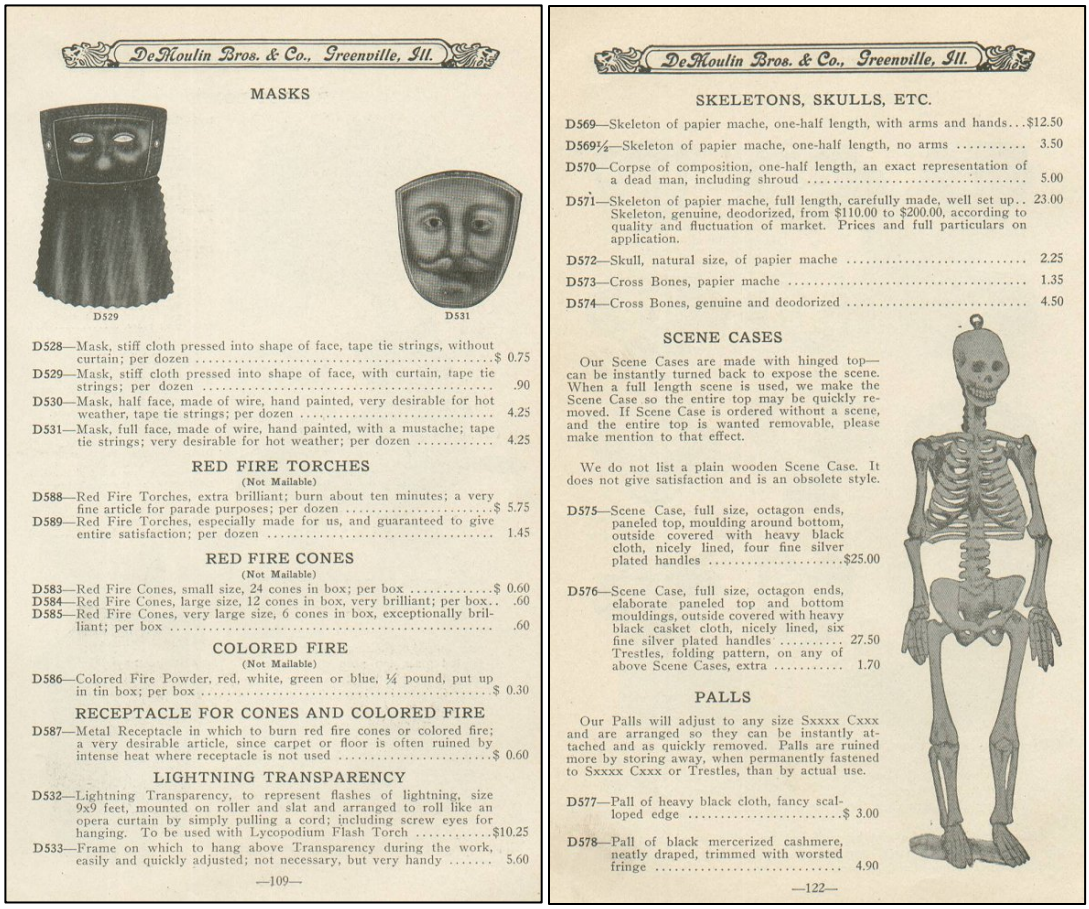

DeMoulin Bros. & Co., Greenville, Ill.

MASKS

D529 D531

D528—Mask, stiff cloth pressed into shape of face, tape tie strings, without curtain; per dozen ..... $ 0.75
D529—Mask, stiff cloth pressed into shape of face, with curtain, tape tie strings; per dozen ..... .90
D530—Mask, half face, made of wire, hand painted, very desirable for hot weather, tape tie strings; per dozen 4.25
D531—Mask, full face, made of wire, hand painted, with a mustache; tape tie strings; very desirable for hot weather; per dozen 4.25

RED FIRE TORCHES
(Not Mailable)

D588—Red Fire Torches, extra brilliant; burn about ten minutes; a very fine article for parade purposes; per dozen ..... $ 5.75
D589—Red Fire Torches, especially made for us, and guaranteed to give entire satisfaction; per dozen 1.45

RED FIRE CONES
(Not Mailable)

D583—Red Fire Cones, small size, 24 cones in box; per box ..... $ 0.60
D584—Red Fire Cones, large size, 12 cones in box, very brilliant; per box.. .60
D585—Red Fire Cones, very large size, 6 cones in box, exceptionally brilliant; per box ..... .60

COLORED FIRE
(Not Mailable)

D586—Colored Fire Powder, red, white, green or blue, ¼ pound, put up in tin box; per box ..... $ 0.30

RECEPTACLE FOR CONES AND COLORED FIRE

D587—Metal Receptacle in which to burn red fire cones or colored fire; a very desirable article, since carpet or floor is often ruined by intense heat where receptacle is not used ..... $ 0.60

LIGHTNING TRANSPARENCY

D532—Lightning Transparency, to represent flashes of lightning, size 9x9 feet, mounted on roller and slat and arranged to roll like an opera curtain by simply pulling a cord; including screw eyes for hanging. To be used with Lycopodium Flash Torch $10.25
D533—Frame on which to hang above Transparency during the work, easily and quickly adjusted; not necessary, but very handy 5.60

—109—

DeMoulin Bros. & Co., Greenville, Ill.

SKELETONS, SKULLS, ETC.

D569—Skeleton of papier mache, one-half length, with arms and hands... $12.50
D569½—Skeleton of papier mache, one-half length, no arms 3.50
D570—Corpse of composition, one-half length, an exact representation of a dead man, including shroud 5.00
D571—Skeleton of papier mache, full length, carefully made, well set up.. 23.00
Skeleton, genuine, deodorized, from $110.00 to $200.00, according to quality and fluctuation of market. Prices and full particulars on application.
D572—Skull, natural size, of papier mache 2.25
D573—Cross Bones, papier mache 1.35
D574—Cross Bones, genuine and deodorized 4.50

SCENE CASES

Our Scene Cases are made with hinged top—can be instantly turned back to expose the scene. When a full length scene is used, we make the Scene Case so the entire top may be quickly removed. If Scene Case is ordered without a scene, and the entire top is wanted removable, please make mention to that effect.

We do not list a plain wooden Scene Case. It does not give satisfaction and is an obsolete style.

D575—Scene Case, full size, octagon ends, paneled top, moulding around bottom, outside covered with heavy black cloth, nicely lined, four fine silver plated handles $25.00

D576—Scene Case, full size, octagon ends, elaborate paneled top and bottom mouldings, outside covered with heavy black casket cloth, nicely lined, six fine silver plated handles 27.50
Trestles, folding pattern, on any of above Scene Cases, extra 1.70

PALLS

Our Palls will adjust to any size Sxxxx Cxxx and are arranged so they can be instantly attached and as quickly removed. Palls are ruined more by storing away, when permanently fastened to Sxxxx Cxxx or Trestles, than by actual use.

D577—Pall of heavy black cloth, fancy scalloped edge ..... $ 3.00

D578—Pall of black mercerized cashmere, neatly draped, trimmed with worsted fringe 4.90

—122—

Figure 4: Image shows the 1930 *DeMoulin Bros. & Co.* catalog entries for ceremonial masks and skeletons. Note the availability of genuine cross bones.

Figure 5: Image of the full body layout. ***(Photography by Jason Neiss)***

Skeletal Pathologies, Anomalies, and Trauma

Upon complete inspection, there is no evidence of healed fractures or traumas, though radiographs were not performed. There is an overall rugosity to the remains that speaks to a high level of muscularity, and therefore, activity in life (Byers 2008). The epiphyses and metaphyses of the long bones have a visible degree of macro-cortical bone porosity. Mild osteoporosis is also evident in the thoracic and lumbar regions of the vertebral column.

Skull

The parietals have partially healed lytic lesions. The right side is smaller, with less healing, indicating potential infection at the time of death. The right parietal lesion is 2.5 mm wide x 3 mm high (see figure 6), and the left lesion is 5 mm wide and 7 mm wide. Part of the lesion on the left side along the squamosal suture likely occurred in relation to the autopsy cut.

Figure 6: Image of the section and lytic lesion on the right parietal. ***(Photography by Jason Neiss)***

The maxillae show signs of chronic sinusitis, both sides evidencing abnormal bone growth along the external aspects of the nasal sinuses on the splanchnocranium (see figure 7.1). The right maxilla has significant internal lesions within the nasal cavity. There are cortical bone lesions on both the right and left maxillae, just lateral to the nasomaxillary suture, with the right side showing a more significant reaction. The maxillary palate has shallowed, with bony lesions invading alveolar spaces (see figure 7.2). The right palate shows severe lytic reaction and thinning, and the medial aspect displays a pathological lesion with complete destruction of the cortical bone. There are

hypertrophic muscle attachment sites infraorbitally on both the maxillae and zygomatics (see figure 7.1).

Figure 7: 7.1 Left image shows cortical bone changes at the maxillary sinuses. The infraorbital hypertrophic muscle attachment sites can also be seen. 7.2 Right image shows lytic destruction of the palate. *(Photography by Jason Neiss)*

The right mandible has a lingual abscess at the location of the right mandibular second molar (RM_2). There are only four teeth left in the mandible and no intact teeth in the maxillae (see appendices D and E). Two additional teeth, the right and left maxillary third molars, were found loose within the coffin. There is significant antemortem and postmortem tooth loss in addition to obvious signs of dental disease including caries and calculus on the teeth present: the right mandibular third molar, the left mandibular first, second, and third molar. Both the mandible and maxillae exhibit alveolar resorption. The right mandibular first and second incisors have significant alveolar resorption, as do the first and second molars on both the right and left maxillae, and the left maxillary second incisor. This individual had a very pronounced underbite with apparent concomitant dental malocclusion. The mastoid processes are very large and rugose, and the external occipital protuberance and crest are

pronounced, suggesting that the individual is male (sexing of the skeleton is described in greater detail below). There are periosteal and lytic lesions on the posterior aspect of the maxillae with the right side showing partial destruction of the thin cortical surface.

Vertebrae

The vertebral column shows significant pathologies with osteoarthritis, tuberculosis, and possibly the beginnings of osteoporosis. The cervical vertebrae exhibit an abnormally pronounced anterior curvature, as well as showing signs of fusion. The first and third cervical vertebrae (C-1, C-3) have the left transverse foramen, the fourth cervical vertebra (C-4) has both transverse foramen, and the fifth cervical vertebra (C-5) has the right transverse foramen; all other transverse foramina are absent due to postmortem fragmentation. The excessive curvature would have left this individual with an abnormal cranial angle, and would have likely been debilitating in life. The thoracic vertebral spinous processes have osteophytes indicating a high level of physical, occupational activity and early osteoarthritis (Byers 2008; Waldron 2009). Initially, upon analyzing the thoracic vertebrae, scoliosis was the first and most likely pathology considered (Ortner 2003). Upon further inspection and rearticulation of the thoracic vertebral column, however, no visible lateral curvatures could be identified, though it is still possible, even likely, that there was some in life. Scoliosis explains the angles seen in the spine (Ortner 2003), and the degree of curvature is likely underestimated due to the absence of soft tissue. The lumbar vertebrae have osteophytic development on the bodies, and the fifth lumbar (L-5) has an inferior

vertebral body cavitation (see figure 8) in the cancellous bone without extensive damage to the surrounding cortical bone or spinous processes. The cavitation in the trabecular bone of the vertebral body without vertebral collapse and no proliferation to the posterior aspect of the vertebra is indicative of proliferative, osseous tuberculosis-arthritis (Ortner 2003). In a study from 1964, involving 62 autopsied individuals with vertebral tuberculosis, L-5 was the second most common vertebra affected, after the third lumbar (L-3) (Ortner 2003). The thoracic and lumbar vertebra also have Schmorl's Nodes, from the 6th thoracic (T-6) through L-5, which indicates a degenerative change associated with the beginning of ostophytic formation and an occupation that included heavy labor (Buikstra and Ubelaker 1994; Byers 2008).

Figure 8: Inferior aspect of L-5 with tuberculosis cavitation and osteophytes. ***(Photography by Jason Neiss)***

Ribs

There are no significant pathologies noted in the ribs. The left side has one partial sternal end on the 10th rib; most of the rest were cut postmortem and poorly preserved. Most of the right ribs have been cut; there are five right rib fragments that have been matched and numbered. The right fifth and seventh sternal fragments have partial sternal ends that are too poorly preserved to use in age estimations. The right fourth sternal fragment has incomplete cut marks, or false starts (Byers 2008). The articular surfaces of all of the ribs are in very poor condition, with most of the heads and tubercles displaying some bone loss. While siding is still possible, numbering

using the vertebral articular facets with the rib heads and vertebral transverse processes with rib tubercle articulation points could not be accomplished due to poor preservation. Numbering has been completed using guidelines set out by White et al. (2012). There are sternal fragments for the right third, fourth, fifth, seventh, and eighth ribs. Incidentally, the sixth rib on the right side is the only rib to show no signs of cutting, but the sternal end has severe damage due to the poor preservation conditions related to the 1962 flood.

Shoulder Girdle, Arms, and Hands

The clavicles and scapulae have no significant pathologies. Both have cortical bone loss that can be attributed to the conditions of their storage. No significant pathologies were noted on the left humerus, radius, ulna, carpals, metacarpals, or phalanges. The coronoid fossa of the left humerus evidences an unnatural waxy substance (see figure 9) that we suspected was related to an historic preservation technique used in scientific models. We used Portable Field X-ray Florescence (FPXRF) (Kalnicky and Singhvi 2001) to analyze the substance and found high concentrations of arsenic and lead. The FPXRF analysis was conducted on the left humerus in the coronoid fossa, on the shaft, the left femur on the shaft, the right first rib, and using bones of a known date from outside of this skeleton. All of the bones from this individual tested positive for arsenic, with the waxy substance build up in the coronoid fossa having the highest concentrations at about 1.5% (Nyers 2012), the control did not have any arsenic. Arsenic is a known preservative in funerary and preserving practices from the mid-19th century (Civil War Era) until around 1910 in

the United States (Konefes and McGee 2001). The skeleton found in Missouri was noted to have a “sticky substance” on the long bones -- another similarity in these cases (Lakey and Walker 2007). In addition, the left distal humerus at the metaphysis and ulna lateral to the semilunar notch evidences human-made, postmortem drill holes likely used to articulate the these remains perhaps for ceremonial purposes. Alternatively, the holes and arsenic and lead laden preservative could indicate the skeleton’s use as teaching or scientific model prior to its acquisition by the Odd Fellows.

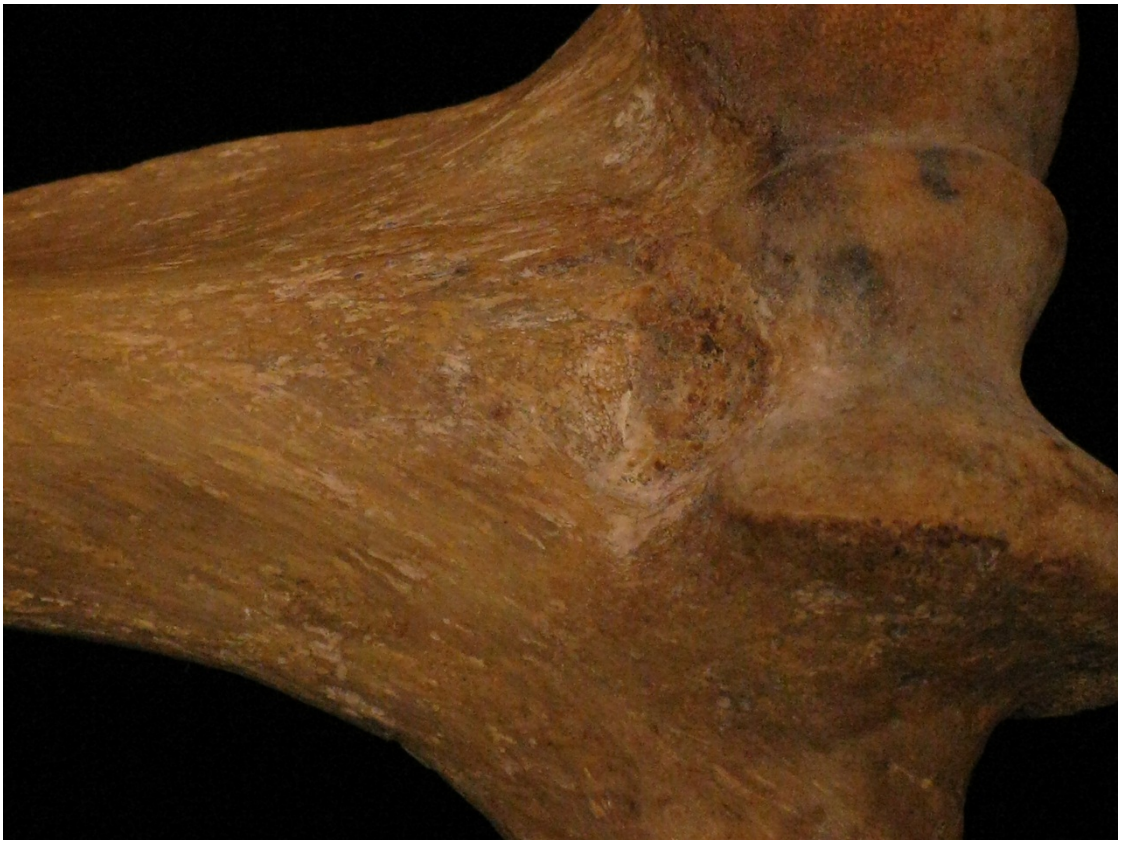

Figure 9: Image of the left coronoid fossa with a buildup of waxy arsenic laced preservative. ***(Photography by Jason Neiss)***

The right humerus, radius, ulna, and fifth metacarpal (RMC 5) have significant pathological findings. The degree of cancellous bone proliferation, cortical bone loss, osteophyte formation, and obliteration of the elbow joint involving the humerus and ulna is indicative of arthritic tuberculosis (Ortner 2003). The distal humerus is missing the trochlea and trochanter completely, and the semilunar notch of the ulna is extremely distorted (see figure 10.2). The proximal radius also has significant damage to the head and neck. In a study by Dr. Alfer, published in 1892, involving 1,752 cases of osseous tuberculosis, the elbow was the third most infected joint (Ortner 2003, 228). The Ulna also shows sequestra formation on the proximal end at the radial notch, an indication of secondary osteoarthritis in the destroyed joint (Ortner 2003, 230).

Figure 10: 10.1 The left image from *Identification of Pathological Conditions in Human Skeletal Remains* by Donald J. Ortner, 2003, shows a right elbow with joint damage from tuberculosis. 10.2 The right image shows similar damage to the skeleton found in Scio. *(Photography by Jason Neiss)*

Pelvic Girdle, Legs, and Feet

There is extensive damage to the sacrum and the innominates, as noted above (see figure 11 and 12), making identification of any pathologies almost impossible. With a tubercular lesion on the inferior aspect of L-5, it stands to reason that there may have been significant findings in the sacrum and innominates had they been in better condition. The areas that are absent on the left iliac crest and auricular surfaces of both innominates are areas of osseous tissue that the tuberculosis bacterium is known to occupy (Ortner 2003). It is possible that these bones were damaged during the course of the proliferative disease process allowing for a more fragile osseous state that would have accelerated the speed of deterioration, especially given the less than optimal preservation conditions of the remains.

Figure 11: Image of the damage to the left and right innominates, pictured from a superior angle. ***(Photography by Jason Neiss)***

Figure 12: Image of the posterior aspect of the sacrum. ***(Photography by Jason Neiss)***

The femurs, tibiae, fibulae, patellae, and tarsals are all present. They exhibit good overall cortical bone integrity and, other than mildew staining and residue from the waxy preservative manifesting in a chalky coating, are in relatively good condition. The right fibula has periosteal reactions on the medial aspect of the shaft and at the posterior distal end with mild osteophytic activity on the anterior portion of the distal end. The left calcaneus, left intermediate cuneiform, and right hallux have minor cortical bone flaking. The right first distal phalange has significant damage to the distal phalangeal tubercle, and all of the inferior cortical bone is missing. The missing cortical bone is most likely a result of flood damage. There are missing foot phalanges, as noted above and in the skeletal inventory sheets (see appendix B).

Age, Sex, Stature, Bio-geographic Origin

Age Estimation

This individual, despite being approximately 90% complete, is unfortunately missing most of the osteological aspects that are typically used in age estimations of skeletal remains. The one method of age estimation that can be fully utilized is cranial suture closure (Meindl and Lovejoy 1985). It is the least accurate method for age estimation, but the only unit of measurement available for this set of remains. Utilizing data methods from *Introduction to Forensic Anthropology* (Byers 2008), ectocranial suture closure was measured using a zero to three scale -- zero represents no suture closure, one is indicative of minimal suture closure, two represents significant suture closure, three represents complete obliteration of the cranial suture. The method, known as the Meindl and Lovejoy system, is also used in *Standards* and *Human Osteology* (Buikstra and Ubelaker 1994; White et al. 2012). Utilizing ten set points on the ectocranial sutures, the ten-point measurement score was 17 (see appendix C), or stage five out of six. The age range for stage five is 34 to 60, with a mean age of 49 (see figure 13). With such a large age range established, endocranial suture measurements were employed. Endocranial suture measurement only has three categories, early (20 to 34 years), middle (35 to 49 years), and late (50+ years). These remains display complete suture obliteration along the sagittal and coronal sutures and significant closure along the lamdoidal suture. These findings puts this individual into the late category with an age estimation of 50+. I did try to employ the palatal suture

method of age estimation as well, but the degree of pathology displayed on this individual's palate made this impossible (see figure 7.1). With a fair amount of certainty, this individual was $\geq$ 40 years of age at the time of death. An upper age estiimation for this individual is likely 65 years given the integrity of the cortical bone throughout, as well as the early stages of osteophytic development. In this analysis, accuracy is more important that precision.

Figure 13: Image of the Coronal and Lambdoidal sutures, the Sagittal suture has obliterated; all features that were utilized in the age estimation of this individual. ***(Photography by Jason Neiss)***

Sex

Atrributing sex to an individual can sometimes be difficult; morphologies can be ambigious or androgynous in some cases. The most reliable method for determing the sex of an individual involves using the pelvis to analyze sevral key sexually dimorphoc features. The pubis is analyzed for the presence of a ventral arc and degree of sub-pubic concavity, and the degree of concavity in the ischiopubic rami, and the width of the sciatic notches are also typicaly evaluated. However, in this case, most of these features could not be anayzed due to the condition of the innominates. The sciatic notches were intact and scored a four on a scale from one to five -- one being hyper feminine, three being ambiguous or indeterminate, and five being hyper masculine. Fortunately, this individual displayed some very sexually dimorphic cranial traits. This individual was determined to be male, with only one cranial trait not displaying as hyper masculine (White et al. 2012). The nuchal crest, mastoid processes (see figure 14), supraorbital margins, and glabella all scored a five on the above mentioned scale (see appendix C). The mental eminence scored a three, indeterminate, as the chin is somewhat pointed and has no real cleft to it. In addition, overall, the mandible is rugose, again suggesting that this individual is male.

Figure 14: Image of the mastoid process, note the length and rugosity; features that were used in the sex estimation of this individual. ***(Photography by Jason Neiss)***

Stature

Stature was determined using long bones and two variations of formulae. The first formula, known as the Trotter method, does not include the tibia because it has been noted that the measurements of the tibia do not properly account for the medial malleoulus and add 2-3 cm to stature estimates (White et al. 2012). The second method employed was not utilized in final analysis because, while it is a newer method, the results pertain to modern American populations with birth years after 1944 (Wilson et al. 2010). These estimations were done prior to the coffin and residue analyses which indicated that this individual died before 1910.

Only bones from the left side have been used for these estimates, as the right sided long bones have pathologies that distort their length. Calculations are performed in metric. The stature estimates in standard work out to approximately 5’7” to 5’10” (66.91 inches to 70.00 inches).

Bone	Length	Formula	Standard Deviation	Mean	Range
Humerus	33.2	3.08 (33.2) + 70.45	± 4.05	172.71	168.66 – 176.76
Radius	24.7	3.78 (24.7) + 79.01	± 4.32	172.38	168.06 – 176.70
Ulna	26.2	3.70 (26.2) + 74.05	± 4.32	170.99	166.67 – 175.31
Femur	45.6	2.38 (45.6) + 61.41	± 3.27	169.94	166.67 – 173.21
Fibula	38.1	2.68 (38.1) + 71.78	± 3.29	173.89	170.60 – 177.18

Table 1: Trotter stature estimate formulas and ranges.

Bio-Geographic Origin/Ancestry

The estimation of bio-geographic origin, “race” or ancestry from human skeletal remains is a contentious debate within physical anthropology today, largely because of the research indicating that there is more variation within so-called “race” groups than between (American Association of Physical Anthropologists 2012). To avoid controversy, Byer’s method of using the word “ancestry” will be utilized here (Byers 2008). There are traits that can distinguish an individual as being from a

particular genetic ancestry, thus biogeographic background for established ancestry can also be estimated, though this is only considered somewhat reliable (about 50% accurate, White et al. 2012) when a large sample size is attainable. Estimations of ancestry rely solely on cranial features and are considered questionable by most osteologists when a sample size of only one skull is used as in this case. Thus, the findings discussed below should be considered speculative.

This individual displays a high cranial vault, parabolic dental arcades, projecting mental eminence, a jagged palatine suture, and anglular orbits. The nasal features are very telling, exhibiting large nasal spines, a nasal sill, high steeple-like nasal bones, a narrow nasal aperture, and a depressed nasion. There are no signs of midfacial or alveolar prognathism. All observed cranial features are associated with White/European ancestry (Byers 2008; White et al. 2012).

Personal Identification, Time and Cause of Death

The circumstances under which this individual was found, and the history of the IOOF organization, give no clear indicators as to the identity of this individual. Oral histories and archival catalogs from *DeMoulin Bros. & Co.* show clear representations of "Regalia and Paraphernalia" used by the IOOF Lodges, including skeletons and coffins (Phoenixmasonry Masonic Museum and Library 2011). The 1930 catalog, one of the last printed, is reproduced in its entirety online and contains papier-mâché skeletons (Phoenixmasonry Masonic Museum and Library 2011). Due to the secretive nature of fraternal organizations, records containing the specific details regarding this skeleton have not been offered from the state or national level. Whether any records exist within the IOOF organization that identify the exact origins and time of death or purchase of this skeleton is unknown at this time. However, utilizing hardware morphologies, the coffin can be dated from 1855 to 1870 (French 2012) and the skeleton can be dated to before 1910, as the use of arsenic in funerary preparations was outlawed at that time (Konefes and McGee 2001). Due to all of these factors, there is no way to accurately determine time of death. The approximate time of death that can be established is 1860-1910 based on the time frame that arsenic was used in funerary preservatives. Because the coffin was likely not made for this individual, it is not possible to use the coffin as a mechanism for establishing time of death.

Cause of death is also difficult to ascertain. There were no soft tissue samples to examine and no obvious violent trauma. There were open osseous tuberculosis

lesions on the right parietal, obliteration of the right elbow by tuberculosis, and a deep cavitation in the L-5 vertebrae indicative of an ongoing state of pathology that was active until death occurred. It is likely that this individual died of tuberculosis.

Summary and Conclusion

The remains are those of a fully skeletonized, disarticulated, male who was at least 40 years of age at the time of death. He was likely of European ancestry and was relatively tall at 5’7” – 5’10”. He was also robust with significant muscle mass, indicating an active lifestyle. This individual suffered from proliferative tuberculosis at the end of his life, evidenced by lesions on the cranium, humerus, ulna, radius, and L-5 vertebra. Postmortem, he was likely used as a medical model as evidenced by the holes drilled in the left humerus and ulna, the cranium section forming unattached crooked calotte, the cuts to the sternal ends of the ribs, and the application of an arsenic-laced preservative.

The skeleton was found in a mid-19th century coffin, which had not been buried, but had significant water damage from a known flood in 1962. The interior of the coffin was covered in a thick layer of dried dirt and mold. The dimensions of the coffin were not suited for an individual of this stature, as the maximum internal length is 52.5”, and the minimum height of this individual was 5’7”. This was likely a coffin designed for a child. After use as a medical model, the skeleton and coffin were likely purchased out of an Odd Fellows paraphernalia catalog for use in initiation rites. The Odd Fellows, as keepers of the dead, have modified their ritual practices overtime. Today they use an empty casket or a casket with plastic bone replicas for initiation ceremonies.

Bibliography

American Association of Physical Anthropologists. *American Association of Physical Anthropologists.* 2012. http://physanth.org/association/position-statements/biological-aspects-of-race (accessed June 4, 2012).

Andrews-Lynn, Martin, interview by Dawn Marie Alapisco. *Initiation Rites* (May 12, 2012).

Bass, William M. *Human Osteology A laboratory Field Manual.* Fifth Edition. Columbia: Missouri Archaeological Society, 2005.

Bioarchaeology Lab of the Arizona State Museum. *Arizona State Museum Skeletal Inventory form Guidelines.* Tucson: University of Arizona, 2004.

Buikstra, Jane E., and Douglas H. Ubelaker. *Standards for Data Collection From Human Skeletal Remains.* Fayetteville: Arkasas Archaeological Survey, 1994.

Byers, Steven N. *Introduction to Forensic Anthropology.* Third Edition. Boston: Pearson, 2008.

French, Jamie, interview by Dawn Marie Alapisco. *Personal Communication, Hardware Dating* (June 4, 2012).

Independent Order of Odd Fellows. *Independent Order of Odd Fellows.* 2012. http://www.ioof.org/aboutus.html (accessed April 27, 2012).

Kalnicky, Dennis J, and Raj Singhvi. "Field Portable XRF analysis of environmental smaples." *Journal of Haxardous Materials*, 2001: 93-122.

Knepper, Anne Marie. "A Real Skeleton in the Closet." *Albany Democrat-Herald*, August 28, 2011.

Konefes, John L, and Michael K McGee. "Old Cemetaries, Arsenic, and Health Safety." In *Dangerous Plcaes: Health, Safety, and Archaeology*, by David A Poirier and Kenneth L Feder, 127-136. Westport: Bergin & Garvey, 2001.

Lakey, Lester S, and Suzanne E Walker. "CSI Ozarks: Practicing Forensic Anthropology." *Practicing Anthropology*, 2007: 40-46.

Lundgreen, Drew, interview by Dawn Marie Alapisco. *Coffin Sizes* (May 21, 2012).

Meindl, Richard S, and C. Owen Lovejoy. "Ectocranial Suture Closure: A Revised Method for the Determination of Skeletal Age at Death Based in the Lateral-Anertior Sutures." *American Journal of Physical Anthropology*, 1985: 57-66.

Minten, Jenny, interview by KVAL News. *Skeleton in the Closet* (August 30, 2011).

Minten, Lindy, interview by Dawn Marie Alapisco. *IOOF Skeleton* (March 25, 2012).

Nyers, Alex, personal communication with Dawn Marie Alapisco. *PXRF Analysis* (June 4, 2012).

Oregon IOOF. *Grand Lodge of Oregon, IOOF*. 2012. http://www.oregonioof.org (accessed May 30, 2012).

Ortner, Donald J. *Identification of Pathological Conditions In Human Skeletal Remains.* Second Edition. Amsterdam: Elsevier Academic Press, 2003.

Phoenixmasonry Masonic Museum and Library. *http://www.phoenixmasonry.org.* 2011. http://www.phoenixmasonry.org/masonicmuseum/demoulin/index.htm (accessed May 17, 2012).

Salem Public Library. *Salemhistory.net.* 2012. http://www.salemhistory.net/culture/oddfellows.htm (accessed April 27, 2012).

Schindell, Jennifer, interview by Dawn Marie Alapisco. *Personal Communications* (May 30, 2012).

Valdes, Robert. *How Stuff Works: How Autopsies Work.* 2012. http://science.howstuffworks.com/autopsy2.htm (accessed June 5, 2012).

Waldron, Tony. *Paleoppathology.* Cambridge: Cambridge University Press, 2009.

White, Tim D., Michael T. Black, and Pieter A. Folkens. *Human Osteology.* Third Edition. Amsterdam: Elsevier Academic Press, 2012.

Wilson, Rebecca J, Nicholas P Herrmann, and Lee Meadows Jantz. "Evaluation of Stature Estimation from the Database for Forensic Anthropology." *Journal of Forensic Sciences*, 2010: 684 - 689.

Appendices

Appendix A

Arizona State Museum
THE UNIVERSITY OF ARIZONA

ARIZONA STATE MUSEUM
HUMAN SKELETAL REMAINS CHECKLIST

Site Name/Number: Scio Independent Order of Odd Fellows Lodge
Observers: Jenny and Lindy Minten
Feature/Burial Number: OSU.2011.IOOF.001
Present Location of Remains: OSU Biocultural Anthropology Labroatory
Date: 02/16/2012

General

☐ Juvenile
☑ Adult

MNI: 1
MNI Form:
collection type: Historic/forensic

Taphonomy

Yes	No	Unobservable	
☐	☐	☐	Weathering (describe severity and which elements affected): axial skeleton primarily effected
☐	☐	☐	Discoloration: severe mold, color variable and ranges from ivory to black
☐	☐	☐	Cutmarks, gnaw marks: cranial section, and sternal ends of ribs

Form List - indicate forms used

☒	1	Skeletal Inventory
☒	2	Adult Age and Sex
☒	3	Permanent Teeth Inventory
☒	4	Permanent Teeth Pathologies
☐	5 a & b	Permanent Teeth Morphology (optional)
☒	6	Postcranial Measurements (Adult)
☒	7a & b	Non-Metric Traits and Cranial Metrics
☐	8	Cranial Deformation
☒	9	Pathology Checklist
☐	10	Degenerative Joint Disease
☒	11	Spinal Osteophytosis and DJD
☐	12	Adult Skeleton
☒	13	Adult Skull
☒	14	Left Ilium, Scapula, and Clavicle
☒	15	Right Ilium, Scapula, and Clavicle
☒	16	Right Humerus
☒	17	Left Humerus
☒	18	Right Radius
☒	19	Left Radius
☒	20	Right Ulna
☒	21	Left Ulna
☒	22	Right Femur
☒	23	Left Femur
☒	24	Right Tibia
☒	25	Left Tibia
☒	26	Right Fibula
☒	27	Left Fibula
☒	28a & b	Hand
☒	29a & b	Foot
☐	30	Immature Epiphyseal Union & Age Assessment
☐	31	Immature Measurements
☐	32a	Deciduous Teeth Inventory
☐	32b	Deciduous Teeth Pathology
☐	32c & d	Deciduous Teeth Morphology (Optional)
☐	33	Infant Skeleton
☐	34	Child Skeleton
☐	35	Isolated Bones
☐	36a & b	Cremated Bone (use 36b only for more complete cremations)

Appendix B

Provenience _____ Numeric I.D. _____ ASM 8/24/04 Form 1

SKELETAL INVENTORY

AXIAL

element	#	cond
1st Cervical		C
2nd Cervical		C
3-6 Cervical	3	C
7th Cervical		C
1-9 Thoracic	9	C
10th Thoracic		C
11th Thoracic		C
12th Thoracic		C
1st Lumbar		C
2nd Lumbar		C
3rd Lumbar		C
4th Lumbar		C
5th Lumbar		C
Sacrum	1	P
Coccyx	0	
Left Ribs	11	P
Right Ribs	11	P

APPENDICULAR

element	left	right
Scapula	1	1
glenoid	1	1
Clavicle	1	1
med. epi.	1	1
Sternum		
manubrium	0	
body	0	
xiphoid	0	
Ilium	1/2	1
auricular	1/2	1/2
Pubis	0	1/2
symphysis	0	0
Ischium	1	1
Acetabulum	1	1
Patella	1	1

CRANIAL

element	left	right
Parietal	1	1
Temporal	1	1
Zygomatic	1	1
Lacrimal	1	1
I. N. C.	0	0
Nasal	1	1
Maxilla	1	1
Palatine	1	1
TMJ	1	1
Mandible	1	
Frontal	1	
Sphenoid	1	
Ethmoid	1	
Vomer	1/2	
Occipital	1	
Hyoid	0	
Thyroid	0	
Crycoid	0	
Ossicles	3	

APPENDICULAR

element	left side epi-p	prox	mid	dist	epi-d	right side epi-p	prox	mid	dist	epi-d
Humerus	C	C	C	C	C	C	C	C	C	P
Radius	C	C	C	C	C	C	C	C	C	C
Ulna	C	C	C	C	C	P	C	C	C	C
Femur	C	C	C	C	C	C	C	C	C	C
Tibia	C	C	C	C	C	C	C	C	C	C
Fibula	C	C	C	C	C	C	C	C	C	C

Codes:
c = >/= 75% present
p = 25% - 75% present
f = < 25% present

EXTREMITIES

element	#	cond	element	#	cond
Scaphoid	2	C	Calcaneus	2	C
Lunate	0	0	Talus	2	C
Trapezium	0	0	Cuboid	2	C
Trapezoid	0	0	Navicular	2	C
Capitate	2	C	Medial Cuneiform	2	C
Hamate	2	C	Intermed. Cuneiform	2	C
Triquetral	1	C	Lateral Cuneiform	2	C
Pisiform	1	C			
Metacarpals			Metatarsals		
1st	2	C	1st	2	C
2nd	2	C	2nd	2	C
3rd	2	C	3rd	2	C
4th	2	C	4th	2	C
5th	2	C	5th	2	C
C. Phalanges			T. Phalanges		
proximal	10	C	proximal	8	C
middle	5	C	middle	0	0
distal	1	C	distal	2	C/P
Sesamoids	0	C	Sesamoids	0	0

NOTES

RMC-5 PATH
R- HUM, RAD, ULNA - PATH
L-5 LESION
OSTEOPHYTES
ROGOSE
PALATE LESIONS
MAXILLAE LESIONS

This form includes information derived from Buikstra and Ubelaker (1994), *Standards for Data Collection from Human Skeletal Remains,* Arkansas Archeological Survey, and is used with permission of the publisher.

Appendix C

Provenience _____ Numeric I.D. _____ ASM 8/24/04 Form 2

ADULT AGE/SEX RECORDING FORM

Age Criteria

Pubic Symphysis	Left	Right
Todd (1-10)	N/A	N/A
Suchey-Brooks (1-6)	N/A	N/A

Auricular Surface (1-8)	Left	Right
	N/A	N/A

Suture Closure & Epiphyseal Union: blank = unobservable, 0 = open, 1 = minimal, 2 = significant, 3 = complete

External Cranial Vault	1. Midlambdoid	1
	2. Lambda	2
	3. Obelion	3
	4. Anterior Sagittal	3
	5. Bregma	1
	6. Midcoronal	1
	7. Pterion	2
	8. Sphenofrontal	2
	9. Inferior Sphenotemporal	2
	10. Superior Sphenotemporal	1
Clavicle	Sternal epiphysis	N/A
Sacrum	S1/S2 fusion	N/A
Innominate	Iliac crest	N/A

Palatine	11. Incisive Suture		3
	12. Anterior Median Palatine		2
	13. Posterior Median Palatine		2
	14. Transverse Palatine		2
Internal Cranial Vault	15. Sagittal		2
	16. Left Lambdoid		2/3
	17. Left Coronal		3
Vertebral Annular Epiphyses	Cervical	superior	N/A
		inferior	N/A
	Thoracic	superior	N/A
		inferior	N/A
	Lumbar	superior	N/A
		inferior	N/A

Estimated Age:

Subadult (12-18 years)	____
Young Adult (18-35 years)	____
Middle Adult (35-50 years)	x
Old Adult (50+ years)	x

Comments:

ectocranial cranial suture closure age range - 34-60 with a mean of 49, endocranial age range - late 50+

palate pathologies prevent accurate age estimation

Sex

Pelvis	Left	Right
Ventral Arc (1-3)	N/A	N/A
Subpubic Concavity (1-3)	N/A	N/A
Ischiopubic Ramus Ridge (1-3)	N/A	N/A
Greater Sciatic Notch (1-5)	4	4
Preauricular Sulcus (0-4)	0	0

Skull	
Nuchal Crest (1-5)	5
Mastoid Process (1-5)	5
Supraorbital Margin (1-5)	5
Glabella (1-5)	5
Mental Eminence (1-5)	3

Estimated Sex, Pelvis (1-5) _____ = ____ Estimated Sex, Skull (1-5) 23/5= 4.6 = MALE

Comments:

sex determination from cranial traits

This form includes information derived from Buikstra and Ubelaker (1994), *Standards for Data Collection from Human Skeletal Remains,* Arkansas Archeological Survey, and is used with permission of the publisher.

Appendix D

Provenience _____ Numeric I.D. _____ ASM 8/24/04 Form 3

PERMANENT TEETH RECORDING FORM
Wear, Development, Loss

Loss Categories	Wear Stages	Development Stages
A = antemortem	0 = not in occlusion	0 = unobservable
P = postmortem	1-10 = per *Standards*	1-14 = per *Standards*
U = unknown	X = unknown due to caries or breakage	

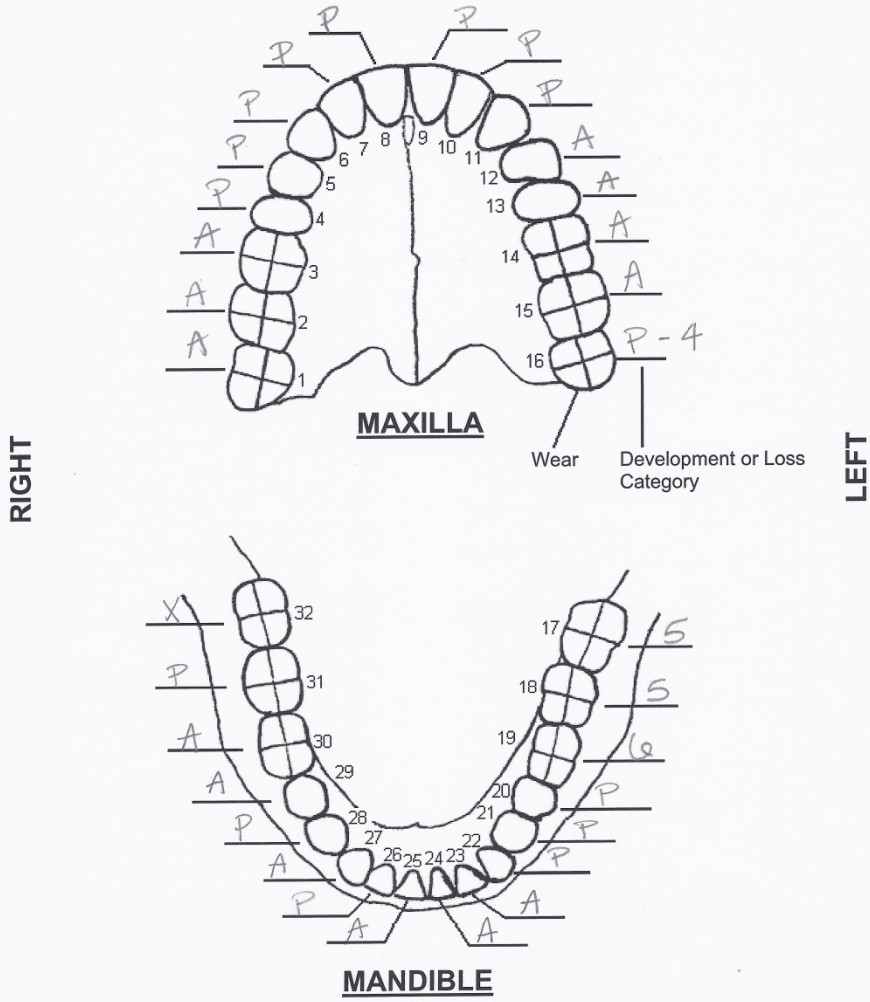

This form includes information derived from Buikstra and Ubelaker (1994), *Standards for Data Collection from Human Skeletal Remains,* Arkansas Archeological Survey, and is used with permission of the publisher.

Appendix E

Provenience _____ Numeric I.D. _____ ASM 8/24/04 Form 4

PERMANENT TEETH RECORDING FORM
Pathologies

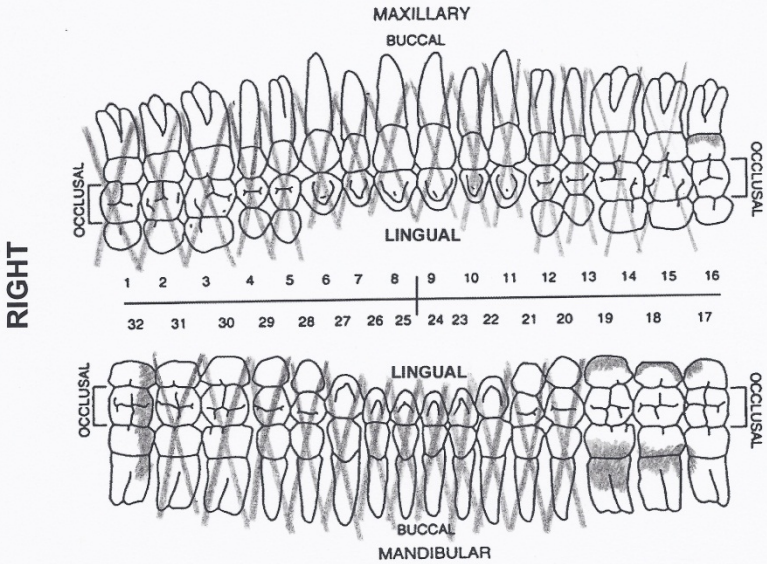

Indicate missing alveolar bone on drawings below with cross-hatching

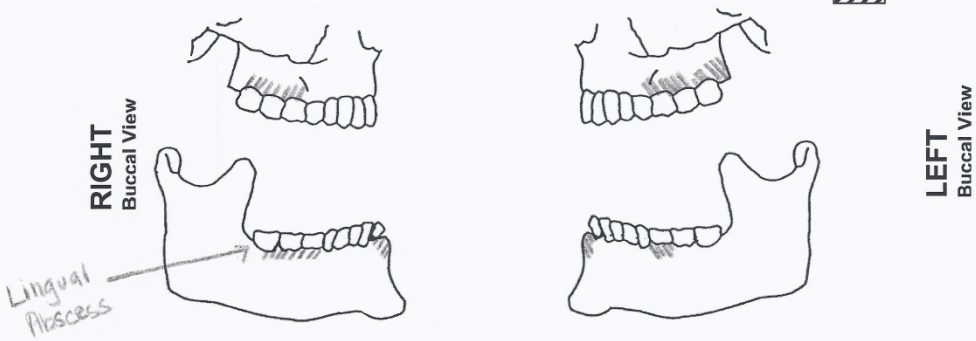

Note: Indicate dental pathologies on the drawings above. Use codes per *Standards*.

Checklist:	Caries	Abscesses	Hypoplasia	Calculus	Periodontal Disease	Hypocalcification
present	✓	✓		✓	✓	
absent			✓			✓
unobservable						

This form includes information derived from Buikstra and Ubelaker (1994), *Standards for Data Collection from Human Skeletal Remains,* Arkansas Archeological Survey, and is used with permission of the publisher.

Appendix F

Provenience _____ Numeric I.D. _____ ASM 8/24/04 Form 6

POSTCRANIAL MEASUREMENT RECORDING FORM (ADULTS)

All measurements are in millimeters. * indicates that measurement is approximate

	left	right
35. Clavicle: maximum length	13.3 cm	14.5 cm
36. Clavicle: A-P Dia. at midshaft	13 cm	10.2 cm
37. Clavicle: sup-inf Dia. at midshaft	.9 cm	.9 cm
38. Scapula: height	19.2 cm	N/A
39. Scapula: breadth	10.4 cm	N/A
40. Humerus: maximum length	33.2 cm	32.7 cm
41. Humerus: epicondylar breadth	6.0 cm	6.4 cm
42. Humerus: vertical dia. of head	4.7 cm	4.7 cm
43. Humerus: max. dia. at midshaft	2.4 cm	2.3 cm
44. Humerus: min. dia. at midshaft	1.8 cm	1.7 cm
45. Radius: maximum length	24.7 cm	24.5 cm
46. Radius: A-P dia. at midshaft	1.2 cm	1.1 cm
47. Radius: M-L dia. at midshaft	1.5 cm	1.6 cm
48. Ulna: maximum length	26.2 cm	26.5 cm
49. Ulna: A-P diameter	1.6 cm	1.6 cm
50. Ulna: M-L diameter	1.5 cm	1.2 cm
51. Ulna: physiological length	22.5 cm	21.8 cm
52. Ulna: minimum circumference	3.5 cm	3.6 cm
53. Sacrum: anterior length	12.3 cm	
54. Sacrum: anterior superior breadth	10.6 cm	
55. Sacrum: max. trans. dia. of base	4.9 cm	

	left	right
56. Os Coxae: height	21.3 cm	N/A
57. Os Coxae: Iliac breadth	N/A	N/A
58. Os Coxae: pubis length	N/A	N/A
59. Os Coxae: ischium length	N/A	N/A
60. Femur: maximum length	9.0 cm	9.3 cm
61. Femur: bicondylar length	45.6 cm	45.5 cm
62. Femur: epicondylar breadth	8.2 cm	8.1 cm
63. Femur: max. dia. of head	4.6 cm	4.5 cm
64. Femur: A-P subtrochanteric	2.7 cm	2.7 cm
65. Femur: M-L subtrochanteric	3.0 cm	2.9 cm
66. Femur: A-P midshaft dia.	2.9 cm	2.6 cm
67. Femur: M-L midshaft dia.	2.6 cm	2.6 cm
68. Femur: midshaft circum.	8.5 cm	8.5 cm
69. Tibia: length	38.8 cm	38.8 cm
70. Tibia: max. prox. epi. breadth	7.3 cm	7.5 cm
71. Tibia: max. dist. epi. breadth	5.2 cm	5.2 cm
72. Tibia: max. dia. at foramen	3.4 cm	3.1 cm
73. Tibia: min. dia. at foramen	2.2 cm	2.1 cm
74. Tibia: circum. at foramen	8.8 cm	8.8 cm
75. Fibula: maximum length	38.1 cm	37.9 cm
76. Fibula: max midshaft dia.	1.3 cm	1.4 cm
77. Calcaneus: maximum length	8.2 cm	8.3 cm
78. Calcaneus: middle breadth	4.2 cm	4.3 cm

This form includes information derived from Buikstra and Ubelaker (1994), *Standards for Data Collection from Human Skeletal Remains,* Arkansas Archeological Survey, and is used with permission of the publisher.

Appendix G

NONMETRIC TRAITS Provenience _____ Numeric I.D. _____ **ASM 8/24/04** Form 7a

	L	M	R
1. Metopic suture: 0 = absent 1 = partial 2 = complete 9 = unobservable		0	
2. Supraorbital structures:			
a. Supraorbital notch: 0 = absent 1 = present, < ½ occluded by spicules 2 = present, > ½ occluded by spicules 3 = present, degree of occlusion unknown 4 = multiple notches 9 = unobservable	1		1
b. Supraorbital foramen: 0 = absent 1 = present 2 = multiple foramina 9 = unobservable	0		0
3. Infraorbital suture: 0 = absent 1 = present 2 = complete 9 = unobservable	1		0
4. Multiple infraorbital foramina: 0 = absent 1 = internal division only 2 = two distinct foramina 3 = more than two distinct foramina 9 = unobservable	0		0
5. Zygomatico-facial foramina: 0 = absent 1 = 1 large 2 = 1 large plus smaller f. 3 = 2 large 4 = 2 large plus smaller f. 5 = 1 small 6 = multiple small 9 = unobservable	6		6
6. Parietal foramen: 0 = absent 1 = present, on parietal 2 = present, sutural 9 = unobservable	1		1
7. Sutural bones: 0 = absent, 1 = present, 9 = unobserv.			
a. epiteric bone	0		0
b. coronal ossicle	0		0
c. bregmatic bone		0	
d. sagittal ossicle		0	
e. apical bone		0	
f. lambdoid ossicle	0		0
g. asterionic bone	0		0
h. ossicle in occipito-mastoid suture	0		0
i. parietal notch bone	0		0

	L	M	R
8. Inca bone: 0 = absent 1 = complete, single bone 2 = bipartite 3 = tripartitie 4 = partial 9 = unobservable		0	
9. Condylar canal 0 = not patent 1= patent 9 = unobservable	1		1
10. Divided hypoglossal canal: 0 = absent 1 = partial, internal surface 2 = partial, within canal 3 = complete, internal surface 4 = complete, within canal 9 = unobservable	0		0
11. Flexure of superior sagittal sulcus 1 = right 2 = left 3 = bifurcate 9 = unobservable		1	
12. Foramen ovale incomplete 0 = absent 1 = partial formation 2 = no definition of foramen 9 = unobservable	0		0
13. Foramen spinosum incomplete 0 = absent 1 = partial formation 2 = no definition of foramen 9 = unobservable	0		0
14. Pterygo-spinous bridge 0 = absent 1 = trace (spicule only) 2 = partial bridge 3 = complete bridge 9 = unobservable	9		9
15. Pterygo-alar bridge 0 = absent 1 = trace (spicule only) 2 = partial bridge 3 = complete bridge 9 = unobservable	9		9
16. tympanic dehiscence: 0 = absent 1 = foramen only 2 = full defect present 9 = unobservable	0		0

This form includes information derived from Buikstra and Ubelaker (1994), *Standards for Data Collection from Human Skeletal Remains,* Arkansas Archeological Survey, and is used with permission of the publisher.

Appendix H`

Provenience _____ Numeric I.D. _____ ASM 8/24/04 Form 7b

	L	R
17. Auditory exostosis: 0 = absent 1 = < 1/3 canal occluded 2 = 1/3-2/3 canal occluded 3 = > 2/3 canal occluded 9 = unobservable	0	0
18. Mastoid foramen: **a. Location** 0 = absent 1 = temporal 2 = sutural 3 = occipital 4 = both sutural and temporal 5 = both occipital and temporal 9 = unobservable	4	1
b. Number: 0 = absent 1 = 1 2 = 2 3 = more than 2 9 = unobservable	2	2
19. Mental foramen: 0 = absent 1 = 1 2 = 2 3 = more than 2 9 = unobservable	1	1
20. Mandibular torus: 0 = absent 1 = trace (can palpate but not see) 2 = moderate: elevation between 2-5 mm. 3 = marked: elevation greater than 5 mm. 9 = unobservable	1	1
21. Mylohyoid bridge: **a. Location** 0 = absent 1 = near mandibular foramen 2 = center of groove 3 = both bridges described in 1) and 2), with hiatus 4 = both bridges described in 1) and 2), no hiatus 9 = unobservable	0	0
b. Degree 0 = absent 1 = partial 2 = complete 9 = unobservable	0	0
22. Atlas Bridging: **a. Lateral bridging** 0 = absent 1 = partial 2 = complete 9 = unobservable	0	0
b. Posterior bridging 0 = absent 1 = partial 2 = complete 9 = unobservable	0	0

	L	R
23. Accessory Transverse Foramina -- in 7th cervical vertebra 0 = absent 1 = partial 2 = complete 9 = unobservable	9	9
24. Septal aperture: 0 = absent 1 = small foramen (pinhole) only 2 = true perforation 9 = unobservable	0	1

CRANIAL MEASUREMENTS (in mm, left side for bilateral measurements unless noted as R)

1. Max. cranial length	21.5 cm
2. Max. cranial breadth	15.2 cm
3. Bizygomatic diameter	13.7 cm
4. Basion-bregma height	13.7 cm
5. Cranial base length	10.2 cm
6. Basion-prosthion length	9.3 cm
7. Maxillo-alveolar breadth	5.9 cm
8. Maxillo-alveolar length	4.9 cm
9. Biauricular breadth	11.2 cm
10. Upper facial height	6.3 cm
11. Minimum frontal breadth	9.7 cm
12. Upper facial breadth	10.6 cm
13. Nasal height	3.9 cm
14. Nasal breadth	2.4 cm
15. Orbital breadth	3.8 cm
16. Orbital height	3.3 cm
17. Biorbital breadth	9.8 cm
18. Interorbital breadth	2.1 cm
19. Frontal chord	11.8 cm
20. Parietal chord	15.9 cm
21. Occipital chord	4.3 cm
22. Foramen magnum length	3.1 cm
23. Foramen magnum breadth	3.0 cm
24. Mastoid length	3.3 cm
25. Chin height	1.9 cm
26. Height of the mandibular body	2.1 cm
27. Breadth of the mandibular body	1.1 cm
28. Bigonial width	10.6 cm
29. Bicondylar breadth	11.9 cm
30. Minimum ramus breadth	2.9 cm
31. Maximum ramus breadth	4.2 cm
32. Maximum ramus height	6.7 cm
33. Mandibular length	9.7 cm
34. Mandibular angle	35° mandibulometer

This form includes information derived from Buikstra and Ubelaker (1994), *Standards for Data Collection from Human Skeletal Remains,* Arkansas Archeological Survey, and is used with permission of the publisher.

Due to some postmortem modifications, some measurements may not be entirely accurate.

Appendix I

Provenience _____ Numeric I.D. _____ ASM 8/24/04 Form 9

PATHOLOGY CHECKLIST

Cranial	present	absent	unobservable
Porotic hyperostosis		x	
Cribra orbitalia		x	
Premature synostosis		x	
osteomas		x	
periosteal reaction	x		
lytic reactions	x		
proliferative reactions	x		
trauma		x	
cultural modifications		x	

Axial	present	absent	unobservable
ankylosis	x		
arch defects		x	
compression fractures		x	
Schmorl's nodes	x		
periosteal reactions	x		
lytic reactions	x		
osteoporosis	x		
trauma		x	

Appendicular	present	absent	unobservable
periosteal reaction	x		
lytic reactions	x		
proliferative reactions	x		
osteoporosis		x	
trauma		x	
cultural modifications		x	
osteomyelitis		x	
exostoses	x		

Extremities	present	absent	unobservable
lytic reactions	x		
proliferative reactions	x		
periosteal reactions	x		
trauma		x	
exostoses		x	

Notes:

Appendix J

Provenience _____ Numeric I.D. _____ ASM 8/24/04 Form 11

SPINAL OSTEOPHYTOSIS RECORDING FORM

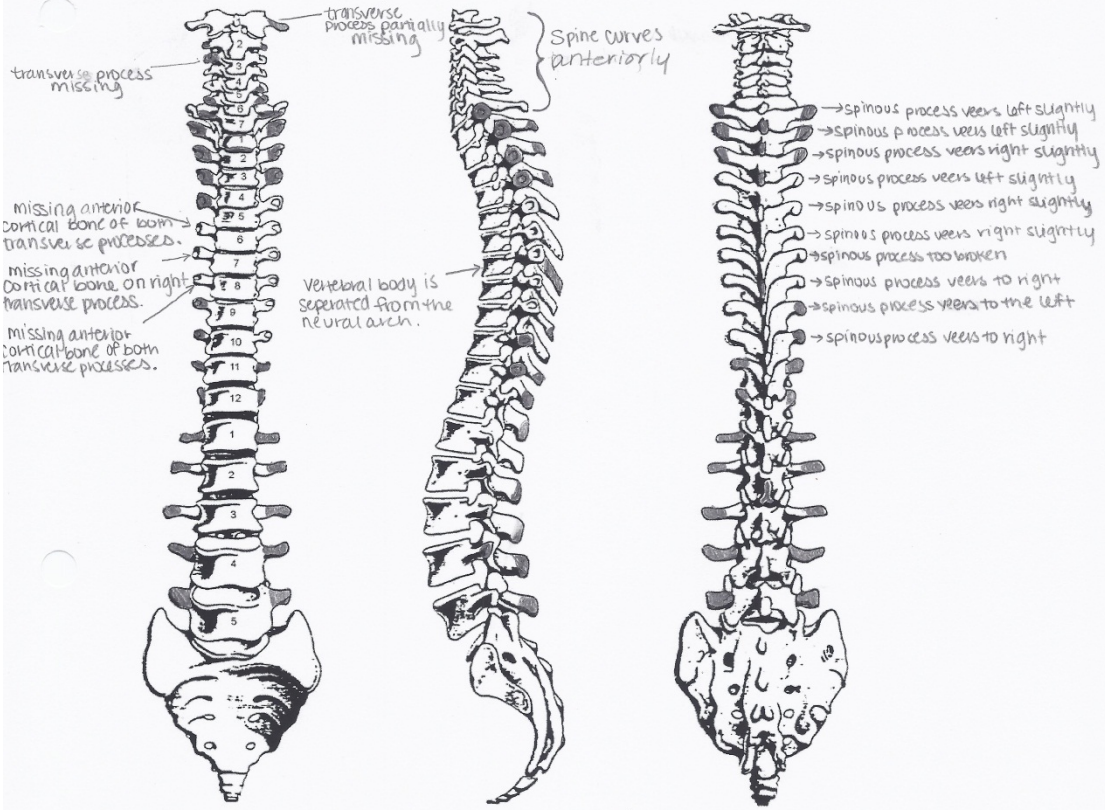

Osteophytosis - stages 0-4 (Ubelaker 1999)

Vertebral Category	Superior Surface	Inferior Surface
Cervical	_____	_____
Thoracic	_____	_____
Lumbar	_____	_____

Degenerative Joint Disease (Vertebral Articular Surfaces) – stages a-d (Ubelaker 1999)

Vertebral Category	Superior Surface		Inferior Surface	
	Left	Right	Left	Right
Cervical	____	____	____	____
Thoracic	____	____	____	____
Lumbar	____	____	____	____
Sacral	____	____		

NOTE: If condition varies, bracket & note areas of major differences on graph. Applies to both DJD & osteophytosis.

Appendix K

Provenience _____ Numeric I.D. _____ ASM 8/24/04 Form 13

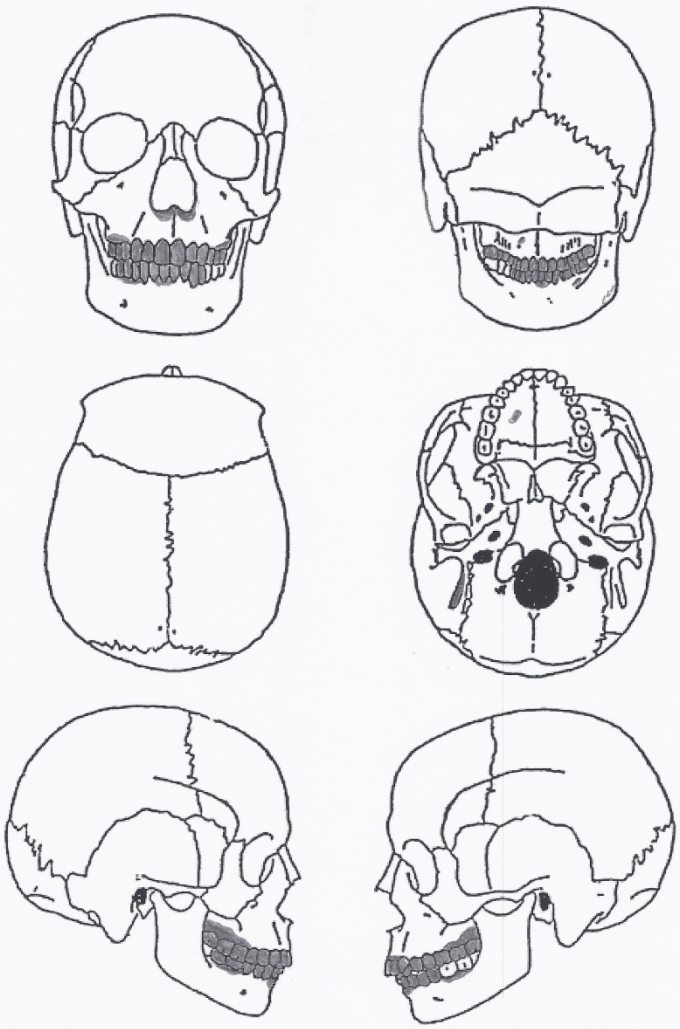

This form includes information derived from Buikstra and Ubelaker (1994), *Standards for Data Collection from Human Skeletal Remains,* Arkansas Archeological Survey, and is used with permission of the publisher.

Appendix L

Provenience _____ Numeric I.D. _____ ASM 8/24/04 Form 14

LEFT ILIUM, SCAPULA, CLAVICLE

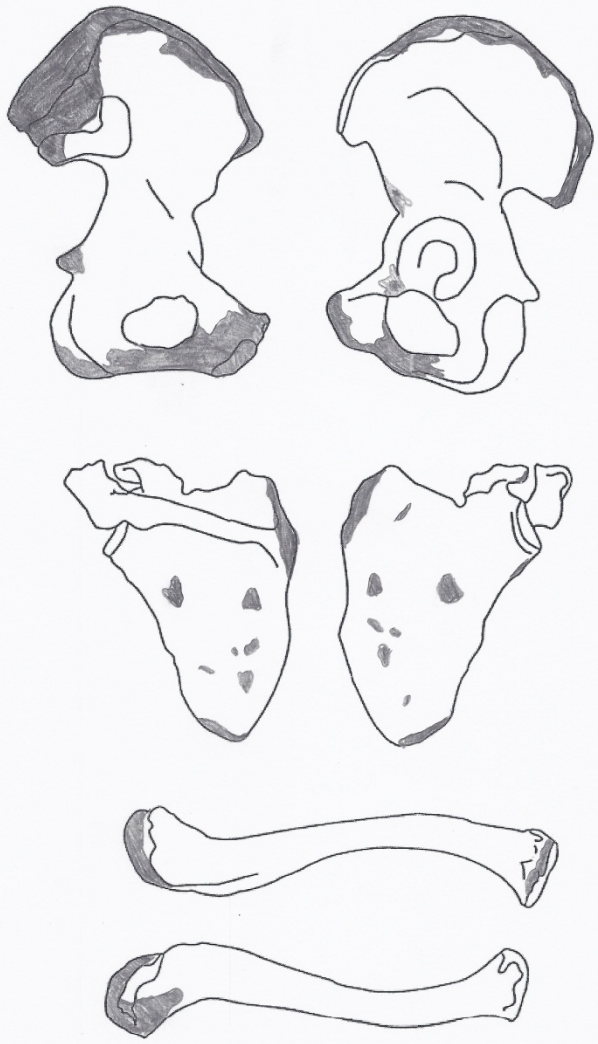

This form includes information derived from Buikstra and Ubelaker (1994), *Standards for Data Collection from Human Skeletal Remains,* Arkansas Archeological Survey, and is used with permission of the publisher.

Appendix M

Provenience _____ Numeric I.D. _____ ASM 8/24/04 Form 15

RIGHT ILIUM, SCAPULA, CLAVICLE

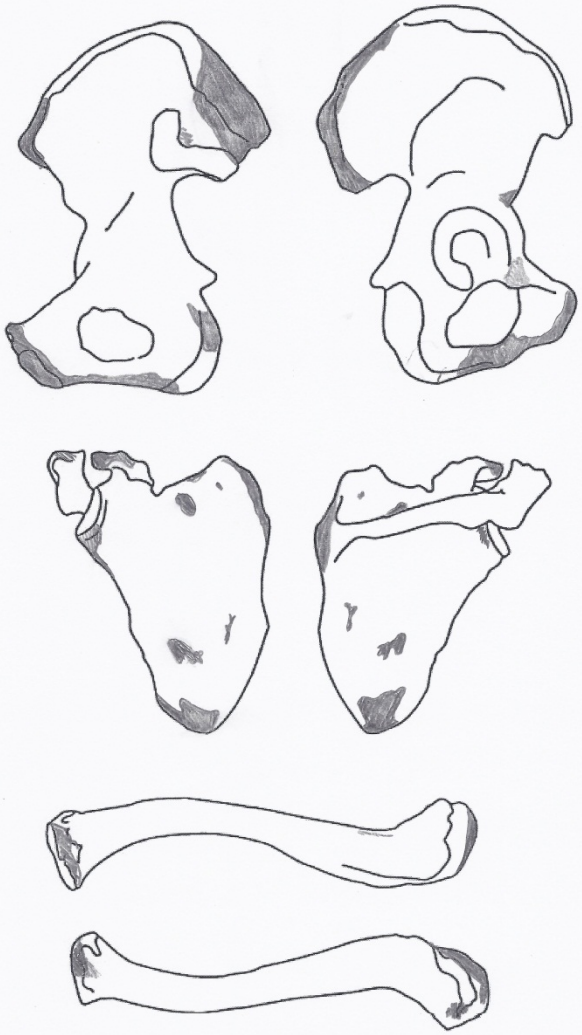

This form includes information derived from Buikstra and Ubelaker (1994), *Standards for Data Collection from Human Skeletal Remains,* Arkansas Archeological Survey, and is used with permission of the publisher.

Appendix N

Provenience _____ Numeric I.D. _____ ASM 8/24/04 Form 16

RIGHT HUMERUS

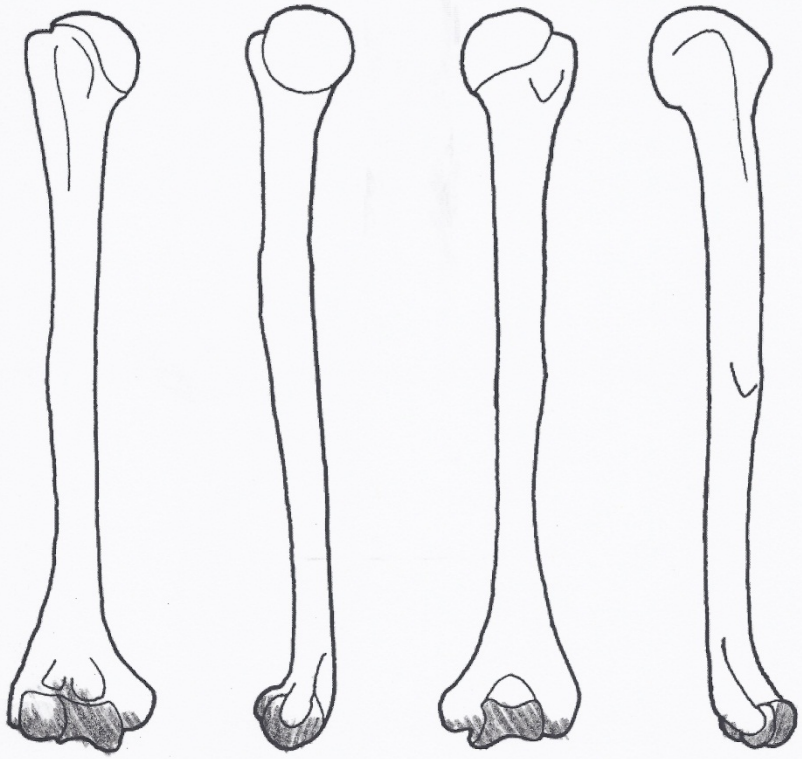

anterior **medial** **posterior** **lateral**

Notes:

Appendix O

Provenience _____ Numeric I.D. _____ ASM 8/24/04 Form 17

LEFT HUMERUS

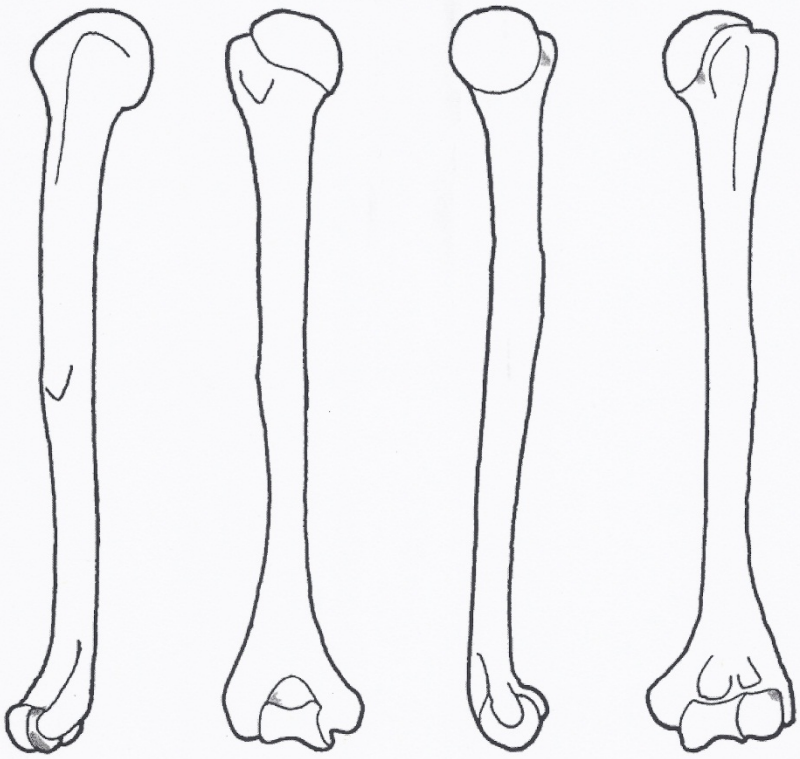

lateral **posterior** **medial** **anterior**

Notes:

Appendix P

Provenience _____ Numeric I.D. _____ ASM 8/24/04 Form 18

RIGHT RADIUS

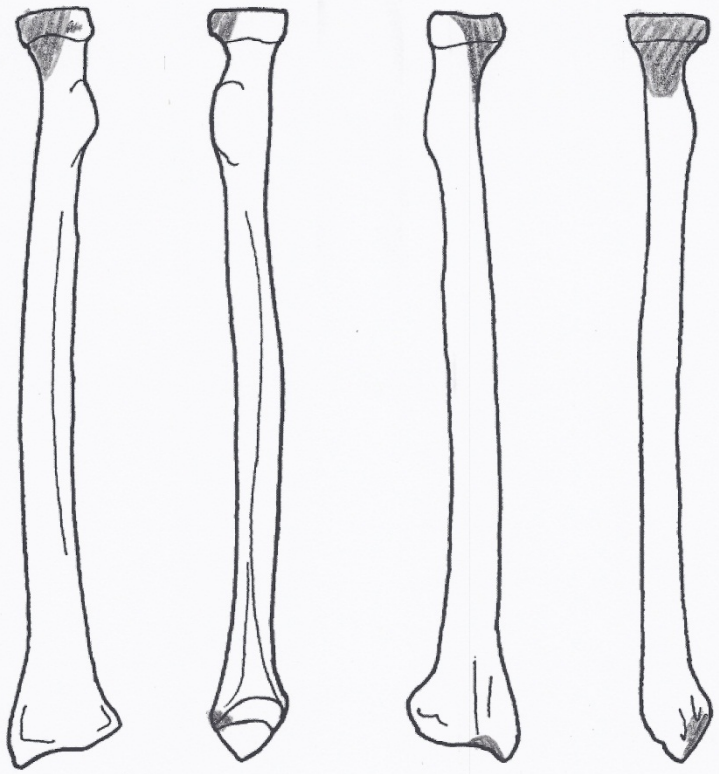

anterior **medial** **posterior** **lateral**

Notes:

Appendix Q

Provenience _____ Numeric I.D. _____ ASM 8/24/04 Form 19

LEFT RADIUS

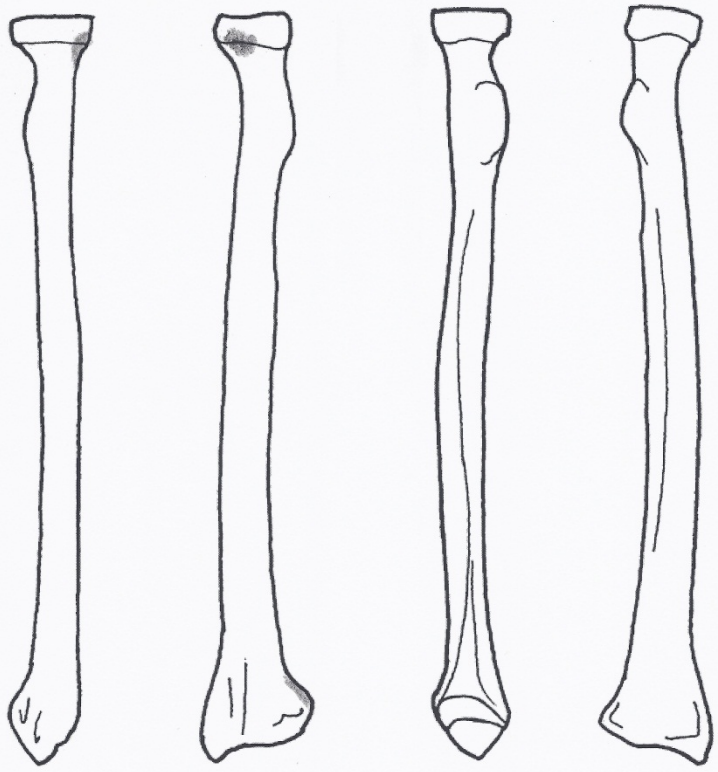

lateral **posterior** **medial** **anterior**

Notes:

Appendix R

Provenience _____ Numeric I.D. _____ ASM 8/24/04 Form 20

RIGHT ULNA

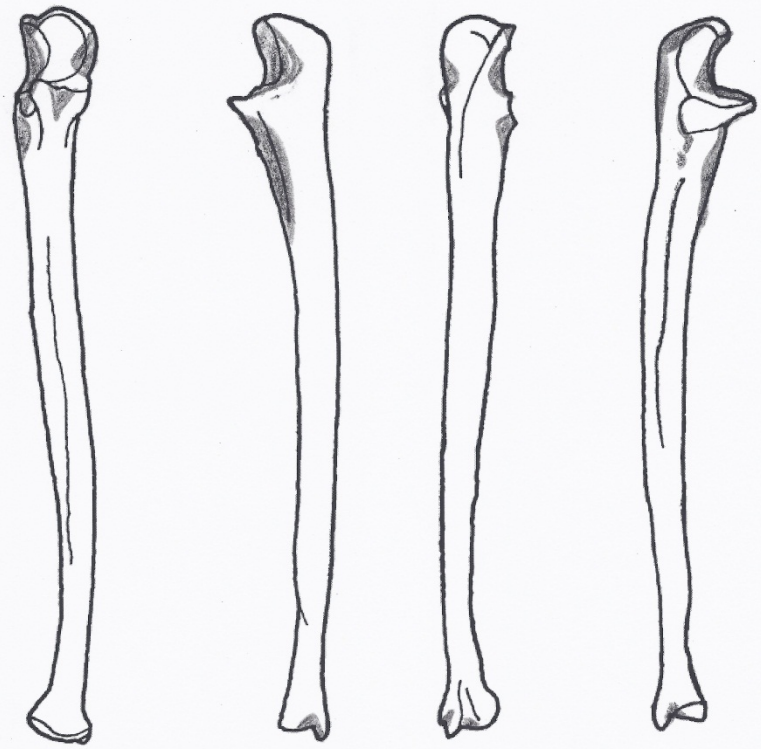

anterior **medial** **posterior** **lateral**

Notes:

Appendix S

Provenience _____ Numeric I.D. _____ ASM 8/24/04 Form 21

LEFT ULNA

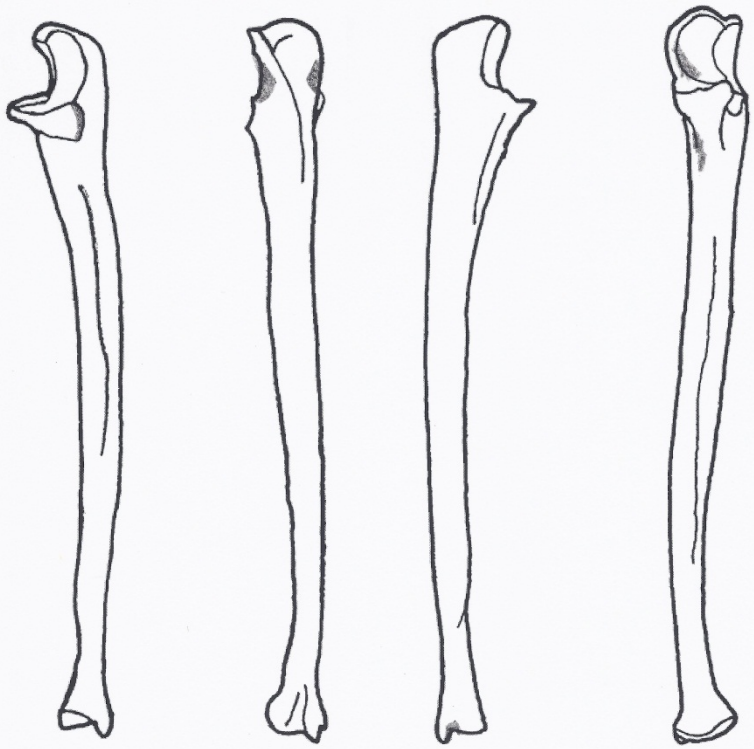

lateral **posterior** **medial** **anterior**

Notes:

Appendix T

Provenience _____ Numeric I.D. _____ ASM 8/24/04 Form 22

RIGHT FEMUR

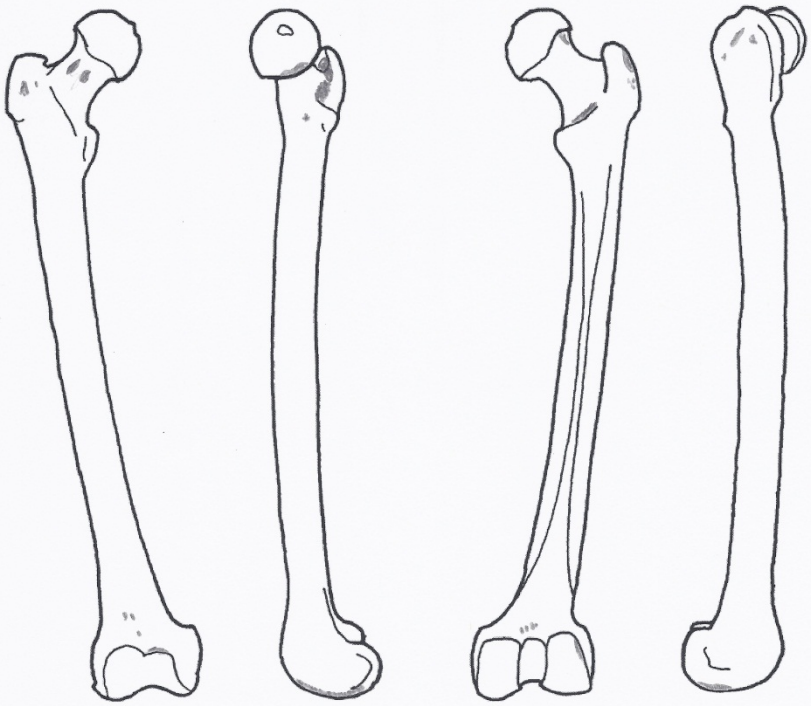

anterior **medial** **posterior** **lateral**

Notes:

Appendix U

Provenience _____ Numeric I.D. _____ ASM 8/24/04 Form 23

LEFT FEMUR

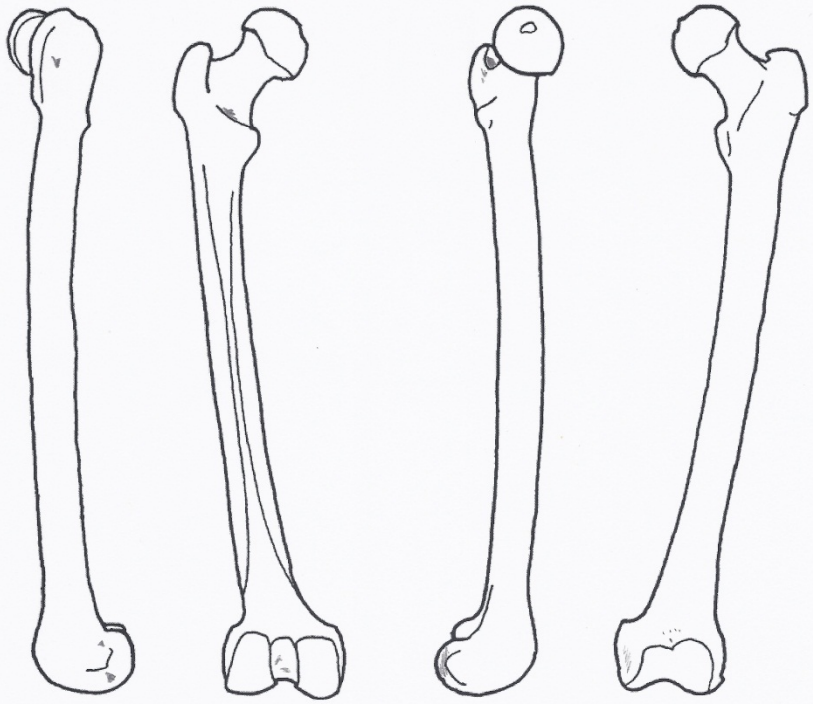

lateral **posterior** **medial** **anterior**

Notes:

Appendix V

Provenience _____ Numeric I.D. _____ ASM 8/24/04 Form 24

RIGHT TIBIA

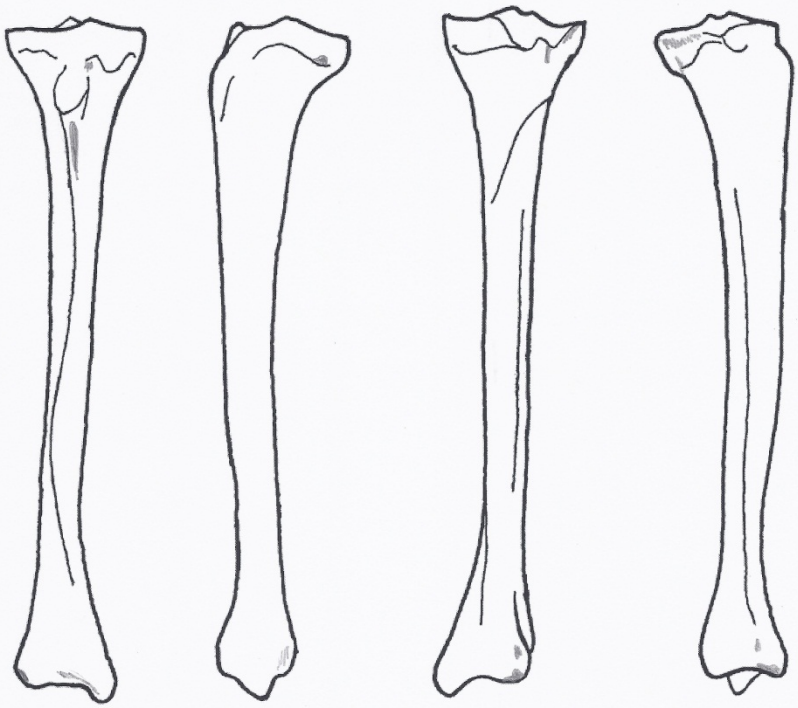

anterior **medial** **posterior** **lateral**

Notes:

Appendix W

Provenience _____ Numeric I.D. _____ ASM 8/24/04 Form 25

LEFT TIBIA

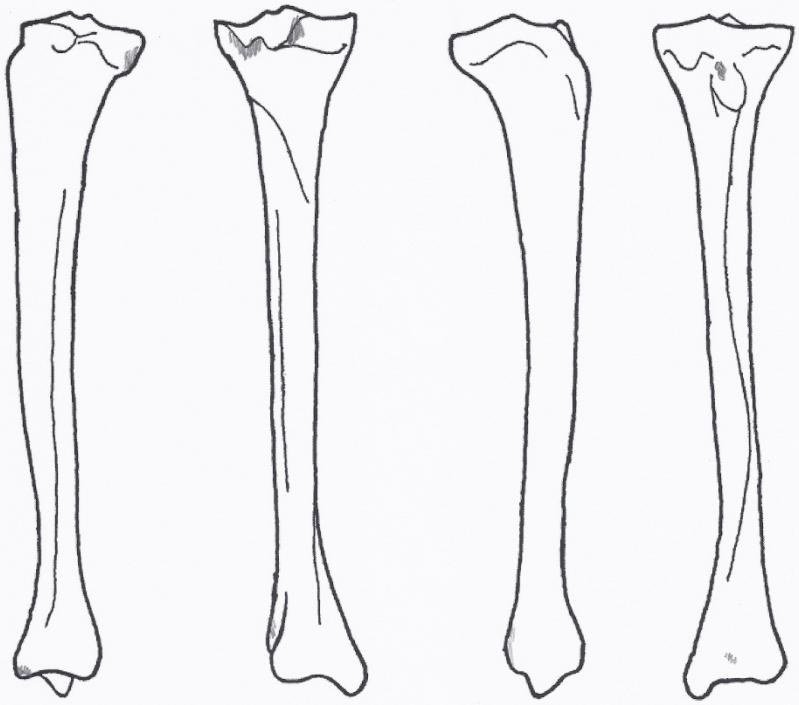

lateral **posterior** **medial** **anterior**

Notes:

Appendix X

Provenience _____ Numeric I.D. _____ ASM 8/24/04 Form 26

RIGHT FIBULA

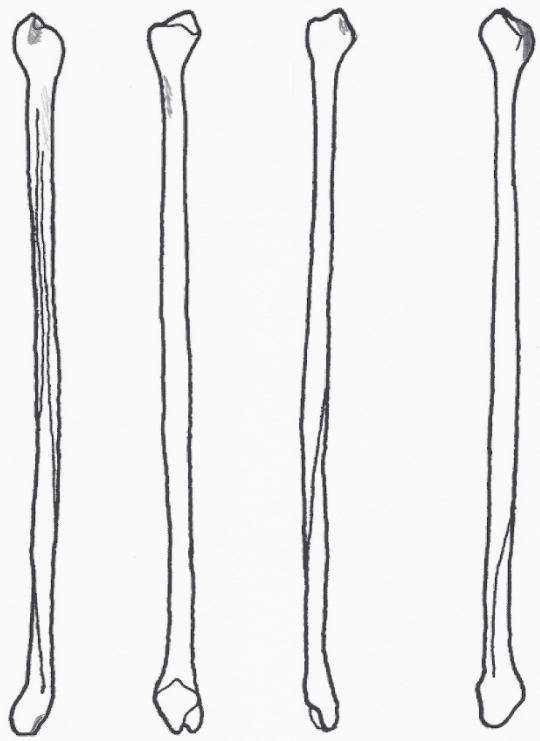

anterior **medial** **posterior** **lateral**

Notes:

Appendix Y

Provenience _____ Numeric I.D. _____ ASM 8/24/04 Form 27

LEFT FIBULA



lateral **posterior** **medial** **anterior**

Notes:

Appendix Z

Provenience _____ Numeric I.D. _____ ASM 8/24/04 Form 28a

RIGHT HAND

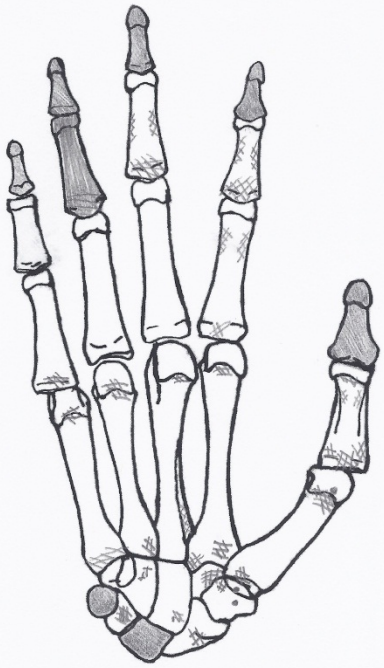

palmar

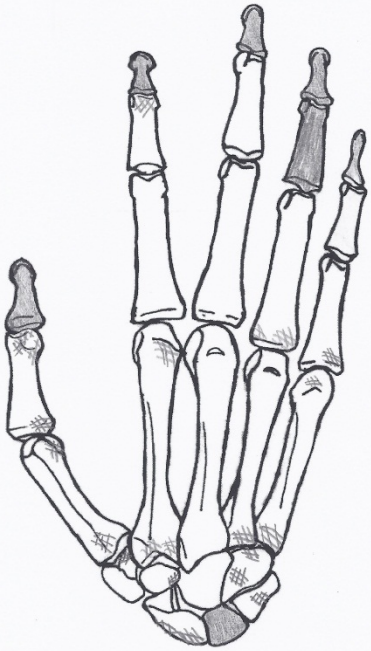

volar

Appendix AA

Provenience _____ Numeric I.D. _____ ASM 8/24/04 Form 28b

LEFT HAND

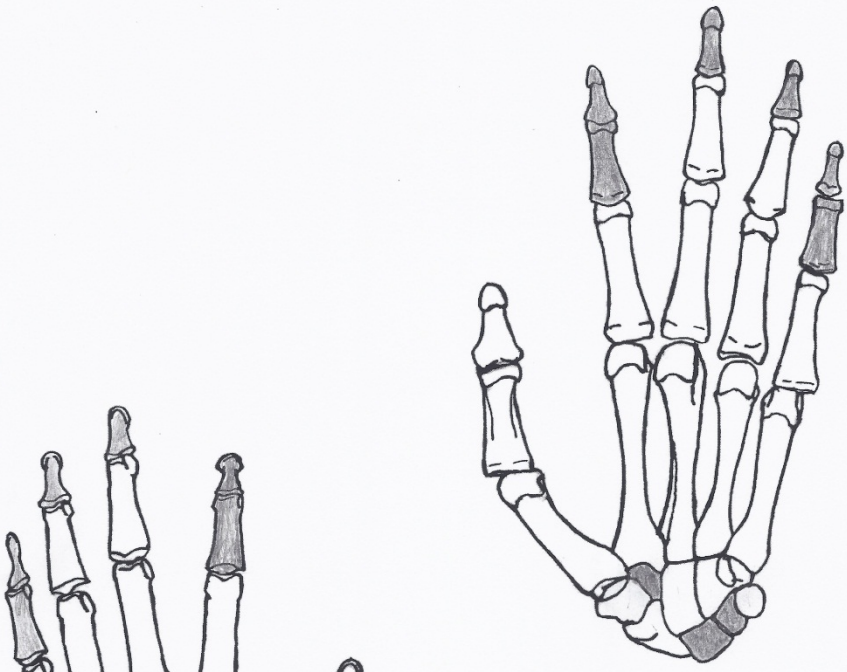

palmar

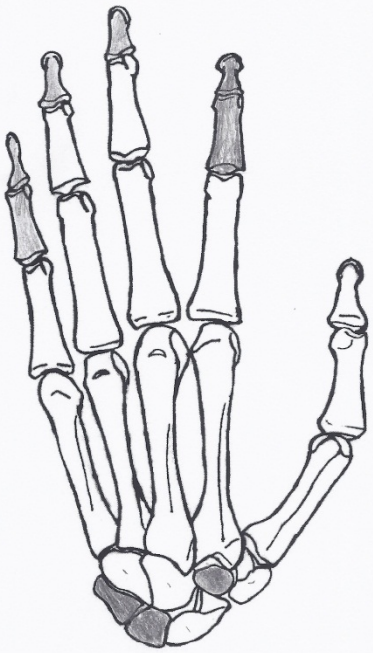

volar

Appendix AB

Provenience _____ Numeric I.D. _____ ASM 8/24/04 Form 29a

RIGHT FOOT

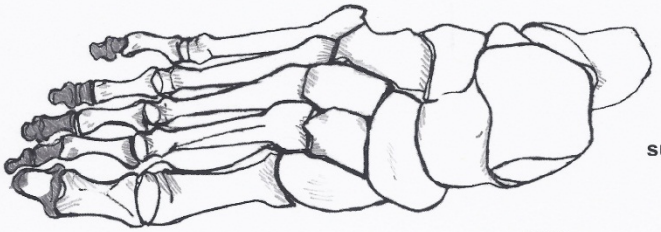

superior

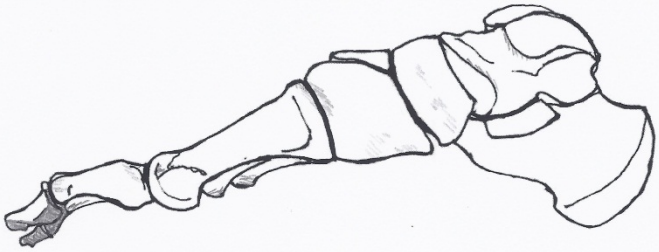

medial

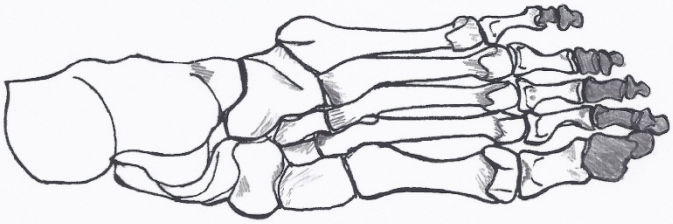

inferior

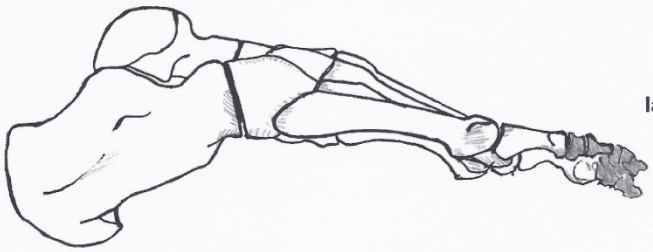

lateral

Appendix AC

Provenience _____ Numeric I.D. _____ ASM 8/24/04 Form 29b

LEFT FOOT

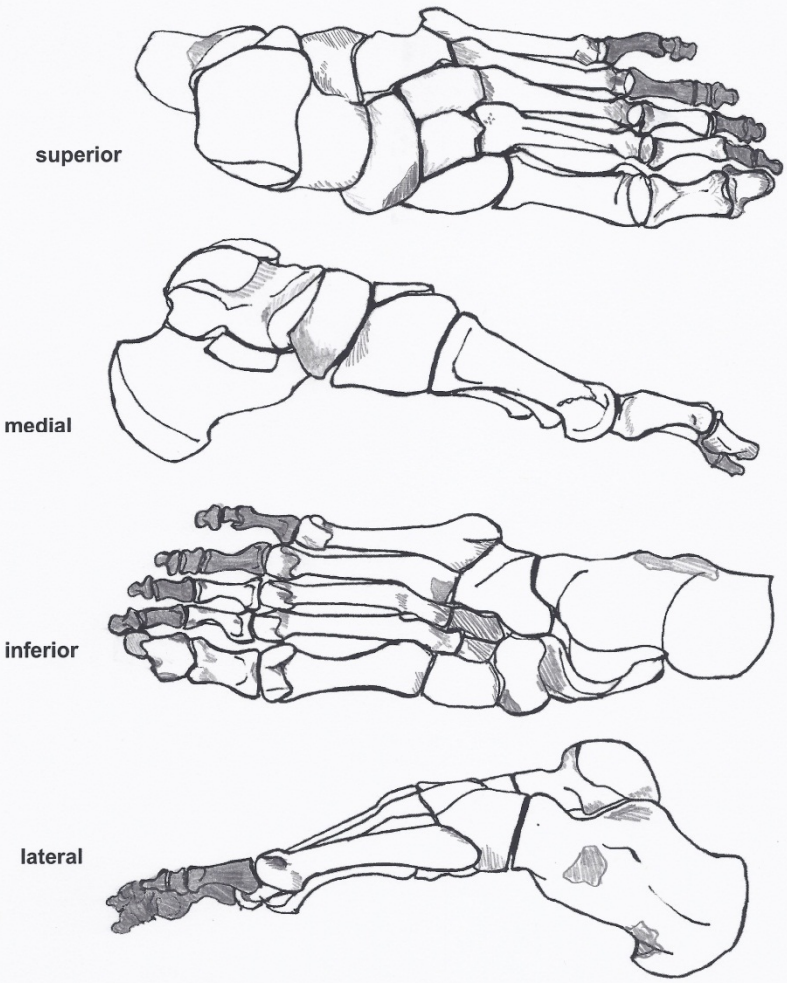

University Honors College Copyright Release Form

We are planning to release this Honors Thesis in one or more electronic forms. I grant the right to publish **my thesis** entitled,
The Skeleton in the Closet: An Historic Forensic Case from Scio, Oregon,
in the Honors College OSU Library's Digital Repository (D-Space), and its employees the nonexclusive license to archive and make accessible, under conditions specified below.

The right extends to any format in which this publication may appear, including but not limited to print and electronic formats. Electronic formats include but are not limited to various computer platforms, application data formats, and subsets of this publication.

I, as the Author, retain all other rights to my thesis, including the right to republish my thesis all or part in other publications.
I certify that all aspects of my thesis which may be derivative have been properly cited, and I have not plagiarized anyone else's work. I further certify that I have proper permission to use any cited work which is included in my thesis which exceeds the Fair Use Clause of the United States Copyright Law, such as graphs or photographs borrowed from other articles or persons.

Signature: *Dawn Marie Alapisco*
Printed Name: Dawn Marie Alapisco
Date: June 5, 2012