OSTEOGENESIS IN THE GOLDEN HAMSTER

by

DEE BEATTY

A THESIS

submitted to

OREGON STATE COLLEGE

in partial fulfillment of
the requirements for the
degree of

MASTER OF SCIENCE

June 1949

APPROVED:

[redacted]

Assistant Professor of Zoology

In Charge of Major

[redacted]

Chairman of Department of Zoology

[redacted]

Chairman of School Graduate Committee

[redacted]

Dean of Graduate School

ACKNOWLEDGMENT

Sincere expression of appreciation is due Dr. Howard Hillemann of the Zoology Department of Oregon State College for suggesting the problem for this thesis, for making available necessary materials and facilities, and for his patient criticism and guidance of the work throughout.

TABLE OF CONTENTS

	Page
INTRODUCTION	1
MATERIALS AND METHODS	3
Animals	3
Table 1	6
Preparation of Specimens	7
OSSIFICATION CENTERS APPEARING IN EMBRYONIC DEVELOPMENT AND DURING THE FIRST SEVEN POST-NATAL DAYS	10
A. Ossification centers in the skeleton excluding the skull	10
B. Ossification centers in the skull	18
ANOMALIES	28
DISCUSSION	30
TABLE 2	32
PLATES	
Plate 1 4 Figures	38
Plate 2 4 Figures	40
Plate 3 4 Figures	42
REFERENCES	43

OSTEOGENESIS IN THE GOLDEN HAMSTER

INTRODUCTION

The golden hamster Cricetus auratus was first described by Waterhouse in 1893 and introduced from Syria into England in 1931. Since then it has been widely adopted as a laboratory animal especially in parasitological and bacteriological work. Its estrus cycle has been described by Deanesly ('38), Kent and Smith ('45), Kupperman, Greenblatt and Hair ('44) and Ward ('46). The blood picture has been reported by Stewart, Florio and Murgrage ('44). Priddy and Brodie ('48) studied the facial musculature, nerves and blood vessels in relation to the cheek pouches and the anatomy and cytology of the pituitary gland has been worked out by Hauke and Charipper ('46). A number of papers deal with its care and nutritional requirements.

Relatively few developmental studies have been made. Samuel and Hamilton ('42) described the living eggs of the hamster. Venable ('46) discussed pre-implantation stages and Ward ('48) implantation and early development. Graves ('45) studied the

development of the embryo during the first nine days after fertilization and Ortiz ('45) outlined the development of the Wolffian and Müllerian ducts and the accessory reproductive organs. Boyer ('48) described the early development of the hamster with special reference to the major circulatory channels.

Since a survey of the literature revealed no work dealing with the skeletal development of the hamster, it is the purpose of this paper to outline the progressive ossification of the hamster skeleton beginning with the first pre-natal ossification center and extending through the seventh post-natal day.

MATERIALS AND METHODS

Animals

The hamsters used in this study were drawn from the colony of about seventy females and ten males established in the Zoology Department at Oregon State College. Most of the animals had been obtained from Quivira Specialties, Topeka, Kansas and from the General Biological Supply House, Chicago.

The hamsters' diet consisted of rabbit pellets, rolled oats, mash, dog biscuits, apples and vegetables together with plenty of water and salt licks.

Embryos of known age were obtained by recording the time of matings. About 7:00 P.M. every evening during the months of November, December, January and early February, 1948-49, males were placed in the mating cages and all of the unmated females were "tried". At first vaginal smears were attempted to determine the stage of the estrous cycle, but it was later found to be easier to place the female in the male's cage for a few minutes and to observe for results. If no interest was displayed, the female was removed and another "tried". If the females were receptive, copulation began almost at once, and was allowed to continue for at least

fifteen minutes. As soon as a female mated she was given a number and a separate cage with the time of copulation being recorded.

During the winter months it was noted that many of the females were markedly unreceptive to the males and that a large percentage of the copulations did not result in pregnancy. Beginning in March the sexual activity was greatly increased and the matings were consistently fertile.

Embryos were collected beginning on the ninth day through the sixteenth day of gestation. The mothers were sacrificed on succeeding days at approximately 7:00 P.M. Thus the series of embryos differed by progressive increments of twenty-four hours.

Post-natal animals were collected on the day of birth and on seven succeeding days at an hour corresponding with the birth hour so that these specimens were also twenty-four hours apart.

The specimens on which this paper is based were accumulated over a period of about six months. With few exceptions none of those of a particular age were all from the same litter. If there was a considerable variation in size, enough additional

animals were collected for that age to establish a norm. It appeared that a rather characteristic size and stage of development was reached on each particular day. A total of 114 skeletons were prepared (Table 1).

TABLE 1

Number of specimens used in the study

Age in days	Number of specimens
Pre-natal	
10	5
11	15
12	14
12½.....	6
13	20
14	8
15	9
Post-natal	
1	9
2	5
3	5
4	3
5	6
6	4
7	5

Preparation of Specimens

Dawson's Alizarin-Red-S bone staining technic found in Lee's The Microtomist's Vade-Mecum was used with some modifications.

The procedure was as follows:

1. Fix animal in 95% alcohol for at least two days.

2. Skin animal if much pigmentation or hair is present and eviscerate.

3. Place animals that have fat deposits in acetone for at least two days. Large fat depots must be picked away.

4. Replace the animal in 95% alcohol for another two days.

5. Clear in aqueous KOH. The strength of the KOH varies with the size of the embryo. A solution of 0.5% may be safely used on most specimens although solutions as weak as .0125% are required for the smallest. Solutions as strong as 1 to 2% may safely be used on larger animals. This step must be watched and the length of time depends on the size of the animal. Prolonged baths in KOH are to be avoided to prevent maceration of soft tissues, but it is essential that the animal

be thoroughly cleared before staining.

6. Stain for 24 hours or longer depending on the size of the animal.

Stock stain:

50% alcohol ..... 300 c.c.
Alizarin red..... 0.5 gms.
Glacial Acetic Acid..... 15 c.c.
Glycerine..... 50 c.c.
Add Alizarin to alcohol and dissolve; then add the acid and glycerine.

Working solution:

Dilute stock stain 2 parts to 70 parts with KOH of the same strength used for clearing.

7. Remove from the stain and wash again in KOH of the same strength used for clearing.

8. If the staining process has been governed closely the bone will have the proper amount of stain and the tissues will be only lightly tinged with red. This tissue coloring will be removed with subsequent treatment. If the animals are overstained they may be destained in a dilute acid-alcohol solution (1% H_2SO_4 in 95% alcohol). Destaining should be avoided if possible, especially on young embryos. The specimen should be washed in water and then placed in acid-alcohol. This process must be watched carefully since a prolonged bath will decalcify and decolorize the bone. Wash in water again.

9. Replace in KOH.

10. Run up to pure glycerine through a graded series of KOH and glycerine prepared as follows:

Glycerine		KOH (% used in clearing)
3 parts	to	7 parts
5 parts	to	5 parts
7 parts	to	3 parts

Removal of stain from tissues occurs during this treatment and the process may be speeded up with application of low heat or by placing the clearing specimens in strong sunlight.

11. Store finished specimens in pure glycerine with a few grains of thymol.

OSSIFICATION CENTERS APPEARING IN EMBRYONIC DEVELOPMENT AND DURING THE FIRST SEVEN POST-NATAL DAYS

All references to bones in this paper concern only their ossified centers or portions. In every case the first appearance of ossification is recorded and the maximum number of centers is reported for each age.

A. Ossification centers in the skeleton excluding the skull.

Gestation day 12

The first centers of ossification appear on the twelfth day of gestation. Of the eleven embryos examined five show a small ossifying center in the clavicle.

Gestation day 12½

Since day 13 showed a great increase in number of ossifying centers over day 12, it was thought desirable to examine an intermediate stage. Embryos examined at 12½ days of gestation were found to have ossification in the vertebro-costal

ribs, 5 through 13. The ribs grade imperceptibly in length, with the middle members of the series being longer than those toward either end.

The humerus begins at this age as a short cylinder in the middle of the diaphysis.

Gestation day 13 (Plate 1 Fig. 1)

In addition to the previously ossifying humerus the radius now appears as a short thin-walled tube ending abruptly in the middle of the diaphyseal cartilage. The ulna likewise makes an appearance on this day.

Ossification in the scapula begins near its vertebral end along with a portion of the spinous process already separating the supra and infra-spinous fossae.

The three main bones of the hind limb, the femur, tibia and fibula appear on this day for the first time as small cylinders in the cartilaginous diaphysis.

Vertebrocostal ribs 1 to 4 are added to complete the series.

The first ossification of the pelvic girdle

makes its appearance at this time in the ilium.

Neural arches are also beginning. These consist of cervicals 1 through 7, thoracics 1 through 13 and lumbars 1 through 4.

Gestation day 14

Two lumbar neural arches are added to make a total of six. Three sacral neural arches are present. The first ossification of vertebral bodies occurs on this day and involves thoracics 2 through 13, lumbars 1 through 6, and sacrals 1 through 2. These centra appear one day later than the first vertebral arch ossifications.

Gestation day 15 (Plate 1 Fig. 2)

On the fifteenth day of gestation the 3rd phalanx on digits 2 through 5 appear in the manus while the pes shows development of the 3rd phalanx on digits 1 through 5. These terminal phalanges are small cone-tipped cylinders.

Metacarpals and metatarsals 2, 3, and 4 are present for the first time.

The two remaining bones of the pelvic girdle, the ischium and pubis, now show small ossification

centers.

Cervical centra 3 through 7 appear for the first time. The first thoracic centrum is now ossifying to make a total of 13, while the addition of the 3rd sacral centrum completes that series. Four caudal centra are present. All neural arches for the above mentioned centra are formed in addition to two extra caudal neural arches.

Components of the sternum make their first appearance at this time. The posterior end of the manubrium is beginning in two separate centers. Sternebrae 1, 2 and 5 are present.

Post-natal day 1

In the manus phalanx 1 of digits 2, 3, and 4 appears as a thin ring of ossification in the cartilaginous diaphysis. The fifth metacarpal is also present. In some specimens metatarsals 1 and 5 are added as is digit 1 of phalanx 1.

The vertebral column shows additions both anteriorly and posteriorly. Caudal bodies 5 to 9 are present and all but the last four have beginnings of neural arches. Neural arches are fused to to the first six tail centra and the three sacral neural arches are fusing with their centra. The first two cervical bodies, the atlas and axis, are now present. The hypocentrum of the atlas begins as a small round center of ossification lying midventrally within the cartilaginous ring of the atlas. The odontoid process of the axis appears as a very small spot of ossification cephalic to the ossifying center of the axis centrum.

The paired centers of the manubrium are beginning to fuse and with the addition of sternebrae 3 and 4 that series is completed.

Post-natal day 2

Additional ossification has occurred in the phalanx of the pes. Phalanx 1 and 2 on digits 2 through 5 complete the series. The fibulare (calcaneus) begins as a cylindrical ossification center at the bend of the hind foot midway between the posterior end of the tibia and the first phalanx of the fifth digit.

In the manus, phalanx 2 on digits 1, 2, 3, 4 and 5 and phalanx 1 on digit 5 appear in the form of the usual band-shaped ossification centers. Metacarpal 1 is also present.

The vertebro-costal portions of the ribs have ossified to the costochondral junction.

The medial articulating process of the ilium is extending toward the second sacral vertebra.

Post-natal day 3

On the third post-natal day no new bones are added, but a gradual enlargement and change in shape can be noted in the previously mentioned centers. The neural arches of the three sacral vertebrae and the first four caudal vertebrae are

fused with their centra.

Nutritive foramina in the infraspinous fossa of the scapula may be seen near the spine.

The verteb-arterial foramina for cervicals 3, 4 and 5 have formed by this time.

Post-natal day 4 (Plate 1 Fig. 3)

A tenth caudal centra is noted and the first five caudal bodies now have neural arches. The verteb-arterial foramina of the sixth cervical vertebra is complete. The carotid tubercle (Chassaignac's tubercle), a costal element peculiar to the sixth cervical vertebra is distinct at this time.

In the heel the tibiale (talus) now appears as a center of ossification at the same level but medial to the fibulare (calcaneus).

Post-natal day 5

There is little or no change except a general increase in size. The fifth caudal neural arches are seen fused to their centra.

Post-natal day 6

Changes noted are the addition of phalanx 1 of digit 1 in the manus and a minute beginning of an epiphyseal center on the proximal end of the humerus.

Also, the verteb-arterial foramina of the second cervical vertebra is completed.

An hourglass-shaped os priapi (baculum) was found in one male specimen.

Post-natal day 7 (Plate 1 Fig.4)

Another caudal vertebra is present to make a total of eleven. Fusion of the vertebral arches on the dorso-median line can be seen in lumbars 1 and 2, sacrals 1, 2 and 3, and caudals 1 and 2.

There is an ossification in the epiphysis at the distal end of both the femur and humerus.

The tibiale (talus) and fibulare (calcaneus) are enlarged and a center of ossification in the position of the future cuboid is added.

Three carpals are noted. These are: the ulnare (triangular) distal to the ulna, the radiale (navicular) distal to the radius, the intermedium

(lunate) distal to the radius but between the radiale and ulnare.

The first sesamoid, the patella, appears at this time.

B. Ossification centers in the skull.

Gestation day 12

The first ossification centers in the skull begin on the twelfth day of gestation. The dentary appears as a small center lateral to Meckel's cartilage toward its caudal end and the maxilla may be identified as a small irregular patch.

Gestation day 12½

No additional centers have appeared although those already present have extended their limits somewhat.

Gestation day 13 (Plate 2 Fig.1)

Marked progress in development has occurred and many new bone centers may be distinguished.

The dentary is rapidly investing Meckel's cartilage both craniad and caudad.

The zygomatic process of the maxilla is evident and another separate center of ossification in the maxilla can be seen anterior to the orbit.

The paired premaxillae appear as rather elongated centers anterior to the maxillae and extending toward the snout. The incisors of the upper jaw have erupted.

The paired squamosals arise as slender bars from which the zygomatic process is already protruding.

The frontals appear as relatively large reticular plates dorsal to the orbit.

A very small center of ossification is beginning in each of the parietals posterior to the frontals.

A ventral view of the skull reveals further development. The exoccipitals are rather large centers lying on either side of the V-shaped basioccipital the point of which is directed anteriorly.

Anterior to the basioccipital and in the same plane, the basisphenoid may be seen as a small ossification center. The medial pterygoid processes or hamuli (presumably homologous with the entopterygoids of lower forms) are well developed and lie ventral to the basisphenoid on either side of the

median pterygoid fossa.

A pair of palatines are seen developing immediately anterior to these pterygoid processes of the basisphenoid.

Lateral to the palatines the irregular centers of the alisphenoids are visible.

Midway between the developing centers of the maxillae and the premaxillae, the vomer appears as a short horizontal plate pointed at the anterior end and lying against the ventral side of the mesethmod region. Extending from the median line of the vomer near its anterior end is a perpendicular keel directed ventrally toward the medial line of fusion of the palatine processes of the maxillaries.

Gestation day 14 (Plate 2 Fig. 2)

New bones to appear on this day are the nasals, zygomatics, ectotympanics, and supraoccipitals.

The zygomatic (malar, jugal) manifests itself as a very slender sickle-shaped ossification center lying free between the zygomatic processes of the maxilla and squamosal.

The nasal bones ossify as two bars, one on either side of the median dorsal line.

The supraoccipital arises as two circular areas connected by a slender commissure in the postero-dorsal region of the skull.

The slender sickle-shaped ectotympanic lies ventro-laterally to the basisphenoid, and is considered to represent the angular of the lower jaw of reptiles.

Further expansion of the bones of the previous day is observed. An anterior median notch occurs in the basisphenoid and represents the incompletely established cranio-pharyngeal canal. The ento-pterygoid on either side has contacted the basisphenoid and the line of demarcation between the two is barely visible. Both the frontals and parietals have greatly extended in area.

The dentary is approaching the squamosal; the coronoid, cotyloid and angular processes of the dentary are also evident as trabeculae directed toward their future limits. The incisors of the lower jaw have erupted. Alveoli for the molars in both the maxilla and mandible are present.

A large infra-orbital foramen in the maxilla has been established.

Gestation day 15 (Plate 2 Figs. 3-4)

Paired interparietals (postparietals, dermosupraoccipitals) are first represented as thin lines of scattered centers on either side immediately anterior to the supraoccipitals (endochondral).

The lacrimals are now apparent in the anterior wall of the orbit.

The orbitosphenoids arise on either side dorso-laterally to the presphenoid and antero-medially to the alisphenoids.

The basihyal can be recognized as a median calcified cartilage in the form of a short transverse bar with a slight curvature opening dorsally.

What probably represents the pre-articular dermal bone (goniale, post opercular) of the lower jaw of sauropsids (the processus anterior p. gracilis, p. folii of the malleus of mammals generally) makes its appearance in close association with the anterior limb of the U-shaped ectotympanic and is found medially to it as in other myomorphs.

There is one lateral scroll on each premaxilla. It arises in continuity with the postero-medial border of the premaxilla (anterior margin of the incisive foramen) as a vertical half

cylinder longitudinally disposed with the concavity directed toward the cartilaginous septum of the mesethmoid.

Medial to the orbit and inside the cranium the frontal bone develops an oblique ridge directed cephalocaudad. This pair of ridges (one on either side) contact the cartilaginous cribriform plate of the ethmoid.

The condylar canal is still a notch in the exoccipital.

The posterior end of the zygomatic (malar, jugal) lies below the zygomatic process of the squamosal, and its anterior end lies dorsal to the zygomatic process of the maxilla.

Further extensions of bones previously described may be noted. The palatines and the alisphenoids on either side have met. The premaxillae, maxillae and palatines have established the secondary hard or false palate. Some of the roofing bones of the skull overlap. In particular, the lateral edge of the parietal overlies the upper edge of the squamosal and the anterior edges of both the parietal and squamosal overlie the rear edge of the frontal.

Post-natal day 1 (Plate 3 Fig. 1)

No new bones begin development on this day, but further extensions of bones previously established are noticeable.

The palatines have extended laterally and the alisphenoids medially to form a line of junction. The palatines have also extended caudad and have contacted the pterygoids (entopterygoid of reptiles). The pterygoid on either side has fused with the basisphenoid. The pterygoid also shows a lateral extension from its dorsal end.

The lower edge of the squamosal overlies the upper edge of the alisphenoid. The orbitosphenoids have united with the presphenoid to form the sphenethmoid.

The condylar foramen in each exoccipital is now completed.

The interparietals are united on the median line.

The first upper molar makes its appearance and in the mandible the first two molars have also broken through. Mental foramina are established in the mandible.

Post-natal day 2 (Plate 3 Fig. 2)

There is an ossification center in both the cephalic and caudal regions of the periotic (petrosal), corresponding with the pro- and opisthotic areas respectively.

The tympanic bulla (entotympanic) is first indicated in a small center in its caudal aspect medial and caudal to the posterior limb of the ectotympanic.

The posterior ends of the vomer have extended back to the presphenoid. The median process of the vomer has reached the palatine process of the maxillaries on the median line thus dividing the nasal passage into right and left sides. The keel of the vomer has also met the scrolls of the premaxillaries. Anteriorly the vomer extends obliquely dorsally to the medial wings of the premaxillae which form the anterior part of the nasal septum.

The posterior ends of the nasals and premaxillae have extended back over the anterior ends of the frontals. The second upper molar has erupted.

Post-natal day 3

The cranio-pharyngeal canal in the basisphenoid is reduced to a small aperture.

Post-natal day 4 (Plate 3 Fig.3)

Ossification is extended in both the pro- and opisthotic areas.

An ossification may be seen in the free end of a finger-like process in the ethmoturbinal on either side.

Post-natal day 5

The tympanic bulla is nearly complete in outline.

The periotic (petrosal) is well advanced with its ossifying rudiments united. Each pterygoid has sent from its dorsal end a process directed obliquely toward the tympanic bulla.

There is a total of eight islands of ossification in the ethmoturbinal and also an additional turbinal on either premaxilla medial to the alveolus of the incisor.

A central foramen is seen in the presphenoids.

Post-natal day 6

Ossification of the cribriform plate of the ethmoid occurs mainly in paired lateral areas, however, scattered independent smaller ossification centers appear on either side. The main paired ossification centers show a series of perforations for the fillia olfactoria (Olfactory I).

All three upper and lower molars are present.

Post-natal day 7 (Plate 3 Fig. 4)

The frontal and occipital fontanels are quite small and all other sutures are well established.

Increased ossification in the cribiform plate of the ethmoid is noted.

ANOMALIES

Various anomalies were noted. Ribs were frequently found to have vestigial centers on either side of the first lumbar vertebrae. The arrangement of these remnants varied. Sometimes an ossification center was found on one side only; occasionally an ossification was more extensive than its mate. Fusions of adjacent ribs were also seen. In one specimen of post-natal day 3, the proximal ends of ribs 10 and 11 on the left side were fused. Another specimen of the same age showed a fusion of the middle portions of ribs 7 and 8. A post-natal day 5 animal had a pair of vestigial ribs with the rib on the left side being fused to the neural arch of lumbar vertebra 1 by a slender neck of ossification. One animal of post-natal day 6 had an abnormally short thirteenth rib on the right side.

In the sternum of one specimen there were five alternating rudiments between the second and fifth sternebrae, with two rudiments on the left side and three on the right. Several specimens were found to have a third ossification center between and ventral to the regular two centers of the fifth sternebrae.

The axis centrum in two post-natal day 1 animals was found to begin ossification in paired centers, transversely arranged.

Several rather dense discrete circular plates of variable size were found in the walls and neck of the urinary bladders of two post-natal day 2 animals. These structures consisted of a resistant and brittle material which took on a deep hue with Alizarin Red S, resembling somewhat normal ossification centers in this respect. One animal had two such areas and the other three.

Portions of the umbilical cord near the body of 14 and 15 day gestation embryos were found to contain short cylindrical areas which like bone took on a deep red color. These cylinders did not end abruptly but seemed to shade imperceptibly into the unstained regions both proximally and distally. Upon manipulation with forceps, this red tissue was found to be quite yielding.

DISCUSSION

This paper has dealt primarily with the first appearance of ossification centers in the hamster skeleton and the charted data (Table 2) will be found to be self-explanatory. However, it is of interest to note the correlation of the rapid rate of ossification with the precocious development of the hamster. This animal has the unusually short gestation period of sixteen days. Since the first ossification was found to begin on the twelfth day of gestation, this allows only four days of bone development before birth. During this short period the greater portion of the entire skeleton is represented by ossification centers and in many cases the characteristic shape of the definitive structure may be seen.

By the time of birth the vertebrae are well represented but the degree of fusion of the elements is insignificant even through the seventh post-natal day. All bones of the pelvic and pectoral girdles are represented before birth and the sternum is complete except for the last two sternebrae which ossify on the first post-natal day. The long bones of the fore and hind limbs are well developed before

birth, but epiphyseal centers do not begin until the sixth and seventh post-natal days. Tarsals and carpals begin ossification toward the end of the first post-natal week. Some of the phalanges of both the fore and hind limbs begin to ossify prenatally but most of them do so in the early post-natal days.

By the time of birth most of the bones of the adult skull are represented. Three bones, the periotic, entotympanic and cribriform plate of the ethmoid, appear during the first week of post-natal life. At the end of the first seven post-natal days the skull bones have greatly expanded and sutures are established.

Rapid ossification is coupled with a rapid increase in body size and both occur during such a short period of time that the development of the hamster may be spoken of as "explosive".

TABLE 2

First appearances of ossification centers in the golden hamster

Ossification Center	Age Period	
	Days prenatal	Days postnatal
Vertebral bodies:		
Cervicals 3-7	15	
Cervicals 1-2		1
Odontoid process.....		1
Thoracics 2-13	14	
Thoracic 1.....	15	
Lumbars 1-6.....	14	
Sacrals 1-2.....	14	
Sacral 3.....	15	
Caudals 1-4.....	15	
Caudals 5-9.....		1
Caudal 10.....		4
Caudal 11.....		7
Vertebral arches:		
Cervicals 1-7.....	13	
Thoracic 1-13.....	13	
Lumbars 1-4.....	13	
Lumbars 5-6.....	14	
Sacrals 1-3.....	14	
Caudals 1-6.....	15	
Ribs:		
Vertebrocostals 5-13..	12½	
Vertebrocostals 1-4...	13	
Sternum:		
Manubrium.....	15	
Sternebrae 1,2,5.....	15	
Sternebrae 3,4.....		1
Pectoral girdle:		
Scapula.....	13	
Spinous process.....	13	
Clavicle.....	12	

TABLE 2 (Continued)

Ossification Center	Age Period	
	Days prenatal	Days postnatal
Pelvic girdle:		
Ilium.....	13	
Ischium.....	15	
Pubis.....	15	
Upper and fore arm:		
Humerus.....	12½	
Proximal epiphysis...		6
Distal epiphysis.....		7
Radius.....	13	
Ulna.....	13	
Carpals:		
Radiale (Navicular)..		7
Intermedium (Lunate).		7
Ulnare (Triangular)..		7
Metacarpals:		
First.....		2
Second.....	15	
Third.....	15	
Fourth.....	15	
Fifth.....		1
Forelimb digits:		
Digit One		
Phalanx One.....		6
Phalanx Two.....		2
Digit Two		
Phalanx One.....		1
Phalanx Two.....		2
Phalanx Three.....	15	
Digit Three		
Phalanx One.....		1
Phalanx Two.....		2
Phalanx Three	15	
Digit Four		
Phalanx One.....		1
Phalanx Two.....		2
Phalanx Three.....	15	

TABLE 2 (Continued)

Ossification Center	Age Period	
	Days prenatal	Days postnatal
Forelimb digits:		
Digit Five		
Phalanx One.....		2
Phalanx Two.....		2
Phalanx Three.....	15	
Thigh and shank:		
Femur.....	13	
Distal epiphysis.....		6
Tibia.....	13	
Fibula.....	13	
Tarsals:		
Tibiale (Talus).....		4
Fibulare (Calcaneus).		2
Cuboid.....		7
Metatarsals:		
First.....		1
Second.....	15	
Third.....	15	
Fourth.....	15	
Fifth.....		1
Hindlimb digits:		
Digit One		
Phalanx One.....		1
Phalanx Two.....	15	
Digit Two		
Phalanx One.....		2
Phalanx Two.....		2
Phalanx Three.....	15	
Digit Three		
Phalanx One.....		2
Phalanx Two.....		2
Phalanx Three.....	15	

TABLE 2 (Continued)

Ossification Center	Age Period	
	Days prenatal	Days postnatal
Hindlimb digits:		
Digit Four		
Phalanx One.....		2
Phalanx Two.....		2
Phalanx Three.....	15	
Digit Five		
Phalanx One.....		2
Phalanx Two.....		2
Phalanx Three.....	15	
Sesamoids:		
Patella.....		7
Miscellaneous:		
Os priapi (baculum)..		6
Skull:		
Dermatocranium		
Dentary.....	12	
Frontal.....	13	
Entopterygoid (hamulus)	13	
Interparietal.....	15	
Lacrimal.....	15	
Maxilla.....	12	
Nasal.....	14	
Palatine.....	13	
Parietal.....	13	
Premaxilla.....	13	
Squamosal.....	13	
Ectotympanic.....	14	
Vomer.....	13	
Zygomatic.....	14	
Chondrocranium		
Alisphenoid.....	13	
Basisphenoid.....	13	
Basioccipital.....	13	
Cribriform plate(ethmoid)		6
Entotympanic.....		2
Exoccipital.....	13	
Orbitosphenoid.....	15	

TABLE 2 (Continued)

Ossification Center	Age Period	
	Days prenatal	Days postnatal
Skull:		
Chondrocranium		
Periotic (Petrosal)		
Opisthotic.....		2
Prootic.....		2
Presphenoid.....	15	
Supraoccipital.....	14	
Visceral arch cartilages		
Basihyal (calcified).	15	

PLATE 1

Fig. 1	13 day prenatal	side view	X 4
Fig. 2	15 day prenatal	side view	X 2.4
Fig. 3	4 day postnatal	dorsal view	X 1.4
Fig. 4	7 day postnatal	ventral view	X 1.2

Key to Abbreviations

at	atlas	mt	metatarsal
bh	basihyal	mx	maxilla
ca	caudal	oo	opisthotic
cl	clavicle	pa	parietal
dn	dentary	ph	phalanx
dp	distal epiphysis	pm	premaxilla
ec	ectotympanic	pu	pubis
ex	exoccipital	ra	radius
fb	fibula	sa	sacral
fe	femur	sb	sternebrae
fr	frontal	si	spinous process
fu	fibulare	so	supraoccipital
hu	humerus	sp	scapula
il	ilium	sq	squamosal
ip	interparietal	tb	tibia
is	ischium	te	tibiale
lb	lumbar	ul	ulna
mc	metacarpal	vo	vomer
		zy	zygomatic

PLATE 1

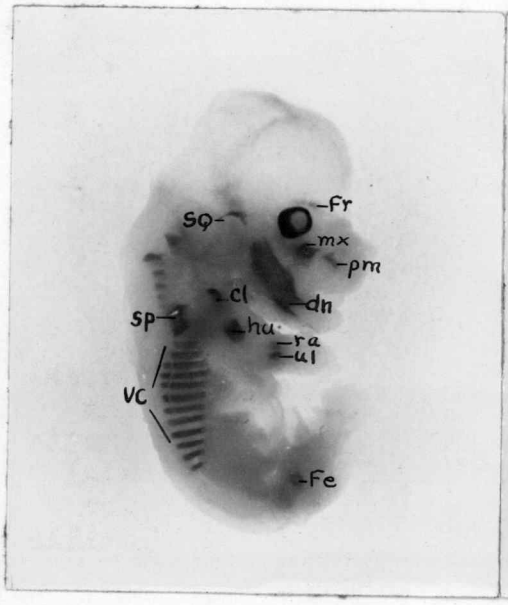

Fig. 1

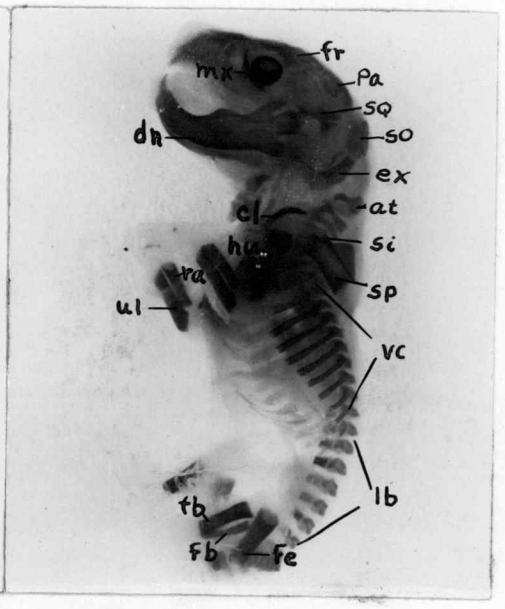

Fig. 2

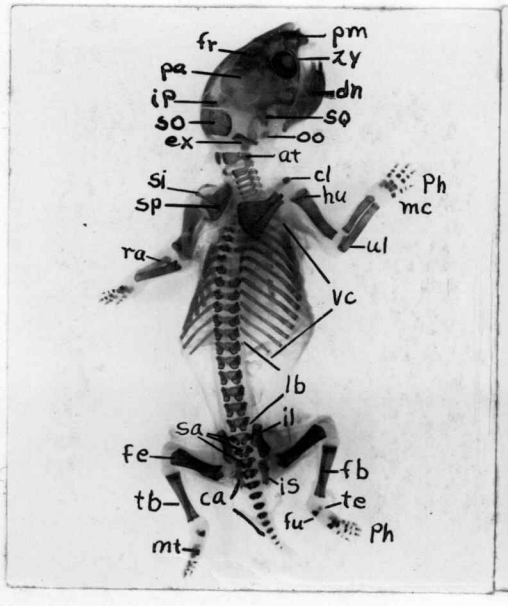

Fig. 3

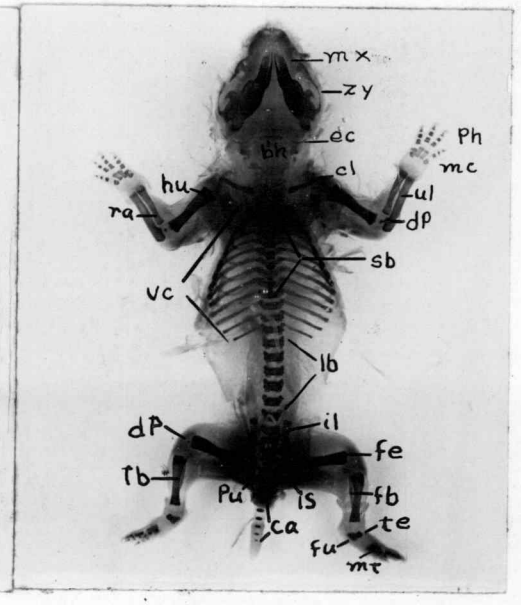

Fig. 4

PLATE 2

Fig. 1	13 day prenatal	ventral view	X 11.7
Fig. 2	14 day prenatal	ventral view	X 10
Fig. 3	15 day prenatal	dorsal view	X 7
Fig. 4	15 day prenatal	ventral view	X 7

Key to Abbreviations

al	alisphenoid
at	atlas
bo	basioccipital
bs	basisphenoid
cc	craniopharyngeal canal
ec	ectotympanic
ep	entopterygoid
ex	exoccipital
mx	maxilla
os	orbitosphenoid
pl	palatine
pm	premaxilla
pr	prearticular
ps	presphenoid
sq	squamosal
vo	vomer
zy	zygomatic

PLATE 2

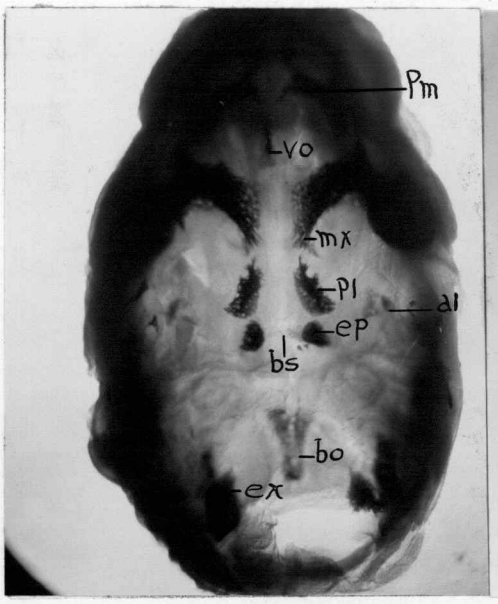

Fig. 1

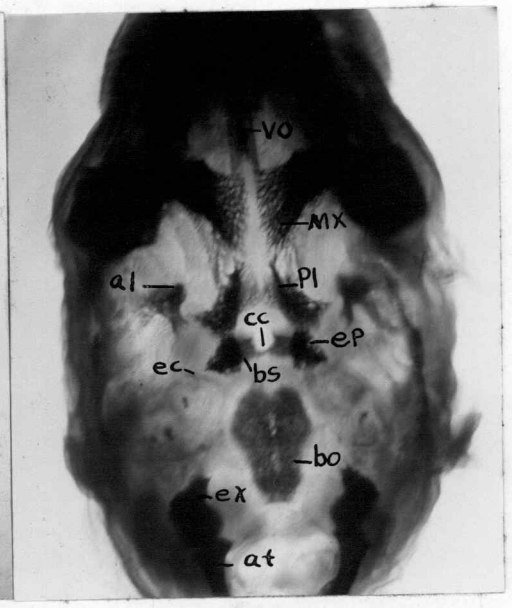

Fig. 2

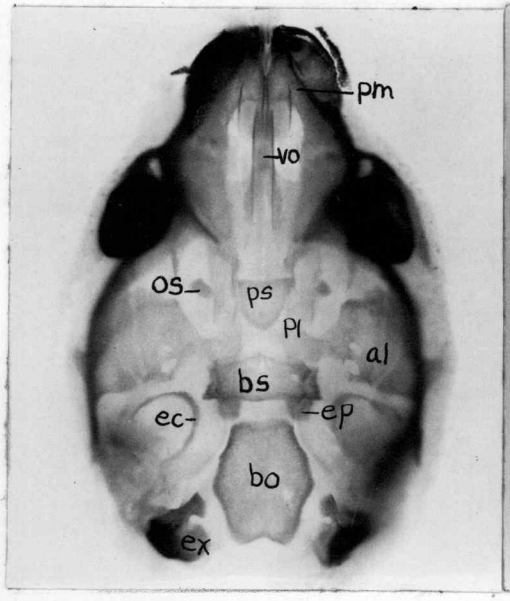

Fig. 3

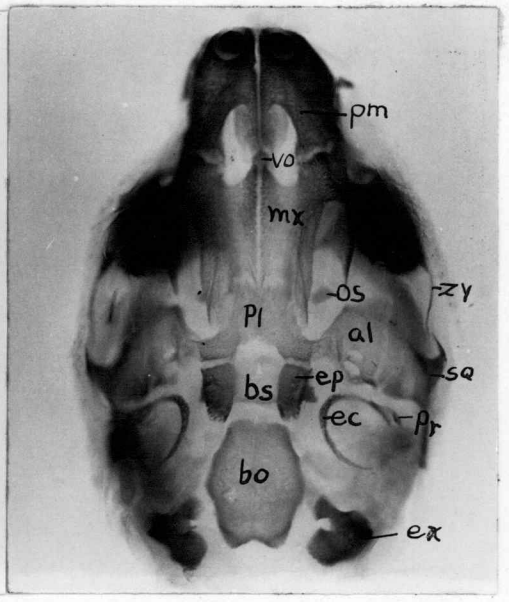

Fig. 4

PLATE 3

Fig. 1	1 day postnatal	ventral view	X 6
Fig. 2	2 day postnatal	ventral view	X 4.7
Fig. 3	4 day postnatal	dorsal view	X 4.7
Fig. 4	7 day postnatal	ventral view	X 4.7

Key to Abbreviations

al	alisphenoid
at	atlas
bh	basioccipital
bs	basisphenoid
cp	cribriform plate of ethmoid
ec	ectotympanic
ip	entopterygoid
ex	exoccipital
fr	frontal
ha	hypocentrum of atlas
la	lacrimal
mx	maxilla
oo	opisthotic
pl	palatine
pm	premaxilla
pr	prearticular
ps	presphenoid
pt	periotic

PLATE 3

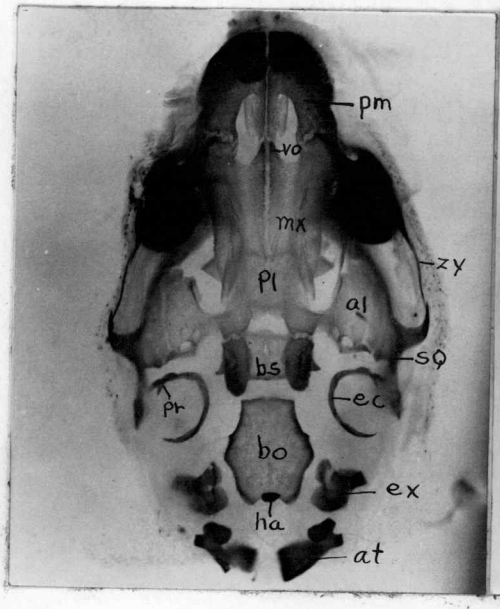

Fig. 1

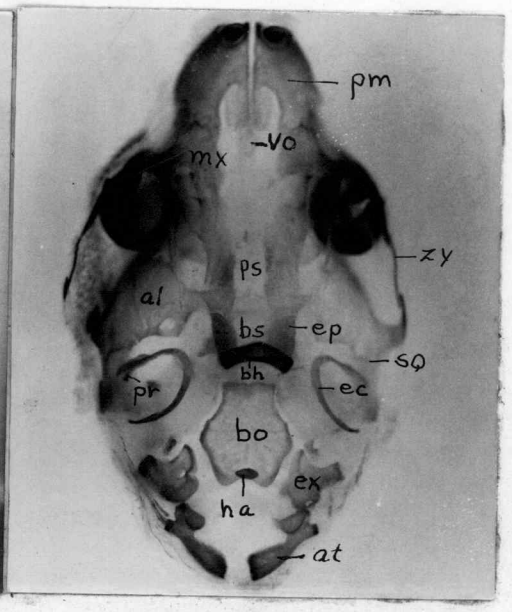

Fig. 2

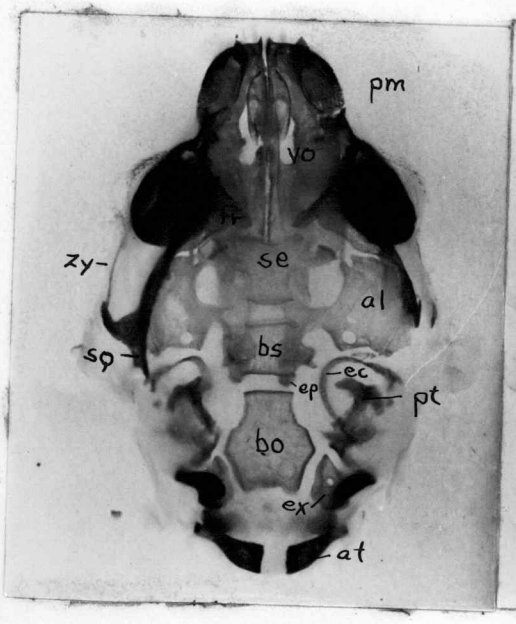

Fig. 3

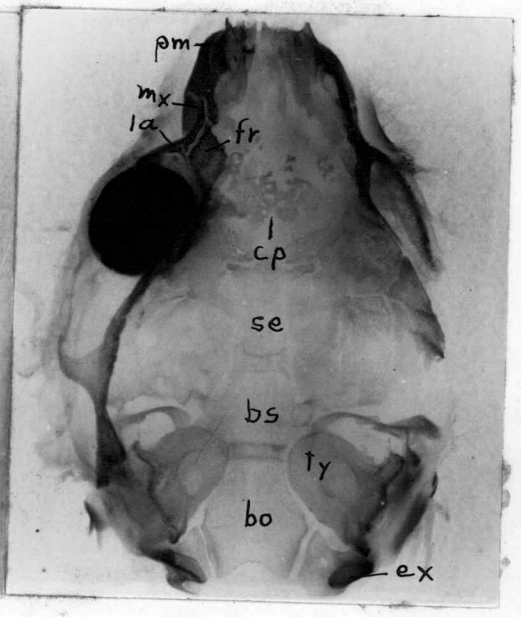

Fig. 4

REFERENCES

Boyer, Charles C. 1948 Development of the golden hamster Cricetus auratus, with special reference to the major circulatory channels. Journ. Morph. 83: 1-38.

Deanesly, R. 1938 The reproductive cycle of the golden hamster (Cricetus auratus). Proc. Zool. Soc. Lond. Ser. A 108: 31-37.

de Beer, G. R. 1937 The development of the vertebrate skull. Oxford, Clarendon Press.

Graves, Artis Paris 1945 Development of the golden hamster, Cricetus auratus Waterhouse, during the first nine days. Amer. Jour. Anat. 77 (2): 219-244.

Greene, Eunice Chace 1935 Anatomy of the rat. Trans. Amer. Phil. Soc., vol. 27.

Hauke, Harriet H. and Harry A. Charipper 1946 The anatomy and cytology of the pituitary gland of the golden hamster, Cricetus auratus. Anat. Rec. 96 (4): 563.

Kent, George C. and Ralph A. Smith 1945 A study of the estrous cycle in the golden hamster, Cricetus auratus. Anat. Rec. 92: 263-371.

Kupperman, H. S., R. B. Greenblatt and L. Q. Hair 1944 The sexual cycle and reproduction in the golden hamster. Anat. Rec. 88: 441.

Lee, Arthur Bolles 1937 The Microtomist's Vade-Mecum. Ed. 10. Philadelphia, P. Blakiston's Son and Co.

Ortiz, Evelina 1945 The embryological development of the Wolffian and Müllerian ducts and the accessory reproductive organs of the golden hamster (Cricetus auratus). Anat. Rec. 92: 371-389.

REFERENCES (Continued)

Priddy, Ralph B. and Arnold F. Brodie 1948 Facial musculature, nerves and blood vessels of the hamster in relation to the cheek pouch. J. Morph. 83: 149-180

Samuel, D. M. and W. J. Hamilton 1942 Living eggs of the golden hamster. Jour. Anat. 76 (2): 204-209.

Stewart, Mabel O., Lloyd Florio and Edward R. Murgrage 1944 Hematological findings in the golden hamster (Cricetus auratus). Jour. Exp. Med. 80 (3): 189-196.

Strong, R. M. 1925 The order, time and rate of ossification of the albino rat (Mus norvegicus albicans) skeleton. Amer. Jour. Anat. 36: 313-353.

Venable, John H. 1946 Pre-implantation stages in the golden hamster (Cricetus auratus). Anat. Rec. 94 (1): 105-117.

Ward, Margaret C. 1946 A study of the estrous cycle and the breeding of the golden hamster, Cricetus auratus. Anat. Rec. 94: 139-161.

Ward, Margaret C. 1948 The early development and implantation of the golden hamster, Cricetus auratus, and the associated endometrial changes. Amer. Jour. Anat. 82 (2): 231-275.