

AN ABSTRACT OF THE THESIS OF

Emma Gordon for the degree of Master of Science in Veterinary Science presented on July 25, 2016

Title: Evaluation of Topical Application of 1% Morphine Sulfate Solution as an Analgesic on the Healthy Equine Eye.

Abstract approved:

John W. Schlipf Jr.

Abstract:

Corneal ulcers are one of the most common eye conditions of the horse, with potentially serious complications such as loss of vision or the eye itself. They are extremely painful due to the large number of sensory nerve endings found in the cornea. Horses frequently show signs of ophthalmic pain despite systemic analgesics, which have side effects including renal and gastrointestinal toxicity, and CNS excitement. Morphine applied topically to the eye has been shown to have a rapid onset of action in rabbits, dogs and humans and provides effective analgesia without deleterious side effects on corneal healing. Despite investigation of topical ophthalmic morphine in other species, there are no published reports for its use in horses.

In the first study detailed here, we evaluated whether or not short term administration of 1% morphine sulfate was safe to use on the equine cornea and whether this morphine would be absorbed into the serum, aqueous, or vitreous. Morphine was applied topically

to one eye of six horses every four hours for 72 hours before euthanasia. Serum samples were collected at varying time points during the study and ocular fluid collected immediately after euthanasia. Treated and control corneas were sent for histopathology. Horses showed no systemic or ocular adverse effects. Corneal histopathology confirmed there was no difference in microscopic appearance between morphine treated and control corneas. Morphine was detected by ELISA in aqueous humor of the treated eye for all 6 horses with a mean \pm standard deviation of $165.18 \text{ ng/ml} \pm 87.69 \text{ ng/ml}$. Morphine was also detected in vitreous humor of the treated eye of 5/6 horse with a mean \pm standard deviation of $4.87 \pm 4.46 \text{ ng/ml}$. Morphine was detected in the serum of 5/6 horses at varying time points. There was significant variability in serum morphine concentrations between horses. In general, topical morphine sulfate applied to the eye every four hours can be expected to result in systemic absorption, with peak systemic concentrations occurring approximately 5-10 minutes after administration. In addition, morphine concentrations were more consistently detected on day two and three, than day one of administration. Maximum systemic concentration reached in a single horse was 6.98 ng/ml .

The objective of the second study was to test the hypothesis that topical 1% morphine sulfate applied to the equine cornea will result in decreased corneal sensitivity compared to a control eye as measured by corneal aesthesiometer. Mean baseline corneal touch threshold of both control eye and treated eye was 21.8mm. Corneal touch threshold was not significantly different between morphine treated and control eyes at any time point. In conclusion, these studies determined 1% morphine to be safe for short term use on the

equine eye and showed that 1% morphine does not provide an anesthetic effect on the intact cornea. Further studies to evaluate a possible analgesic effect are warranted.

©Copyright by Emma Gordon

July 25, 2016

All Rights Reserved

Evaluation of Topical Application of 1% Morphine Sulfate Solution as an Analgesic on
the Healthy Equine Eye

by

Emma Gordon

A THESIS

Submitted to

Oregon State University

in partial fulfillment of

the requirements for the

Degree of

Master of Science

Presented July 25, 2016

Commencement June 2017

Master of Science thesis of Emma Gordon presented on July 25, 2016

APPROVED:

Major Professor, representing Veterinary Science

Dean of the College of Veterinary Medicine

Dean of the Graduate School

I understand that my thesis will become part of the permanent collection of Oregon State University libraries. My signature below authorizes release of my thesis to any reader upon request.

Emma Gordon, Author

ACKNOWLEDGEMENTS

I would like to thank Dr. John W. Schlipf Jr. for his mentorship throughout this project. I am grateful to him for providing the opportunity to pursue my love of ophthalmology through research, and to have been able to conduct research that I truly had an interest and enthusiasm for. Dr. Schlipf has an ability to tailor his degree of involvement to that regained by the student, and I appreciated being given the freedom to develop and conduct this project with help and guidance provided when asked for.

I am grateful to the other members of my graduate committee, including Dr. Keith Poulsen and Dr. Jerry Heidel for their time in attending meetings and guidance in conducting this project and writing the resultant thesis. Dr. Poulsen's input into this project development in the early stages was valuable and I was very appreciative of Dr. Heidel's time and expertise in reading histology slides.

Thank you also to Joseph McGuire for taking time to serve as my Graduate Council Representative.

In addition to my graduate committee, I am indebted to Nadette Stang for her help in bench-top techniques, data collection and interpretation, and ELISA trouble shooting. I am extremely appreciative of her willingness to stay late and go out of her way in order to help me – without her, this thesis would not have been completed. In addition to Nadette, Christy Sandquist was invaluable in data collection for the aesthesiometry project. Her organization and enthusiasm was very much appreciated. Thank you also to

the students (Class of 2015 and 2016) and OSU VTH veterinary technicians and House Officers who assisted in various ways.

Finally I would like to thank Dr. Christopher Cebra and Dr. Erica McKenzie. Dr. McKenzie for assistance with preparation of my abstract for conference presentation and for allowing me time away from clinics when I needed to be in the lab. Dr. Cebra for performing statistical analysis of my data, as well as providing funding through the Department of Clinical Sciences to present my data at conference.

To all those named, and anyone that I have forgotten: Thank you, I really appreciate it!!

Financial support was provided from internal funding by the College of Veterinary Medicine, Oregon State University.

TABLE OF CONTENTS

	<u>Page</u>
1. Introduction.....	1
2. Objectives and Hypotheses.....	2
3. Literature Review.....	3
3.1 The Equine Eye.....	3
3.1.1 The Importance of the Equine Eye.....	3
3.1.2 Anatomy of the Eye.....	4
3.1.3 Innervation of the Cornea.....	7
3.1.4 Physiology and Immunology of the Eye.....	8
3.2 Basic Physical Examination of the Horse.....	9
3.3 Equine Ocular Examination.....	10
3.3.1 Overview.....	10
3.3.2 Cranial Nerve Examination and Ocular Reflexes.....	12
3.3.3 Corneal Evaluation.....	15
3.3.4 Regional Anesthesia to Facilitate Examination.....	16
3.3.4.1 Perineural Anesthesia.....	16
3.3.4.2 Topical corneal anesthesia for Diagnostic Purposes.....	17
3.3.5 Schirmer Tear Test.....	20
3.3.6 Corneal Culture and Cytology.....	21
3.3.7 Anterior Segment Trans-illumination.....	21
3.3.8 Mydriatic Agents.....	22
3.3.9 Posterior Ophthalmoscopy.....	23

TABLE OF CONTENTS CONTINUED

	<u>Page</u>
3.3.10 Biomicroscopy.....	24
3.3.11 Tonometry.....	24
3.3.12 Aqueous Paracentesis.....	25
3.3.13 Vitreous Paracentesis.....	26
3.3.14 Ocular Ultrasonography.....	27
3.3.15 Electroretinography.....	28
3.3.16 Advanced Imaging Modalities.....	28
3.4 Common Painful Equine Ocular Conditions.....	29
3.4.1 Equine Ulcerative Keratitis/Keratomalacia.....	29
3.4.2 Equine Recurrent Uveitis.....	31
3.4.3 Immune Mediated Keratitis.....	33
3.4.4 Corneal Stromal Abscess.....	33
3.4.5 Calcific Keratopathy.....	34
3.4.6 Eosinophilic Keratitis.....	34
3.5 Current Analgesic Options for Equine Ocular Disease.....	35
3.5.1 Manifestations of Pain in Horses.....	35
3.5.2 Measurement of Corneal Sensitivity and Associated Factors.....	39
3.5.3 Systemic Medications for Pain Control of Ocular Disease.....	41
3.5.4 Review of Morphine and other Opioids in Equine Pain Control.....	45
3.5.5 Overview of Topical Ophthalmic Treatments for Pain Control.....	51

TABLE OF CONTENTS CONTINUED

	<u>Page</u>
4.0 Evaluation of Short-Term Topical 1% Morphine Sulfate Application on the Healthy Equine Eye.....	58
4.1 Introduction.....	58
4.2 Materials and Methods.....	61
4.2.1 Animals and Treatments.....	61
4.2.2 Ocular and Systemic Side Effects.....	65
4.2.3 Corneal Histology.....	66
4.2.4 Enzyme Linked Immunosorbent Assay (ELISA) Quantification of Ocular and Systemic Morphine Absorption.....	67
4.3 Statistical Analysis.....	71
4.4 Results.....	72
4.5 Excluded Study Participant.....	79
4.6 Discussion.....	81
5. Evaluation of Corneal Analgesia After Application of 1% Morphine Sulfate by use of Aesthesiometry in Normal Horses.....	90
5.1 Introduction.....	90
5.2 Materials and Methods.....	93
5.2.1 Animals and Treatments.....	93
5.2.2 Measurement of Corneal Sensitivity.....	94
5.2.3 Treatment (Morphine) and Control (LiquiTears) Application.....	95
5.3 Statistical Analysis.....	97

TABLE OF CONTENTS CONTINUED

	Page
5.4 Results.....	97
5.5 Discussion.....	102
6.0 Conclusions.....	109
References.....	112
Appendix 1: Footnotes.....	110

LIST OF FIGURES

<u>Figure</u>	<u>Page</u>
1. Basic anatomy of the equine eye.....	10
2. Aqueous Paracentesis.....	38
3.1 Morphine ELISA standard curve (kit).....	87
3.2 Morphine ELISA standard curve (aqueous).....	88
3.3 Morphine ELISA standard curve (vitreous).....	88
3.4 Morphine ELISA standard curves superimposed.....	89
4. Graph of Systemic Morphine Concentrations.....	93
5. Graph of systemic morphine absorption for horse one.....	94
6. Graph of systemic morphine absorption for horse three.....	94
7. Graph of systemic morphine absorption for horse four.....	95
8. Graph of Systemic Morphine Absorption for Horse Six.....	95
9. Graph of systemic morphine absorption for horse seven.....	96
10. Excluded study participant corneal histology.....	79
11. Corneal touch thresholds after treatment administration.....	111
12a. Graph of horse one showing change in CTT values from baseline.....	111
12b. Graph of horse three showing change in CTT values from baseline.....	112
12c. Graph of horse four showing change in CTT values from baseline.....	112
12d. Graph of horse five showing change in CTT values from baseline.....	113
12e. Graph of horse six showing change in CTT values from baseline.....	113
12f. Graph of horse seven showing change in CTT values from baseline.....	114
12g. Graph of horse eight showing change in CTT values from baseline.....	114

LIST OF TABLES

<u>Table</u>	<u>Page</u>
1. Cranial Nerve Examination.....	14
2. Study Participant Characteristics.....	62
3. Serum Collection Time Points Post Morphine Administration.....	65
4. Raw Data for Serum Morphine Concentrations.....	75
5. Aesthesiometer Pressure Conversion Table.....	94
6. Aesthesiometry Study Participant Characteristics.....	96

1. Introduction

Corneal ulcers are one of the most common eye conditions of the horse, with potentially serious complications such as loss of vision or the eye itself (Neaderland 1987, Stiles 2003, Robertson 2004, Gilger 2011). They are extremely painful due to the large number of sensory nerve endings found in the cornea (Brooks 2000, Stiles 2003, Robertson 2004, Gilger 2011). Horses with ocular pain are challenging to treat for both veterinarians and owners. Managing pain associated with corneal disease centers around systemic administration of analgesic agents such as NSAIDs and opioids (Robertson 2004, Thomson 2013). Unfortunately, horses frequently continue to show signs of ophthalmic pain despite systemic analgesics, which have side effects including renal and gastrointestinal toxicity, and CNS excitement (Robertson 2004, Devine 2013).

Developing new analgesic protocols represents an important advancement in equine ophthalmology. Morphine applied topically to the eye has been shown to have a rapid onset of action in rabbits, dogs, and humans and provides effective analgesia without deleterious side effects on corneal healing (Peyman 1994, Stiles 2003, Robertson 2004). Despite our knowledge of topical ophthalmic morphine in other species, there are no published reports for its use in horses.

2. Objectives and Hypothesis

Central Hypothesis: Topical application of morphine sulfate would present a viable analgesic option for the equine eye.

Aim 1: Test the hypothesis that short-term administration of topical 1% morphine sulfate does not detrimentally affect the corneal structure.

- a) Compare corneal histology in control corneas to corneas treated with morphine sulfate every four hours for 72 hours.

Aim 2: Test the hypothesis that topical 1% morphine applied to the equine cornea will result in ocular, but not systemic absorption.

- a) Determine serum concentrations of morphine following topical ocular application.
- b) Determine concentration of morphine in aqueous and vitreous humor after topical application.

Aim 3: Test the hypothesis that topical 1% morphine sulfate applied to the equine cornea will result in decreased corneal touch thresholds when compared to a control eye.

- a) Determine if topical 1% morphine sulfate will increase the corneal touch threshold compared to a control eye, as measured by Cochet-Bonnet aesthesiometer.
- b) Determine the duration of action of a single administration of morphine sulfate to the equine cornea.

3.1.1 The Uniqueness of the Equine Eye

As a prey species, the eye is an incredibly vital organ to the horse. Their eyes are positioned laterally in their skull to allow as wide a field of vision as possible, to give them ample opportunity to flee when necessary. However, this positioning and their flighty nature predisposes them to ocular injury. Docile domesticated horses can cope extremely well without one or both eyes including competition in athletic activities. High level competition horses, however, need two healthy eyes in order to perform their intended use such as jumping, which requires depth perception provided by the field of binocular vision possessed by horses. Other disciplines such as barrel racing also require bilateral vision. With this in mind, quality and timely veterinary assessment and treatment is absolutely vital for these animals and their owners.

3.1.2 Anatomy of the Eye

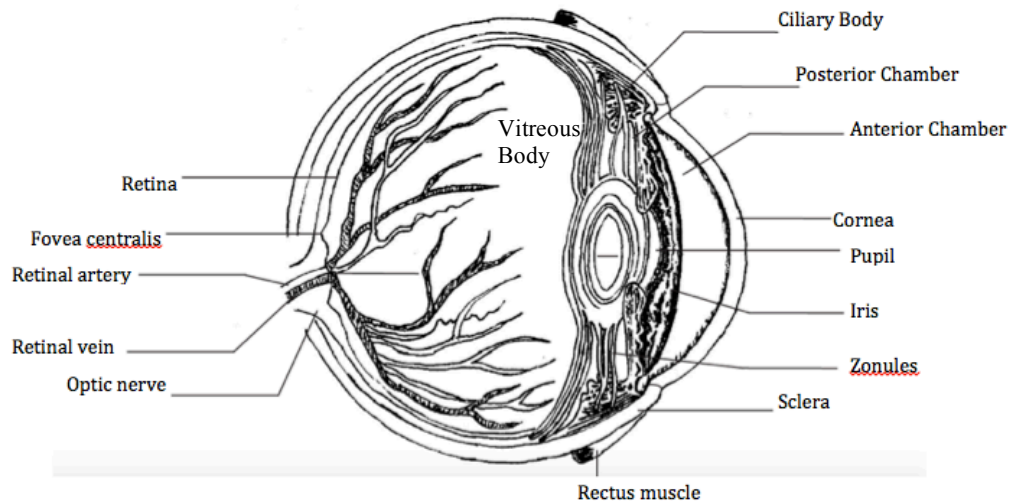


Figure 1. Diagram of the basic anatomy of the equine eye.
Artwork by Shannon Casserly.

A tough white fibrous layer called the sclera covers the outer most part of the caudal eyeball. The transparent conjunctiva covers the sclera in the front of the eye, which is continuous with conjunctiva on the underside of the eyelids. The cornea is a thin, transparent, curved structure at the front of the eye, which helps focus light onto the retina. See Figure 1. Light travels through the cornea, through the pupil formed by an opening in the iris and then through the lens (Barrett 2012). The degree of contraction or relaxation of the iris controls the amount of light that passes through to the back of the eye, similar to a diaphragm on a camera or microscope. The lens changes shape by way of contraction or relaxation of the ciliary muscle/body, which suspends the lens. The lens then helps direct the beam of light to a focal point on the retina. The retina lines the inside of the back of the eye and contains photoreceptor cells that detect light and

produce an action potential in the optic nerve when light hits the retina (Barrett 2012). These photoreceptor cells consist of rods and cones. Rods are more numerous and are responsible for vision at low levels of light. They do not provide color vision. Cones are responsible for fine central vision, as well as color vision. At the front of the eye, just in front of the lens, is the muscular iris, which gives color to the eye and functions to open and close the pupil. The iris is part of the uvea, the term for the iris, ciliary body and choroid. The primary function of the choroid is to provide blood supply for nutrition and gas exchange to various parts of the eye (Gilger 2011, Barrett 2012).

Grossly the eye can be divided into two chambers. The anterior chamber is at the front of the eye and is in the area created from the back of the cornea to the front surface of the lens. The anterior chamber contains aqueous humor, a clear, protein-free liquid that provides nourishment to the cornea and iris (Gilger 2011, Annear 2012). The ciliary body produces the aqueous humor by a combination of diffusion and active transport from plasma, which is then reabsorbed into venous channels at the junction between the iris and cornea. The vitreous chamber, at the back of the eye, is the larger of the two chambers and encompasses the space from the back of the lens to the retina and is filled with a gelatinous material called vitreous humor, also known as the vitreous body (Gilger 2011, Barrett 2012). Vitreous humor is produced by cells in the ciliary body and acts as a physical force holding the retina in place against the vascular choroid. Unlike the frequent turn-over of the aqueous humor, the vitreous humor does not get replaced. The vitreous is composed of type II collagen fibrils, hyaluronic acid and predominantly water (Gilger 2011).

The cornea itself is composed of 3 main layers-the superficial epithelium that is lipophilic, the central stroma, which is hydrophilic, and the endothelium which is lipophilic. The outermost epithelium is stratified and consists of 8-12 layers of non-keratinized squamous cells that are then anchored to a basement membrane by hemidesmosomes (Burstein 1985, Gilger 2011). The stroma makes up 90% of the corneal thickness and is primarily composed of water as well as collagen fibers and glycosaminoglycans (Gilger 2011, Brooks 2012, Henriksen 2013). Deep cornea has primarily chondroitin-4 sulfate whereas superficial cornea has primarily chondroitin-6 sulfate (Gilger 2011). A second basement membrane, also known as Descemet's membrane, lies deep to the stroma. Deep to Descemet's membrane is a single layer endothelium, an essential tissue layer that both forms a physical barrier between cornea and aqueous humor, but also is very active in pumping water and solutes out of the cornea (Gilger 2011, Henriksen 2013).

The average central corneal thickness is 0.6mm in the center and 1mm thick in the periphery (Gilger 2011). In Rocky Mountain horses, corneal thickness has been shown to increase with age but this is not the case in other breeds (Ramsey 1999). Corneal pachymetry performed in healthy adult horses has shown the thickness of the epithelium to be $174.7 \pm 12.6\mu\text{m}$, stroma to be $599.2 \pm 45.4\mu\text{m}$, Descemet's membrane to be $38.4 \pm 15.3\mu\text{m}$ and total corneal thickness to be $812 \pm 44.1\mu\text{m}$ (Pirie 2014).

The outer surface of the cornea is covered by the pre-corneal tear film, which has 3 distinct layers. These consist of the outer most lipid layer, secreted by the Meibomian glands and functions to provide a hydrophobic barrier to the tear film. The central layer is the aqueous layer produced by the lacrimal gland, which assists in tear film distribution across the cornea. The innermost layer is the mucous layer, produced by the goblet cells of the conjunctiva. This layer coats the cornea and provides a hydrophilic layer to assist with tear film distribution. Proper tear production is crucial to maintenance, protection and healing of the cornea (Burstein 1985, Brooks 2000, Brooks 2012).

3.1.3 Innervation of the Cornea

The cornea is the most highly innervated tissue in the mammalian body (Brooks 2000, Marfurt 2001, Lwigale 2007, Kalf 2008). The nerve density in the cornea is 300-600 times that in the skin (Rozsa 1982, Brooks 2000). The majority of corneal innervation is supplied by the ophthalmic branch of the trigeminal nerve (Kalf 2008, Gilger 2011). There are also long branches of the ciliary nerve that enter the corneal stroma at the limbus, progress through to the sub epithelial cell layer where they become entangled between cells to terminate as free bare filaments (Rozsa 1982, Brooks 2000, Henriksen 2013). These ciliary nerves contain both sympathetic and parasympathetic fibers and course with the oculomotor nerve. Studies of nerve organization in the rabbit cornea found that from the sub-epithelial plexus, axons penetrate the epithelium, forming terminals that either diverge or branch vertically or horizontally (Chan-Ling 1989, Barrett 1991). The vertical axons extend towards the outer cell layer. Horizontal axons develop into families of leashes with disorganized terminal branches and endings (Rozsa 1982,

Chan-Ling 1989, Marfurt 2001). Developmentally, corneal innervation is dependent on Lens-derived Semaphorin3A, which is expressed in the eye as a key factor in correct formation of the nerve ring and positioning of the ventral neural plexus in the choroid fissure during embryological development of the eye, and in particular, the cornea (Lwigale 2007).

3.1.4 Physiology and Immunology of the Eye

The normal cornea of all species is colonized by a bacterial micro flora composed predominantly of gram positive bacteria and fungi, with a lesser number of gram-negative organisms. The mean pH of the tear film in horses ranges 7.84 +/- 0.3 to 8.33 +/- 0.15. This is different than blood pH and different than the pH of commonly administered topical ophthalmic medications. This may explain why some medications appear to cause temporary pain when administered (Brooks 2012, Beckwith-Cohen 2014). In rats, pH of a solution appears to slow regeneration of the corneal epithelium when pH is 2.82, but not at a pH of 4.12 or 6.28 (Marr 1957). The pre-corneal tear film assists in transporting oxygen from the external environment to the cornea. The cornea gets a smaller proportion of its oxygen requirements from aqueous humor and limbal blood vessels. The majority of remaining nutrients, such as glucose is supplied by aqueous humor to the cornea. During times of increased metabolic demand within the cornea, glucose can be supplied from sub epithelial glycogen stores. This occurs in wound healing and can occur by both aerobic and anaerobic metabolism.

The immunology of the eye, and in particular the cornea, is unique. The eye is

considered an immunologically privileged site. This means the inflammatory immune response is down regulated in order to protect vulnerable structures in the eye (Gilger 2011). Unfortunately, the other side to this adaptation means ocular infections can be more difficult to control or resolve. The immunological privilege of the cornea is mainly due to endothelial cells, the almost complete absence of blood vessels and lymphatics. The cornea has extremely few antigen presenting cells such as dendritic cells or Langerhans cells. When sufficient inflammatory insult is present, the privileged status is lost and can result in significant ocular inflammation (Gilger 2011). The eye contains immunosuppressive factors within it, which inhibit the activity of immune-competent cells. These include TGF- β , and α -MSH. The retinal pigmented epithelium and the iris and ciliary body inhibit T cells and can also induce them to become T-Regulatory cells (Zhou 2010).

The normal vitreous is transparent and very uniform. During inflammation, the vitreous can develop a loss of this uniformity as debris, membranes and collagen fibrils accumulate in the fluid (Gilger 2011). The blood-retinal barrier is highly effective and prevents passage of cells and large molecules into and out of the eye (Caspi 2013). This blood-retinal barrier functions as a physical barrier to prevent passage of molecules. Lack of efferent lymphatics is also a contributor to this physical barrier (Zhou 2010).

3.2 Basic Physical Examination of the Horse

All live horses used in projects detailed in this thesis underwent a physical examination pre-inclusion to ensure they were healthy and fit to include in the study. The

physical examination starts from a distance, looking for any obvious swellings, abrasions or other abnormalities. Following this, vital signs are obtained. A normal temperature ranges from 99-100.8F, normal heart rate ranges from 28-40 beats per minute and normal respiratory rate ranges from 8-20 breaths per minute. Heart rhythm is evaluated for presence of murmurs or arrhythmias and breathing is evaluated for depth and effort. Pulse quality is assessed. The chest is auscultated for presence or absence of normal lung sounds and the trachea is listened to for abnormal sounds. The abdomen is auscultated for presence of normal gut sounds. Lymph nodes are palpated for abnormal size and limbs are palpated for heat, swelling or pain. Mucous membranes are inspected for color and moistness and capillary refill time should be less than two seconds. Eyes, nostrils and ears are inspected for discharge.

3.3 Equine Ocular Examination

3.3.1 Overview

When performing an ophthalmic examination in a horse, a systematic approach is important to avoid missing abnormalities. There are certain steps performed before others, since later tests will affect accuracy of results. Initial assessment of general eye appearance, lash angle, ocular comfort level, and reflexes (see 3.2.2) should be done prior to administration of sedation. Availability of a darkened room will significantly improve ease and accuracy of the examination.

The general order of steps in a routine equine eye examination, as recommended by Dr. Brian Gilger in Equine Ophthalmology, 2nd Edition (page 4) is:

1. Obtain medical and ocular history
2. Examine horse in its environment, including moving around freely
3. Evaluate for symmetry from the front of the head- globe, orbit, pupils, eyelash direction, ear and lip position
4. Perform vision testing- Menace response, dazzle reflex, maze testing
5. Perform palpebral and pupillary light reflexes
6. Perform Schirmer tear test if indicated
7. Administer sedation if needed
8. Perform palpebral nerve block
9. Use direct trans illumination for gross disease of eyelids, cornea, anterior chamber and iris
10. Collect samples for cytology and culture if indicated
11. Perform detailed examination of the eyelids, cornea, anterior chamber, and iris with trans illumination and biomicroscopy
12. Test corneal reflex
13. Apply topical fluorescein and examine the cornea
14. Apply topical anesthesia if indicated
15. Perform tonometry
16. Induce mydriasis (1% tropicamide)
17. Perform detailed examination of the lens and vitreous
18. Perform direct and/or indirect ophthalmoscopy

19. Irrigate nasolacrimal ducts if indicated

3.3.2 Cranial Nerve Evaluation and Ocular Reflexes

Testing ocular reflexes is a vital part of evaluating the health of an equine eye. Menace response: This is a response (not a reflex) that is typically learned by 14 days of age. The response is invoked with a hand movement towards the eye resulting in a blink of the eyelids or an aversion motion with the head or neck. It is important to avoid moving the hand so forcefully so as to move air onto the horses' face, or to get close enough to touch the hairs surrounding the eye. The hand motion should be performed twice, once in the nasal aspect and once on the temporal aspect of each eye. This is because the nerve fibers decussate at the optic chiasm, approximately 70-90% depending on literature source (Gilger 2011, Barrett 2012). The menace response assesses integrity and function of the retina, cranial nerve II and cranial nerve VII. An impaired menace can occur with a lesion in the retina, optic nerve and facial nerve. It is important to remember cerebellar disease can cause menace deficits without causing blindness. This is thought to occur because the neural pathway between the visual cortex and facial nucleus passes through the cerebellum, therefore cerebellar disease interrupts this efferent pathway of the menace response (Gilger 2011).

Pupillary light reflex (PLR): After evaluating both eyes for pupil size and pupil symmetry, PLR is tested. When light is shone into an eye, the pupil should vertically constrict rapidly, depending on light intensity. This is the direct pupillary light reflex. It assesses retina, optic nerve, mid-brain and the oculomotor nerve. Light directed into one

eye causes constriction of the pupil in the other eye. This is called the consensual response and it occurs due to the parasympathetic component of the oculomotor nerve in the pre-tectal region (Gilger 2011).

Dazzle reflex: The dazzle reflex assesses the light pathway and involves shining a bright light into each eye in turn and looking for a blink response. This can be useful in horses with anterior disease such as cataracts or miosis secondary to inflammation. These horses may not see objects sufficiently to have a menace response present, but should have a positive dazzle reflex as long as the remainder of the pathway is intact. The dazzle reflex assesses retina, optic and facial nerve, rostral colliculus, supra-optic nuclei and orbicularis oculi. In contrast, the menace is cortically mediated.

Palpebral reflex: This reflex is tested by touching the nasal and temporal canthus of the eye. A positive result occurs when the eye blinks at this stimulus. This tests trigeminal and facial nerves (Gilger 2011).

Corneal reflex: This reflex is elicited by touching the cornea directly. A positive response results in closure of the eyelid and retraction of the globe. This tests afferent trigeminal and efferent facial and abducens nerves (Gilger 2011). This test is most commonly performed post euthanasia as it is the final reflex to be lost. Touching the cornea directly in a live patient should be avoided if possible, due to risk of corneal damage.

Other cranial nerves that should be evaluated as part of an ophthalmic exam are listed in

Table One.

Cranial Nerve	Name	Motor or sensory	Function	Dysfunction	Assessment
II	Optic	Sensory	Vision Light pathway	Blindness	Menace PLR, Dazzle
III	Oculomotor	Motor -Rectus muscles -Pupil sphincter -Levator superioris	Globe movement Eyelid elevation	Lateral strabismus	Eye position
IV	Trochlear	Motor to superior oblique	Globe movement	Dorsomedial strabismus	Move head, watch eyes
V	Trigeminal	Sensory -Skin of face and eyelid -Ophthalmic branch, cornea	Sensation of skin, eyelids, cornea	Neurotrophic keratitis	Corneal reflex
VI	Abducens	Motor, Lateral rectus	Globe movement	Medial strabismus	Move head, observe eyes
VII	Facial	Motor -Orbicularis oculi -Lacrimal gland	Eyelid closure Tear production	Exposure keratitis. Dry eye	Palpebral reflex Schirmer tear test
VIII	Vestibulocochlear	-	Equilibrium	Spontaneous nystagmus	Observation

Table 1. Cranial nerve evaluation as part of an ophthalmic examination. Table adapted from Equine Ophthalmology by Brian C. Gilger, 2nd Edition, Page 6.

3.3.3 Corneal Evaluation

The cornea should be evaluated for any evidence of gross abnormalities such as ulceration, edema or presence of opacities. This can be done using either trans-illumination or by use of slit-lamp biomicroscopy. Following Schirmer tear test, and collection of corneal culture, the cornea is stained. Fluorescein staining is typically done first, by using a Fluoret strip containing sodium fluorescein. This stain is vital in evaluating the health of the cornea, conjunctiva and evaluating patency of the naso-lacrimal system. Sodium fluorescein is hydrophilic and will bind to exposed corneal stroma, but will not bind to lipophilic epithelium or Descemet's membrane. Fluorescein staining is an integral part of the ocular examination and should be done during each and every eye exam. It comes in an impregnated strip that can be diluted in eyewash and squirted onto the eye, or painted directly onto the cornea when a stronger solution is required for subtle lesions. Once applied to the cornea, cobalt blue light is used to evaluate positive identification of a corneal epithelial defect that will glow green. Fluorescein is used in the Seidel test to evaluate for leakage of aqueous humor through a full thickness defect in the cornea that may be very small and hard to identify (Gilger 2011).

Rose Bengal, another stain commonly used in assessing the integrity of the cornea, although less commonly than fluorescein. The paper strips contain dichlorotetaiodo fluorescein and are useful in evaluating disorders of the pre-corneal tear film, mucin deficiencies and superficial corneal epithelial abnormalities. It stains dead or damaged

cells and mucus. Rose Bengal is especially useful in evaluating painful eyes where a viral or fungal keratitis is suspected despite a negative fluorescein test.

3.3.4 Regional Anesthesia to Facilitate Examination

3.3.4.1 Perineural Anesthesia

Some horses will allow a full ophthalmic examination to be performed without sedation or perineural anesthesia, however these are a minority. Sedation provides some analgesia, which aids in evaluating a painful eye. The most commonly used drugs for this purpose are α_2 -agonists such as xylazine, detomidine, romifidine, with or without the opioid butorphanol. In addition to sedation, regional nerve blocks can make an equine ophthalmic examination much easier. The most commonly blocked nerve is the auriculopalpebral nerve (palpebral branch of the facial nerve). This nerve innervates the circular orbicularis oculi muscle and controls motor function to the eyelids. Injection of local anesthetic will block the action of this muscle, allowing the lid to be easily opened for ocular examination. The auriculopalpebral nerve branches initially from the main section of the facial nerve, and can be blocked in one of three places. The most dorsal location is the highest point of the zygomatic arch, near the base of the ear, followed by caudal to the caudal ramus of the mandible, and finally where it lies on the zygomatic arch caudal to the bony process of the frontal bone (Gilger 2011). Typically 1-2ml of lidocaine or mepivacaine is used, injected through a 25-gauge needle. These work by blocking sodium channels and preventing nerve impulse transmission by preventing depolarization. Lidocaine has an onset of 4-6 minutes and duration of action of 60-90 minutes. Mepivacaine (Carbocaine) has time of onset of 3-5 minutes and duration of

90-120 minutes. This nerve is entirely motor in function and blocking it provides no analgesia (Gilger 2011).

Sensory innervation to the eyelids of a horse is provided by the ophthalmic and maxillary branches of the trigeminal nerve. The ophthalmic branch then further branches into the frontal, lacrimal and infratrochlear nerves. The maxillary branch of the trigeminal branches into the zygomatic nerve. The frontal nerve, which is more commonly referred to as the supraorbital nerve, provides sensation to the nasal two thirds of the upper eyelid. The temporal aspect of the upper lid is innervated by the lacrimal nerve.

The infra-trochlear nerve supplies sensation to the nasal canthus. The temporal lower lid is innervated by the zygomatic nerve, which is sensory (Gilger 2011). The supraorbital nerve can be blocked as it exits the supraorbital foramen within the frontal bone. The lacrimal nerve can be blocked in a depression adjacent to the lacrimal notch in the dorsolateral orbital rim. The zygomatic nerve can be blocked by performing a line block along the ventral orbital rim. The infra-trochlear nerve can be blocked by a notch on the medial aspect on the dorsal orbital rim (Gilger 2011).

3.3.4.2 Topical Corneal Anesthesia for Diagnostic Purposes

As the cornea is exquisitely innervated, topical corneal anesthesia is essential to completing an ophthalmic exam (Kalf 2008). It is especially necessary for diagnostics such as corneal scrapings for cytology. The most commonly used topical anesthetic is 0.5% proparacaine hydrochloride, which blocks sodium channels. It requires

refrigeration, otherwise it loses potency (Kalf 2008, Pucket 2013). Tetracaine is more commonly used in companion animals, but has the disadvantages of being more likely to cause pain on initial application as well as conjunctival irritation and swelling. There is species variation in duration of anesthesia obtained with proparacaine, but in horses it has a maximum effect at 5 minutes and lasts for 25 minutes. In this study by Kalf et al., corneal touch thresholds as assessed by use of the Cochet-Bonnett aesthesiometer, did not drop to the lowest value possible on the aesthesiometer, suggesting that even at time of maximum proparacaine effectiveness, it did not block all sensation (Kalf 2008). This is in contrast to normal cats where corneal touch threshold was found to reach the lowest possible value at 15 minutes after administration (Binder 2006). Duration and depth of corneal anesthesia appears to be most profound when more proparacaine is administered i.e. when two drops are given instead of one (Binder 2006, Kalf 2008). Similarly, in dogs, maximal effect lasted 15 minutes when one drop was administered and 25 minutes when two drops were administered (Herring 2005).

Advantages of using lidocaine, bupivacaine or mepivacaine are they are less expensive than proparacaine and do not require refrigeration. In one comparative study in clinically healthy horses (Pucket 2013) proparacaine and mepivacaine decreased corneal sensitivity for 35 minutes, lidocaine for 45 minutes and bupivacaine for 60 minutes. Maximum analgesia (lowest corneal touch threshold) was achieved with bupivacaine and proparacaine and least with mepivacaine. For all evaluated drugs, onset of analgesia was evident at one minute and at maximal effect by 5 minutes. No grossly evident side-effects were reported after use of local anesthetics topically on the cornea, however no

microscopic examination of corneal epithelial cells was performed at the conclusion of this study (Pucket 2013).

Another study (Sharrow-Reabe 2012) compared use of topical 0.5% proparacaine and 0.5% aqueous tetracaine in healthy horses. It also looked at use of viscous 0.5% tetracaine. Overall maximum anesthetic duration was 20 minutes with proparacaine and aqueous tetracaine and 30 minutes with viscous tetracaine. Viscous tetracaine also caused the greatest decrease in corneal touch threshold. No side effects were noted from this study. The viscous tetracaine was more difficult to apply however, as it difficult to administer topically through a syringe hub (Sharrow-Reabe 2012).

Other studies evaluating topical use of anesthetics have found evidence of side effects, making these medications only suitable for intermittent diagnostic use and not for frequent clinical analgesic purposes (Marr 1957, Carney 1984, Ramselaar 1988, McGee 2007). The most common site of toxicity is the surface of the cornea and includes pain on application, which appears to be least with proparacaine (McGee 2007). Punctate corneal erosions can also be seen after administration. Monclin et al. found no ocular side effects after administration of tetracaine in healthy horses (Monclin 2011). In humans, long term repeated use of corneal anesthetics has caused stromal keratitis, granularity, delayed epithelial healing and infiltration. Single use treatments however appear to be of minimal concern (Kramer 1980).

Toxicity can occur with excessive administration of local anesthetics from systemic

absorption although this is uncommon in the horse. Systemic toxicity includes signs of nervous and cardiovascular involvement such as muscle twitching or tremors, ataxia, stumbling, falling, seizures, vasodilation, reduced cardiac contractility, brady arrhythmias, and cardiovascular collapse. This is extremely rare in adult horses as a significant volume of the local anesthetic must be administered to reach this toxicity threshold, however if the drug is inadvertently administered into a vessel then much lower volumes can cause systemic side effects (Labelle 2013).

3.3.5 Schirmer Tear Test

The Schirmer tear test is used to measure aqueous tear production. The test involves placing a special strip of filter paper into the conjunctival sac by the nasal canthus. The strip has millimeter increments marked on it. Distance of wetting in mm over 60 seconds is measured. The most common method is performed without topical anesthesia on the cornea as this measures a combination of basal and reflex tearing. This is called Schirmer I test (Brooks 2000, Gilger 2011). The Schirmer II test is performed identically, following application of topical anesthetic such as proparacaine. The Schirmer II test measures only basal secretion and not reflex tearing and is not commonly performed in clinical diagnostics. Abnormal Schirmer tear test results are uncommon in horses compared to dogs and therefore this procedure is often not routinely performed. A Schirmer test is especially indicated however, when there is dysfunction of the facial nerve such as with trauma or facial paralysis. Normal horses have been reported to have a Schirmer I test result ranging from 11 to >30mm per minute. Systemically sick horses commonly have lower values (Gilger 2011).

3.3.6 Corneal Culture and Cytology

Corneal culture and cytology are essential in managing cases of suspected infectious keratitis. Samples for culture can be obtained by touching the corneal surface with a moistened culturette swab. Samples should be obtained from the ulcer edges. It is important that specimens for culture are obtained early in the exam, and before topical anesthetics or fluorescein are applied as these interfere with or inhibit bacterial growth. Aerobic and fungal culture should be routinely performed and anaerobic culture may be indicated in some cases (Gilger 2011).

Cytology is a valuable tool in identifying the type of inflammation in a diseased cornea. Cytology can differentiate bacterial from fungal etiologies, complicated compared to non-complicated ulcers, as well as identify neoplasia and aid in initial therapy selection. Sample collection is performed following application of topical anesthetic to the cornea. The blunt handle end of a scalpel blade is used to lift cells from the affected area and transferred to a microscope slide in a thin layer. Slides are best evaluated by a trained cytologist (Gilger 2011).

3.3.7 Anterior Segment Trans-Illumination

Following evaluation of the cornea is assessment of the anterior chamber and iris. The anterior chamber is best assessed using a thin beam of light such that is provided by a slit lamp. This beam is directed onto the cornea at a 45-degree angle. In a normal, non-inflamed eye, this will produce a clear beam. In an inflamed eye with presence of inflammatory debris such as protein and cells, these particles will show up as a hazy

“headlights in fog” appearance. This is the Tyndall effect, more commonly known as presence of aqueous flare (Gilger 2011). The slit lamp can also aid in assessing volume of the anterior chamber. In addition, the iris should be evaluated for color changes, presence of synechiae, masses, atrophy of iridic granules and normality of the filtration angle.

3.3.8 Mydriatic Agents

In order to perform a thorough ocular exam, the pupil must be dilated (mydriasis) to allow complete visualization of the fundus. The fundic region consists of the retina and optic disc as well as retinal pigmented epithelium. Mydriasis needs to be performed after reflexes have been evaluated, as these drugs will affect menace response, dazzle reflex, resting pupil size and pupillary light reflex. Tonometry should ideally also be performed before mydriasis (Gilger 2011). There are several drugs that can be used to dilate the eye. One percent tropicamide (Mydriacyl) solution is the most commonly used for diagnostic evaluation. This is a short acting mydriatic with onset of action of 10-20 minutes and duration of action of 4-6 hours (Gilger 2011). Tropicamide works by means of anticholinergic action causing both dilation and cycloplegia.

Topical 1% atropine solution is a potent mydriatic agent however it is best reserved for treatment of ocular conditions requiring mydriasis rather than for ocular examination. One administration of topical atropine can cause dilation of the pupil for up to 14 days duration (Gilger 2011). In addition, potential systemic side effects can include slowing gastrointestinal motility although the risk of this after one administration is extremely minimal (Williams 2000, Gilger 2011). Use of atropine can also be a concern when

glaucoma is present as dilation of the iris can interfere with the drainage angle for aqueous humor.

Ten percent phenylephrine hydrochloride solution can be used as an adjunct to atropine in clinically miotic cases. It is a α -agonist, but typically does not cause significant dilation in normal eyes, therefore is not used for routine ophthalmic exams. In addition, 1% phenylephrine can be used to aid in localization of Horner's syndrome lesions. As a sympathomimetic, both phenylephrine and epinephrine will cause rapid pupil dilation in post-ganglionic lesions due to denervation hypersensitivity of the involved cells (Gilger 2011).

3.3.9 Posterior Ophthalmoscopy

Posterior ophthalmoscopy refers to detailed examination of the posterior segment of the eye. Initially, trans-illumination is performed using a Finoff trans-illuminator to grossly examine the posterior aspects of the eye. This is only sufficient for an initial screen for abnormalities. Following this, either direct or indirect ophthalmoscopy is performed. Direct ophthalmoscopy is performed by using an ophthalmoscope. Direct ophthalmoscopy produces an upright image and high magnification, although the area of fundus that is visible at one time is small. Indirect ophthalmoscopy is performed using a light source such as the Finoff trans-illuminator as well as a specialized hand-held lens. The indirect ophthalmoscope allows a wider field of view, better assessment of peripheral structures, however the image becomes inverted (Gilger 2011). Posterior segment examination should include assessment of the vitreous, tapetal and non-tapetal fundus,

retina, retinal blood vessels, and optic nerve. The lens should also be examined for presence of abnormalities such as cataract formation (Gilger 2011). As previously discussed, posterior ophthalmoscopy can be performed without mydriasis, but a complete and thorough examination requires mydriasis. The study protocols described in this thesis did not include pupil dilation during routine eye examination, as there was concern that the medications may interfere with results such as intraocular pressure measurement and Schirmer Tear Test values.

3.3.10 Biomicroscopy

Biomicroscopy involves viewing various structures of the eye under magnification. It is performed using a slit-lamp binocular microscope that has a pivoting light source. The advantage of using this specialized and expensive equipment is significantly improved visualization and localization of the cornea, anterior chamber, and lens as well as the anterior portion of the vitreous humor. The slit-lamp can also be used to assess the thickness of the cornea, measure the depth of the anterior chamber, and is a vital tool for assessing the presence or absence of aqueous flare.

3.3.11 Tonometry

Tonometry refers to the measurement of intraocular pressures and is performed indirectly in clinical cases by measurement of corneal tension. The most commonly used devices are the TonoPen and TonoVet. For the study described in this thesis, the TonoVet was used and will be described here. A significant advantage of the TonoVet over the TonoPen is the ability to obtain readings without the use of topical corneal anesthesia.

Tonometry should ideally be performed in the non-sedated patient as sedation can significantly decreased intraocular pressure (IOP) readings. Xylazine at 0.3mg/kg has been shown to result in a 23% decrease in intra-ocular pressure. Increasing the xylazine dose to 1mg/kg resulted in a decrease in intra-ocular pressure of 27% suggesting there is not a linear dose-response relationship (Robertson 2004). The auriculopalpebral nerve is commonly blocked to allow the upper eyelid to be held open by the operator. The TonoVet is held in the center of the cornea, 5mm distance from the cornea, and horizontal to the ground. Then the button is pressed, a small round tipped filament exits the device and taps the cornea, taking a pressure measurement. Three separate readings are obtained for each eye with standard error less than 5%. This standard error is measured by the instrument and reported with each numerical value reading. Normal values in horses have been reported to range from 24.5 +/- 4mmHg to 28.6 +/- 4.8mmHg. Head position can also influence readings and should be kept consistent throughout multiple day readings (Komaromy 2006, Gilger 2011).

3.3.12 Aqueous Paracentesis

Aqueous paracentesis involves withdrawing a sample of aqueous fluid from the anterior chamber of the eye. Aqueous paracentesis is a procedure that is rarely performed, but can be extremely useful when utilized correctly. It can be performed to obtain a fluid sample for cytology, culture or leptospirosis titer testing (Gilger 2011). The same technique can be used to inject therapeutics such as antibiotics or tissue plasminogen activator (TPA) in an acutely uveitic eye with fibrin formation. The procedure is perhaps

most safely performed with the horse under general anesthesia but it can be done with the horse standing and sedated and with appropriate local anesthesia and is most commonly performed in the dorsotemporal limbus. Dilute betadine solution is used to clean the injection site. Thumb forceps are used to grasp the bulbar conjunctiva near the site of needle insertion to steady the eye position. A 27-gauge needle is directed through the limbal cornea at a 45-degree angle to allow the needle to tunnel through sclera for several millimeters before entering the chamber at an angle parallel to the iris as shown in Figure 2. A volume of 0.2-0.5ml of aqueous humor can be aspirated (Gilger 2011). Possible complications include hyphema; lens capsule rupture, endophthalmitis and secondary corneal edema, anterior uveitis and edema or hemorrhage of the choroid (Gilger 2011).

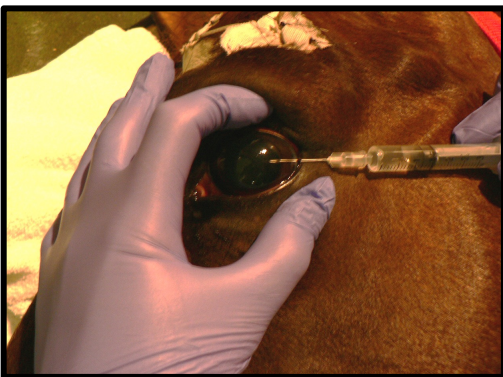


Figure 2. Aqueous paracentesis post-euthanasia. Note the bevel of the needle is facing up, and the angle of the needle is placed so as to avoid lacerating the iris or the cornea. The free hand stabilizes the eye.

3.3.13 Vitreous Paracentesis

Vitreous paracentesis is the process of removing a sample of the vitreous humor for analysis. This is typically performed with the horse under general anesthesia or post-euthanasia but may be done standing. A 23-25gauge needle is inserted 1cm from the

dorsal or dorsotemporal limbus to avoid the retina. The needle is directed towards the approximate location of the optic disc to avoid contacting or puncturing the lens. Potential complications include hemorrhage, detachment of the retina and subsequent vision impairment or endophthalmitis (Gilger 2011). Obtained vitreous humor can be used for culture, cytology or antibody titers. The same technique can be used to instill medications such as antibiotics or gentamicin for ciliary body ablation when medically necessary such as when treating an end-stage eye with severe Equine Recurrent Uveitis. In this situation, a volume of vitreous humor is withdrawn prior to injection so as not to cause pain by increased pressure post injection.

Ocular fluids can also be used for toxicology diagnostics after death. This can include nitrate poisoning, hypomagnesaemia, calcium status, salt poisoning, renal disease (creatinine levels). While these toxicology tests are more likely to be of use in cattle, there is also potential for use in horses (Childers 1995).

3.3.14 Ocular Ultrasonography

Ocular ultrasonography is a rapid and excellent method of evaluating both intraocular and retro bulbar structures in an awake horse. High frequency ultrasound examination and ultrasound biomicroscopy can provide exquisitely detailed images but is only available in limited specialty referral hospitals (Gilger 2011). Ultrasound is especially useful when peri-orbital swelling is such that it does not permit ophthalmic examination or when severe miosis is present, in order to evaluate the posterior ocular structures. One of the more common uses is to evaluate for presence or absence of retinal

detachment (Gilger 2011). Ocular ultrasonography can be easily performed in general practice using a 5-13mHz equine tendon (linear) probe on a well-sedated horse. Sterile lubricant can be used on the upper eyelid as coupling gel. Trans corneal ultrasonography is possible following corneal anesthesia with proparacaine hydrochloride (Gilger 2011).

3.3.15 Electroretinography

This is an advanced diagnostic technique that can be utilized in specialist referral hospitals. Electroretinography (ERG) evaluates retinal function by recording electrical response when the retina is stimulated by light. The output of the test is in the form of an electroretinogram. It does not measure actual vision, but measures the functional capability of the retina and retinal-pigmented epithelium to detect light and generate an impulse. An ERG is indicated in cases where retinal dysfunction is suspected such as equine recurrent uveitis, lens or corneal opacities such that the fundus is unable to be visually examined. Electroretinographies can be used in diagnosing congenital stationary night blindness as well as retinal detachment. Three electrodes are placed for recording the ERG, a positive corneal electrode, negative electrode and a ground electrode. The most accurate reading can be obtained with the horse under general anesthesia but it can be performed in an adequately sedated standing horse. Electroretinography is not part of a routine ophthalmic exam (Gilger 2011).

3.3.16 Advanced Diagnostic Modalities

Ultrasonic Pachymetry: This is an advanced and rarely utilized clinical technique that measures corneal thickness in the live horse. Pachymetry measures the time taken for the ultrasound wave to traverse a normal cornea. By using this technique, the dorsal and

ventral cornea is generally found to be thicker than the central cornea (Gilger 2011).

Specular Microscopy: This technique can be used to evaluate the endothelial layer of the cornea as well as the lens. It uses differential focusing to focus on the corneal epithelial and endothelial cell surfaces at a 45-degree angle. Endothelial layer dysfunction plays a key role in the loss of function in some horses eyes secondary to chronic inflammation. When the number of endothelial cells drops below a critical number (which is as yet unidentified in horses), edema develops due to impaired pumping of water from the cornea due to the decreased number of endothelial cells (Gilger 2011).

Fluorescein Angiography: This extremely rarely utilized technique involves recording of fluorescein dye as it passes through retinal and choroidal circulation after being administered intravenously. Angiography can be utilized to evaluate for presence of lesions in the vascular wall of retinal vessels or tight junctions between retinal-pigmented epithelial cells (Gilger 2011).

3.4 Common Painful Equine Ocular Conditions

3.4.1 Equine Ulcerative Keratitis/Keratomalacia

Corneal disease is a very common reason for horses to be evaluated by veterinarians (Neaderland 1987, Gilger 2011). Of the conditions that affect the cornea, the most common is a corneal ulcer, also known as ulcerative keratitis (Gilger 2012). As previously mentioned, horses are particularly prone to corneal ulcers due to the lateral

positioning of their eye and their flighty nature. As the cornea is extremely densely innervated, especially in the superficial layers, horses with corneal ulcers are in significant pain. Horses with ulcers can also get a secondary uveitis as well, adding to their discomfort (Gilger 2011). Ulceration most often occurs secondary to trauma encountered in the horse's environment. Uncomplicated superficial ulcers will usually heal within a week. Re-epithelialization occurs at a rate of 0.6mm/day in horses (Gilger 2011). Non-healing ulcers, also known as indolent ulcers, are also common in horses and are idiopathic. They can take anywhere from 17 to 52 days to heal and the horse is in fairly significant discomfort while they heal (Gilger 2011).

Superficial corneal ulcers can also become infected with bacteria or fungi, complicating treatment and healing. Anterior uveitis tends to be much more severe in these cases, and much harder to control. The corneal epithelium with its resident micro flora is usually an effective barrier to infection, but this barrier is lost when superficial ulceration is present, predisposing to bacterial and fungal infections (Gilger 2011).

In some cases of severe ulceration, excessive proteolytic activity from white blood cells or bacteria can result in "melting" of the corneal stroma (keratomalacia). The two main proteases responsible are matrix metalloproteinases (MMP's) and the serine proteases (especially neutrophil elastase). Neutrophil elastase digests collagen, laminin and fibronectin. This is a very painful process that can rapidly result in loss of the eye (Gilger 2011). Neonatal foals are also prone to potentially vision-threatening lesions including ulcerative keratitis, non-ulcerative keratitis, uveitis, and entropion. Entropion

commonly occurs secondary to dehydration and can be extremely painful (Labelle 2011).

3.4.2 Equine Recurrent Uveitis

Equine recurrent uveitis (ERU) is a common and devastating disease for equids in North America. It is also known as moon blindness, iridocyclitis, and periodic ophthalmia (Gilger 2011). The disease is an immune-mediated syndrome and is the most common cause of equine blindness. The typical clinical course of ERU is recurring episodes of eye inflammation interspersed by periods of remission. Equine recurrent uveitis develops after an initial episode of uveitis (inflammation of the eye). The underlying cause is not identified in many cases although a strong connection between ERU and leptospirosis has been made. Other inciting causes can include other bacterial infections, viral, protozoal and parasitic disease as well as non-infectious causes such as trauma. There appears to be a genetic component to susceptibility (Gilger 2011).

Uveitis results in congestion in the eye, leading to episcleral injection, congestion and inflammation, which together cause leakage of protein and fluid into surrounding connective tissues as well as protein and inflammatory cells into aqueous and vitreous chambers. Due to this, there is dysfunction of the cornea, sclera, lens, retina and optic nerve. The corneal endothelial Na^+/K^+ ATPase that is responsible for dehydrating the cornea becomes disrupted and corneal stromal edema develops. This may or may not be reversible. Equine recurrent uveitis can lead to cataract formation, synechia formation, lens luxation, glaucoma, retinal detachment and blindness (Gilger 2011). Glaucoma can be a serious complication of anterior uveitis leading to significant pain as well as possible

loss of vision (Annear 2012). Glaucoma can develop slowly and go undetected until it is fairly advanced. The most common underlying condition that leads to glaucoma is equine recurrent uveitis. This occurs when inflammatory cells and mediators that are released during the inflammatory episodes alter the structure of the anterior chamber and drainage pathways for the aqueous fluid. This leads to a build up of aqueous fluid and an increase in intra-ocular pressure. Glaucoma is an extremely painful disease that can be very difficult to treat (Annear 2012).

Horses can also experience primary uveitis, which is separate entity to equine recurrent uveitis. All horses that have a single bout of uveitis are considered at risk for developing ERU syndrome for the next months to years. It is only diagnosed after two or more episodes of uveitis. Unlike primary uveitis, ERU is considered an autoimmune, T cell mediated disease. Clinical signs during an acute inflammatory episode of uveitis, whether due to primary uveitis or equine recurrent uveitis, consist of pain, tearing, squinting, corneal edema, aqueous flare +/- hypopyon (purulent debris) or hyphema (hemorrhage) in the anterior chamber. Some horses will develop white spots in their corneal endothelium. The pupil is typically tightly constricted (miotic) due to inflammation (Gilger 2011).

Neonatal foals are also prone to developing uveitis. Foals with sepsis are significantly more likely to have uveitis than foals without sepsis and these foals were also less likely to survive (Labelle 2011).

As episodes recur, more chronic changes develop. Some horses are affected in only one eye while others in both eyes. Appaloosas are over represented with the majority being affected bilaterally (Gilger 2011, Annear 2012). Regardless of the underlying cause or type of equine uveitis it is uniformly a difficult disease to resolve quickly and can be extremely painful. Currently available pain medications are often inadequate for controlling pain, (See 3.4) necessitating research into and development of alternatives for analgesia.

3.4.3 Immune Mediated Keratitis

Immune mediated keratitis is a recurring keratitis that is non-ulcerative and is uncommon. Clinical signs typically include neovascularization of the cornea, infiltrate of the cornea along with corneal edema (Pate 2012). It is most common in just one eye, but both eyes can be affected. Unlike ulcerative keratitis, immune mediated keratitis does not usually have accompanying intra-ocular inflammation. Immune-mediated keratitis can affect varying depths of the cornea and may be restricted to superficial layers or can extend all the way through stroma and include the endothelial layer. The inflammation is mediated by a combination of T cells and antibodies (Pate 2012). Although not commonly as painful as ulcerative keratitis, this condition can be quite painful.

3.4.4 Corneal Stromal Abscesses

Corneal stromal abscesses are an accumulation of cellular debris, necrotic tissue, white blood cells and potentially an infectious agent within the corneal stromal layer. The infectious agent can be bacterial but more and more commonly is being diagnosed as a

fungal infection (Henriksen 2013). They are thought to occur after a micropuncture in the corneal allows the infectious agent to enter the corneal stroma. As the abscess forms, there is a severe accompanying uveitis that develops and is extremely painful. Some stromal abscesses can be managed medically, but others require surgical intervention (Henriksen 2013).

3.3.5 Calcific Band Keratopathy

Calcific band keratopathy is a complication of chronic uveitis in horses. It occurs when calcium is deposited in a dystrophic fashion in the superficial corneal epithelium and sometimes also the corneal stroma. It affects approximately 6% of horses with chronic equine recurrent uveitis (Brooks 2012). Calcium ions are important in the normal eye but as in blood, levels in ocular fluids are closely regulated. When calcium levels are disturbed, calcium precipitation of the cornea, conjunctiva or sclera can occur. Calcium deposition into the cornea can occur secondary to chronic inflammation such as with equine recurrent uveitis, or can occur with a primary dystrophic condition. Development of corneal calcification is also a known side effect of long-term topical steroid therapy (Brooks 2012). Thicker deposits of calcium can result in elevation of the corneal surface, which causes erosions and ulcers in the corneal epithelium that will take up fluorescein stain and cause pain and secondary inflammation (Brooks 2012).

3.4.6 Eosinophilic Keratitis

Eosinophilic keratitis is an uncommon condition in horses that can be very painful. It is often bilateral and typically affects younger horses (Gilger 2011). Lesions are present

on the cornea as white plaques and may overlie superficial corneal ulcers. The pathogenesis remains unknown but is suspected to include initiation by environmental irritants or allergens, fomites or organisms. Treatment primarily involves corticosteroids and analgesics (Gilger 2011).

3.5 Current Analgesia Options for Equine Ocular Disease

3.5.1 Manifestations of Pain in Horses

Pain has been described in many texts as an unpleasant sensory and emotional experience associated with actual or potential tissue damage ((Muir 2010, Williams 2010, Gleerup 2016). Noxious stimuli are transduced to electrical impulses when they are received by pain receptors or nociceptors. These action potentials are then transmitted from the peripheral site of injury to the spinal cord by sensory nerve fibers (Muir 2010). This causes both a withdrawal response as well as being transmitted to the brain where an emotional response can occur. As a prey species, horses do not always show overt signs of pain, however with advances in science, recognition and management of pain is steadily improving (Gleerup 2016). The quality of pain management provided depends largely on the quality of pain evaluation (Sanchez 2014, Gleerup 2016). Reducing pain as much as possible improves animal welfare and can speed recovery times as well as improving associated factors such as appetite and body condition score (Gleerup 2016).

Painful stimuli applied to abdominal or extra-abdominal organs can also activate sympathetic inhibitory reflexes resulting in ileus (Wong 2011), which can lead to

secondary complications such as cecal impactions. Persistent pain has been shown to be able to modify the physiology and anatomy of the nervous system (Muir 2010). One of the challenges in accurately assessing pain is its subjectivity; therefore use of equine adapted pain scales is extremely valuable. Clinician and owner knowledge of pain-associated behavior is also important. Clinicians can also use physiologic parameters in assessing pain, such as heart rate however these tend to be inaccurate and not pain specific (Gleerup 2016). A normal horse, when observed in its stall environment, will usually be observed eating hay, drinking, sleeping either standing or lying, and is interested in its surroundings. Horses will usually be in the front part of their stall to observe or interact with people or horses (Gleerup 2016).

The sensation of pain is protective and can lead to a fight or flight response with more acute, severe pain, or a more quiet response with sub acute pain as a protective mechanism. Common pain behaviors associated with general pain include restlessness, dullness, decreased physical activity, decreased appetite, decreased socialization and interaction with people or other horses. Horses will stand with their head lowered below the withers and will not be resting or eating as a non-painful horse would usually be seen to do. These horses are more likely to be in the back half of the stall rather than the front half (Robertson 2010, Gleerup 2016). Some horses will show self-mutilation in response to pain, although this is more common with chronic pain. Some horses will also become aggressive towards people. More recently, subtle changes in facial expression have been associated with pain (Gleerup 2016). The most commonly observed facial expressions in horses experiencing pain are asymmetrical or low ears or ears held stiffly backwards,

angled eye or orbital tightening, withdrawn and tense stare, square-like strained nostrils, tension of the muzzle and tension of the chewing muscles (Gleerup 2014, Gleerup 2016).

As previously mentioned, physiological parameters have been associated with degree of pain although these are non-specific and vary significantly between horses. Some parameters that have been correlated to pain, although not consistently in all studies, include heart rate (Lindegård 2009, Gleerup 2016), respiratory rate (Bussières 2008, Gleerup 2016), blood pressure (Bussières 2008, Gleerup 2014, Gleerup 2016). Cortisol also increases with pain (Gleerup 2016) as do B-endorphins (Raekallio 1997, Gleerup 2016). Catecholamines, intestinal sounds and rectal temperature have been shown not to correlate with pain (Gleerup 2016).

Another method of pain assessment used in the clinical setting is to provide pain relief to determine if this causes a change in behavior or demeanor (Gleerup 2016). To help in assessment of pain, equine adapted pain scales based on the behavioral characteristics described, (Raekallio 1997, Robertson 2010, Gleerup 2016) are frequently used in the hospital at Oregon State University for a variety of painful conditions including evaluation and quantification of ophthalmic pain. Ophthalmic pain specific scales exist in human medicine, but there do not appear to be any in equine veterinary literature as yet (Caudle 2007).

Ophthalmic pain can be extremely severe. Even the smallest erosion in the epithelium of the cornea is severely painful and can impact quality of life (Robertson

2004, Williams 2010). The cornea is the most densely innervated area of the body. Injuries to the cornea also cause at least a partial break down in the blood-aqueous barrier leading to secondary uveitis (Annear 2012). Animals with corneal (or other ophthalmic) disease show many of the generalized pain responses discussed earlier, as well as the facial expressions of pain (Williams 2010).

The pain associated with ophthalmic disease comes from a combination of inflammatory cell proliferation, vascular congestion, spasm of iridial and ciliary muscles with miosis as well as ciliary body derived pain. Photophobia is present in most cases, contributing to pain as there is a link between bright light and noxious trigeminal stimulation (Robertson 2004, Williams 2010). Horses with ocular disease are also considered to be at risk for colic while hospitalized. In a study by Patipa et al, 21.4% of horses hospitalized for ocular disease experienced signs of colic during hospitalization (Patipa 2012). Of the affected horses, 87.5% of these were successfully managed medically and 13.9% were diagnosed with a cecal impaction. Risk factors identified in this study were age (<1 year and >21 years at increased risk) and increased duration of hospitalization (>8 days). Contributing factors may have included administration of pharmaceuticals that alter gastrointestinal motility. Alpha₂-agonists are well known to decrease intestinal motility. Some studies have identified a higher incidence of colic in horses receiving opioids although this finding is debated among clinicians and many studies have been performed in non-painful horses. Topical administration of atropine has also been identified as a risk factor due to its potent inhibition of intestinal motility (Patipa 2012). Williams et al. evaluated colic gastrointestinal motility in healthy non-

painful horses administered topical ophthalmic atropine and atropine as a single sub-conjunctival injection. Although these horses were administered atropine significantly more frequently than is usual during treatment of a clinical corneal ulcer, gut motility was absent in all horses for 2-18 hours post administration of topically administered atropine. Signs of colic occurred in 4/6 horses that received topical atropine. One of six horses that received sub-conjunctival atropine showed colic (Williams 2000). Duration of hospitalization may be partially responsible for development of colic in some of these studies because horses being treated for ophthalmic disease tend to be hospitalized for longer durations compared to other indications and often undergo general anesthesia, have feed and management changes associated with a change in housing, and are often fairly painful, all of which are known risk factors for colic in horses.

3.5.2 Measurement of Corneal Sensitivity and Associated Factors

Corneal sensitivity in horses is greatest in the center of the cornea and less sensitive in the periphery (Brooks 2000). Corneal sensitivity can be objectively measured using a Cochet-Bonnet aesthesiometer, with pressure applied with the tip of the thin nylon filament able to stimulate approximately 100 nerve endings spread over 4-10 corneal epithelial cells (Rozsa 1982, Brooks 2000). Corneal sensitivity is important in corneal epithelial healing and may be affected by ophthalmic as well as systemic diseases (Brooks 2000). The sensitivity of the cornea can be affected by several factors. Corneal touch threshold is higher (more sensitive) in younger horses than older horses. Horses diagnosed with pituitary pars intermedia dysfunction (PPID) had an even less sensitive cornea. Because decreased sensitivity of the cornea has been previously associated with

impaired healing of the epithelium, older horses and horses with PPID may be at higher risk for developing non-healing or recurrent corneal ulcers (Miller 2013). This is in keeping with a human study that found older humans have a less sensitive cornea (Millodot 1977).

The cornea has been found to be more sensitive in human females. The same study found corneal sensitivity was not affected by ambient temperature within a normal environmental temperature range, or humidity (Golebiowski 2008).

Wiser et al studied whether there was a correlation between corneal sensitivity and quantity of reflex tearing, however no correlation could be identified (Wieser 2013).

In dogs, the shape of skull has an effect on corneal sensitivity with brachycephalic dogs having the lowest corneal sensitivity and dolichocephalic dogs having the most sensitive corneas (Barrett 1991). Age was a factor in corneal sensitivity in birds of prey, with fledglings having more sensitive corneas than adult birds (Lacerda 2014). During epithelial damage, Substance P and other mediators released from nociceptive fibers can stimulate healing of the corneal epithelium (Gilger 2011). This is because corneal nerves have a trophic effect on the epithelium via mediators such as Substance P (Brooks 2000).

Neonatal foals are especially prone to ophthalmic disease both as part of their systemic illness but also as a primary problem. Labelle et al found that of 70 foals less than 30 days of age, 55.7% had ≥ 1 ophthalmic lesions and 61.5% of these were potentially vision-threatening lesions (Labelle 2011). Foals can be difficult to diagnose corneal ulceration as they do not always show the typical signs that an adult horse will

show such as they may not have epiphora, blepharospasm or conjunctivitis (Brooks 2000). Corneal touch threshold measured by aesthesiometer in normal adult horses is 4.82 ± 0.87 cm. Healthy foals have a corneal touch threshold of 5.01 ± 0.61 cm and sick foals have a decreased corneal sensitivity with a touch threshold of 3.21 ± 0.24 cm (Brooks 2000).

3.5.3 Systemic Pain Medications

Many of the studies assessing efficacy of analgesics in horses have been performed using pain models and not using horses with naturally occurring disease (Muir 2010). The most commonly used systemic pain medications in horses fall into 4 categories, steroidal and non-steroidal anti-inflammatory drugs (Sanchez 2014), opioids, α_2 agonists and local anesthetics (Muir 2010). Examples of these include non-steroidal anti-inflammatory drugs (NSAIDs) such as phenylbutazone, flunixin meglumine, firocoxib and rarely ketoprofen. The opioids include butorphanol, nalbuphine, morphine, buprenorphine, fentanyl, and α -adrenergic agonists include xylazine, detomidine, romifidine, medetomidine (Sanchez 2014). Other systemic medications can include lidocaine, ketamine and gabapentin (Sanchez 2014). Adjunct therapies that are being investigated include acupuncture, chiropractic and nutraceuticals (Muir 2010).

Non-steroidal anti-inflammatory drugs produce their analgesic and anti-inflammatory effects by inhibiting cyclooxygenase (COX), which is the enzyme that converts arachidonic acid to prostaglandins, a vital step in the inflammatory pathway,

therefore NSAID's are most useful in treating mild to moderate inflammatory pain (Robertson 2004, Muir 2010). Prostaglandins exert their negative effects throughout the body by producing pain, fever and inflammation. However they have positive effects such as production of a protective gastric barrier to acidity, help maintain normal gastric secretion, maintain normal gut motility, regulate renal blood flow and contribute to maintenance of renal tubular function.

Current understanding is there are two COX enzymes. Cyclooxygenase 1 is primarily responsible for normal homeostasis and COX 2 is primarily responsible for the inflammation. However COX-2 is important for homeostasis and is considered constitutive in the central nervous system, kidney, eye and reproductive organs (Robertson 2004, Muir 2010). Potential side effects of inhibiting these two enzymes in horses include gastrointestinal toxicity (right dorsal ulcerative colitis and gastric ulcers) and nephrotoxicity, which can occur at clinically acceptable doses in some situations (Sanchez 2014). Both flunixin meglumine and firocoxib have been shown to penetrate the aqueous humor following oral administration at clinical doses. Firocoxib penetrated the aqueous humor to a greater extent than flunixin meglumine at days 3 and 5 (Hilton. 2011). Ocular concentrations of prostaglandin E_2 however, did not differ between groups (Hilton. 2011). Glucocorticoids, a steroidal anti-inflammatory drugs, act on the same pathway as NSAIDs but one step earlier, inhibiting phospholipase A_2 which is responsible for the breakdown of cell membrane phospholipids into arachidonic acid (Muir 2010).

Opioids are considered to be effective in horses although there are concerns for side effects and toxicity such as ataxia and hyper-excitability. The majority of opioids work by binding to mu receptors, however butorphanol and nalbuphine are agonist/antagonists that primarily exert effects on the kappa receptor. Opioids tend to be most effective when combined as part of a multi-modal pain relief plan. Horses in severe pain can develop central sensitization induced hyperalgesia and therefore combining analgesic drugs with different mechanisms of action is beneficial (Sanchez 2014). They also come with significant legal record keeping requirements due to their potential for human abuse and are considered to predispose to ileus, constipation and colic (Muir 2010, Sanchez 2014). Opioids can produce increased locomotor activity, agitation, disorientation and ataxia in some horses although side effects appear to be most significant in horses that are non-painful when administered these drugs. Mama et al. found that higher doses of a mu or kappa agonist led to a longer duration of locomotor activity compared to lower doses. Locomotor activity was also enhanced in horses when a kappa agonist and mu agonists were administered together (Mama 1992).

Administering an α_2 -agonist in combination with an opioid reduces central nervous system excitement (Sanchez 2014). Urine retention has been observed in some horses, especially after large or repeated doses of opioids. Fentanyl can be used in a constant rate infusion, and morphine can be used as part of a pentafusion constant rate infusion for severe pain (lidocaine, ketamine, morphine, detomidine, acepromazine) (Sanchez 2014). Fentanyl transdermal patches are also available in horses although they

have to be changed every 24-36 hours to be effective (Muir 2010) and the pain relief provided by these patches has been underwhelming in clinics. (Sanchez 2014).

Alpha-2 agonists produce some fairly significant side effects in addition to providing analgesia including sedation, ataxia, and reluctance to move due to muscle relaxation by their actions on alpha 2 receptors in differing locations. Alpha₂-agonists can be administered epidurally for certain painful conditions (Sanchez 2014). They tend to produce dose-dependent sedation, bradycardia, respiratory depression and occasionally violent behavior that can result in human injury. They can cause respiratory stridor, snoring, and irregular breathing in addition to sweating, diuresis and ileus, which can lead to colic on occasion (Muir 2010). Reversal agents exist (yohimbine, tolazoline and atipamazole) however side effects of these can be significant, including hypotension and sudden death.

Gabapentin was initially developed as anti-seizure medications and reduces calcium influx but is also used as an adjunctive analgesic although with questionable efficacy. It is primarily recommended for treatment of chronic neuropathic pain (Muir 2010, Sanchez 2014). Tramadol is a mild mu agonist most commonly used in dogs, and has been shown to provide some analgesia when administered to horses IV or epidurally, however oral bioavailability is extremely poor and elimination is rapid (Muir 2010).

Acupuncture is a commonly used adjunctive pain control option in human medicine (Habacher 2006) and is gaining popularity in veterinary medicine. There are

limited numbers of scientific studies evaluating the efficacy at this time and it is therefore difficult to conclusively state whether it is effective (Habacher 2006).

3.5.4 Review of Morphine and Other Opioids in Equine Pain Control

Use of opioid analgesia in horses has been slow to gain popularity. This is partly because early literature was overlooked, and partly because of publications detailing the closeness of analgesic and excitatory dosing in horses (Bennett 2002, Clutton 2010, Menozzi 2012). One single opioid does not appear to be effective for all types of pain and recent studies have been more supportive of using opioids in equine medicine as they can provide excellent visceral and superficial analgesia (Bennett 2002, Clutton 2010). The most commonly used opioids in equine medicine are fentanyl (selective mu agonist), morphine (preferential mu agonist, delta agonist at high doses), butorphanol and nalbuphine (kappa agonist and mu antagonist). In addition to activating mu receptors, at high doses, morphine is also capable of activating delta opioid receptors (Wenk 2003).

When administered intramuscularly to normal horses, morphine (0.1mg/kg) has a terminal half life of 1.5 hours, volume of distribution of 4.5L/kg and clearance of 35ml/kg/min (Devine 2013). Peak plasma concentration was 21.6ng/mL, which occurred 4 minutes after administration of the morphine before dropping below the limit of quantification by a maximum of 7 hours post administration. Adverse effects included mild excitation in one horse, mild injection site reaction and mild sedation in several horses. Side effects were considered uncommon and mild (Devine 2013). The primary metabolites from morphine administration in horses are 3-morphine-glucuronide and 6-

morphine-glucuronide, as in other species (Knych 2013). In mice, 3-morphine-glucuronide has been shown to be neuro-excitatory in itself (Knych 2013). Muscle fasciculations were observed at 0.2 and 0.5mg/kg and ataxia at 0.5mg/kg. Gastrointestinal activity was decreased in both groups (Knych 2013).

Figueiredo et al. looked at morphine administered to healthy non-painful horses (0.05mg/kg and 0.1mg/kg) administered IM or IV. Both IV and IM administration caused minimal and short-term cardiorespiratory, intestinal motility and behavioral changes at both dosages. Neither dose affected the horses responses to noxious stimuli (Figueiredo 2012). Rectal administration of morphine has been investigated in dogs and was found to have bioavailability below that of orally administered morphine, therefore rectal administration provided no advantages (Barnhart 2000). This does not appear to have been studied in horses.

Opioids enhance the sedative effects of α_2 -agonists, and appear to have a synergistic effect in providing analgesia when administered in combination (Bennett 2002, Clutton 2010). Opioid receptors are distributed throughout the central nervous system and gastrointestinal tract. The equine cerebrum has predominantly mu receptors (71% mu receptors, 14% kappa receptors and 15% delta receptors). The equine cerebellum has predominantly kappa receptors (59% kappa, 37% mu and 4% delta receptors) (Thomasy 2007). Receptor distribution varies between species (Hellyer 2003). Mu receptors are largely found in the sub mucosal plexus and kappa receptors have large numbers in the myenteric plexus (Boscan 2006). When opioids bind to the receptors in

the CNS, they cause analgesia. When they bind to receptors in the gastrointestinal tract they can cause alterations in motility, secretion, absorption and blood flow (Boscan 2006, Devine 2013). The extent to which secretory activity is decreased appears to be species specific (Boscan 2006).

Both morphine and fentanyl at higher doses than used clinically, have been shown to inhibit cecocolic electrical and mechanical activity for up to 3 hours in a small number of pain-free ponies (Clutton 2010). Morphine has been shown to have a constipative effect in normal horses, similar to humans and other veterinary species (Bennett 2002, Boscan 2006, Clutton 2010, Menozzi 2012). In the study by Boscan et al, morphine at 0.5mg/kg twice daily in healthy adult horses decreased propulsive motility and moisture content in the gastrointestinal tract (Boscan 2006). However it is worth noting that this dose is significantly higher than the dose that is commonly used in clinical cases. Based on a study performed by Menozzi et al, it appears inhibition of motility in equine small intestine may be mediated by kappa receptors but not mu opioid receptors. Mu opioid receptors appear to mediate their GI motility effects by their anticholinergic activity (Menozzi 2012).

Many of the horses receiving morphine for analgesia are often also receiving other medications that can depress gut motility such as α_2 -agonists, NSAID's and ketamine. The combination effect therefore is a high risk for development of colic, but the implication of opioid drugs as a principal cause of postoperative colic at this point is anecdotal and unsupported by epidemiologic studies (Clutton 2010).

Opioids can have cardiovascular effects, although this depends on the specific drug used, other drugs that the patient is being treated with at the same time, route of administration of the opioid and the patient's level of consciousness at the time of administration (Clutton 2010). Overall, opioids do not seem to depress cardiovascular parameters in horses as significantly as they do in other species (Bennett 2002, Clutton 2010). Some transient changes have included an increased heart rate and increased blood pressure (Clutton 2010). Morphine has been observed to cause urticaria in horses as well as pruritus after epidural administration. This has also been described in humans, dogs and sheep (Burford 2006, Kalchofner 2007). Respiratory effects of opioid drugs in horses tend to be mild although there is a widely held view that higher doses of intra-operative opioids suppress ventilation in anesthetized horses (Clutton 2010). In a more recent study by Clark et al., they found that pre-anesthetic and peri-operative morphine administration to horses undergoing elective surgical procedures was not associated with significant hemodynamic or ventilatory changes (Clark 2005). Horses anesthetized for upper respiratory tract surgery that received morphine were found to have a decreased PaO₂ compared to horses that did not receive morphine. This did not appear to be clinically significant, nor were any other significant cardiopulmonary effects detected. The horses in the morphine group generally had better anesthesia recoveries than those that did not receive morphine (Love 2006). Morphine has been loosely linked to two cases of post-operative pulmonary edema, possibly secondary to morphine induced urinary retention (Clutton 2010). Opioids can also cause a dose-dependent increase in muscle tone and locomotor activity in horses. Typically mu agonists such as morphine and fentanyl seem

to cause this the most. Kappa receptors tend to cause a lesser locomotor stimulation (Bennett 2002).

Morphine administered into the epidural space can provide profound analgesia for hind-limb pain in horses (Bennett 2002, Kalchofner 2007, Clutton 2010). Epidurally administered morphine and buprenorphine have also been shown to provide analgesia in the forelimbs of ponies with experimental carpal synovitis (Freitas 2011). There is also evidence opioids can produce potent analgesia in peripheral tissues by acting at local opioid receptors. This includes intra-articular injection of morphine as well as morphine in intravenous regional limb perfusions. No deleterious side effects have been reported following these routes of administration (Bennett 2002, Hunter 2015). Opioids are frequently used for managing mild to moderate postoperative pain following arthroscopic joint surgery. Administering these medications directly into the joint allows a small total dose to be used, therefore potentially decreasing risk of systemic side effects (Buus Frost 2011). Sheehy et al demonstrated presence of mu opioid receptors in synovial tissue, in particular the proliferative lining layer and in regions surrounding vascular structures. In this study there did not appear to be any differences in binding between horses with inflammation and horses without inflammation (Sheehy 2001). It is thought that opioid receptors in joints do not experience tolerance, therefore small amounts of an opioid may be continuously effective when administered intra-articularly (Stein 1996, Sheehy 2001).

Long-term morphine treatment induces the emergence of delta-opioid receptors as well as delta-opioid receptor mediated analgesia (Ma 2006). Along the same lines, co-

administration of mu and delta opioid receptor agonists can enhance analgesic outcomes (Schramm 2010). Another study found that when morphine was administered intra-articularly in horses with synovitis, it exerted anti-inflammatory effects. These horses had less joint swelling, lower synovial fluid protein concentrations and lower serum and synovial serum amyloid A concentrations, as well as lower peripheral total white blood cell counts than horses that has morphine administered systemically (Lindegaard 2010). van Loon et al. found the mu opioid receptors are up regulated in acute synovitis, however this is attenuated with use of anti-inflammatory drugs (van Loon 2013).

Mu receptors have been found to be present in corneal epithelium, granulocytes, plasma cells and macrophages (Stiles 2003, Hunter 2015). Opioid receptors have been identified on primary nerve fibers, especially in the superficial dorsal horn of the spinal cord but also in peripheral tissues (Joris 1987, Wenk 1999). Perineural injection of morphine provides significant pain relief in some but not all studies (Joris 1987). Several studies in rats have shown opioids are able to produce an analgesic effect when injected locally into inflamed tissue, presumably through peripheral opioid receptor activation (Joris 1987, Stein 1988). Wenk et al. examined various tissues in rats and macaque monkeys for presence of opioid receptors in peripheral sites. Delta receptors were located in skin, corneas, eyelids and lip and well as blood vessels. Receptors appear to be associated with sensory fibers but not with postganglionic sympathetic neuron terminals (Wenk 1999).

In addition to providing analgesia by direct anti-nociceptive effects, opioids can

also decrease inflammatory induced pain from prostaglandin production by inhibiting release of Substance P from neurons (Wenk 2003). Morphine applied every two hours following application of cautery to the rat cornea decreased development of corneal stromal edema as well as infiltration of immune cells. This anti-inflammatory effect was prevented with the opioid antagonist naloxone (Wenk 2003).

3.5.5 Overview of Topical Ophthalmic Medications and Treatments for Pain

Control

Local anesthesia involves temporary blocking pain sensation. Local anesthetics work by binding reversibly to sodium channels, preventing transmission of nerve impulses. This disrupts sensory, motor and autonomic function of the targeted area (Labelle 2013). Local anesthetic effect depends largely on chemical structure. They consist of a hydrophobic aromatic ring, a linkage site between the aromatic ring and an intermediate chain and a hydrophilic amine. The hydrophobic portion is essential for activity as this part allows diffusion through the lipid nerve membrane. Greater hydrophobicity increases access of the local anesthetic to its site of action and decreases its metabolism, which in turn increases its potency and duration of action. However, greater hydrophobicity also increases risk of toxicity (Plumb 2011). Topical anesthetics cause punctate keratitis, as well as necrotizing keratitis, delay epithelialization and prevent cell migration and mitosis (Carney 1984, Plumb 2011). For these reasons, topical anesthetics are suitable only for intermittent diagnostic purposes and not therapeutically for pain control (Marr 1957, Plumb 2011). Further discussion of local anesthetics can be found in section 3.2.4.1 and 3.2.4.2.

Topical morphine has been used experimentally in rabbits, people and dogs and has in some papers been found to have a rapid onset of action (decreased aesthesiometry reading and decreased blepharospasm) and provide notable analgesia without delaying epithelial wound healing (Robertson 2004, Plumb 2011). Topical morphine has not been evaluated in horses prior to the study reported in this thesis. Both mu and delta receptors have been identified in the cornea of normal dogs, although mu were only present in small numbers (Stiles 2003, Plumb 2011). In humans, topically applied 4% morphine has been shown to cause miosis in the treated eye only, although the mechanism for this has not been fully detailed (Fanciullacci 1984). Also in humans, 0.5% morphine applied topically following photorefractive keratectomy was found to reduce post operative pain and appeared safe (Faktorovich 2010). In a study looking at epithelial healing and corneal sensitivity in rabbits with morphine, proparacaine and saline study groups, proparacaine slowed healing of corneal ulcers, whereas morphine did not. The morphine treated group also showed analgesia as quickly as 10 minutes after application to the group with corneal abrasion, however did not have an analgesic effect on the intact cornea (Peyman 1994).

Stiles et al. investigated a 1% morphine sulfate solution on signs of pain and corneal wound healing in dogs (Stiles 2003). They found the presence of numerous delta and infrequent mu opioid receptors in corneal epithelium and anterior stroma of normal dogs. Dogs in the morphine treatment group showed reduced blepharospasm and lower aesthesiometer scores than control group dogs. Duration of healing of the experimentally created ulcers were no different in the morphine treated group than in the control group

(Stiles 2003). In contrast, a study by Thomson et al evaluated the analgesic effects of topical 1% morphine in dogs and cats in clinically affected animals. This group found morphine did not provide analgesia in the treatment group and in fact, some of the morphine treated cats and dogs showed side effects consisting of increased blepharospasm, conjunctival hyperemia and increased blink rate (Thomson 2013).

When topical 1% morphine was applied to rabbit corneas following lamellar keratectomy it promoted corneal analgesia and did not delay corneal re-epithelization (Ribeiro 2012). Type IV collagen was similar between morphine treated and control groups. The area of ulceration was found to be larger in the morphine treated group although, which could potentially be due to morphine induced inhibition of Substance P (a trophic factor) from peripheral sensory nerve endings (Ribeiro 2012). Alternatively, MMP 9 and MMP-2 were elevated in morphine treated rabbits at day 6. Levels of MMP-9 returned to baseline by day 12 of this study, whereas levels of MMP-2 remained elevated in morphine treated corneas for the duration of the study (Ribeiro 2012). Topically administered morphine has been shown in rabbits to be systemically absorbed rapidly and to levels that are compatible with pharmacological activity. This appears to be the only species that systemic absorption of topical morphine has been analyzed in (Chast 1991).

Nalbuphine hydrochloride has been used in corneal analgesia. It binds primarily to kappa receptors as an agonist and partial mu antagonist; therefore it cannot be used in conjunction with morphine or fentanyl, which are both mu agonists (Plumb 2011).

A study in horses by Wotman et al. found that application of topical 1% nalbuphine solution to clinically normal eyes had no effect on corneal sensitivity as measured by aesthesiometer. It also did not cause any ocular irritation (Wotman 2010). Clark et al. also studied the effectiveness of topical nalbuphine in dogs with corneal ulcers. Four out of five dogs required rescue analgesia to be administered, significantly more than the control or tramadol group, suggesting topical nalbuphine provides inadequate analgesia in dogs with corneal ulcers (Clark 2011).

Topical fentanyl has also been evaluated in humans with corneal damage (Zollner 2008). Human corneas were found by immunohistochemical staining to contain both mu and delta opioid receptors localized on nerve fibers within the cornea. In this study, topical application of fentanyl (with dexpanthenol) did not provide measurable analgesia (Zollner 2008).

Topical NSAIDs can be extremely effective in providing pain relief in corneal disease. As with systemic NSAIDs, they are both analgesic and anti-inflammatory. They are less potent anti-inflammatory drugs than topical corticosteroids (Plumb 2011). In cases with disruption of the corneal epithelium such as ulcers, NSAIDs should not be used past the peri-operative period as they have been shown to inhibit re-epithelialization, interfere with lacrimation, cause swelling of the cornea and also increases permeability of the cornea (Robertson 2004). Additionally reported side effects include punctate keratitis, keratomalacia, and corneal toxicity (Guidera 2000, Plumb 2011). They can also add to systemic effects of NSAIDs and their associated systemic toxicity (Plumb 2011).

NSAIDs can also induce mydriasis and reduce breakdown of the blood-aqueous barrier by their anti-inflammatory action.

Commonly used topical corneal NSAID's include bromfenac 0.09% solution, diclofenac sodium 0.1% solution, flurbiprofen sodium 0.03% solution, ketorolac tromethamine 0.5% solution, nepafenac 0.1% solution and suprofen 1% solution. A human study assessing the use of diclofenac eye drops found that 42% of patients treated with diclofenac developed persistent epithelial defect for more than 8 days postoperatively following keratoplasty which was significantly more than for those that were not treated with diclofenac (Shimazaki 1995). This suggests that diclofenac may be toxic to corneal epithelium and should only be used with extreme caution following corneal surgery (Shimazaki 1995, Guidera 2000).

Steroidal anti-inflammatory medications and topical corticosteroids are more potent anti-inflammatory than NSAIDs. Ocular side effects can include predisposition to developing cataracts, increased intra-ocular pressure, infection, decreased wound healing, mydriasis and calcific keratopathy. They can have systemic effects such as hepatopathy and suppression of endogenous glucocorticoid production (Plumb 2011). Topical steroids should never be used when epithelial defects such as a corneal ulcer are present.

Commonly used topical steroidal medications include prednisolone acetate 0.12-1%, dexamethasone 0.1%, betamethasone, fluorometholone 0.1%, loteprednol 0.2-0.5% and rimexolone 1%. Penetration of these medications to the posterior aspect of the eye is poor so inflammation of the posterior aspect of the eye may be better treated with

systemic anti-inflammatory medications such as prednisolone or dexamethasone (Plumb 2011). Steroids can also be administered by sub-conjunctival injection. Prednisolone and dexamethasone have short acting effects and long acting depot effects can be achieved by use of betamethasone, triamcinolone or methylprednisolone acetate (Martins 2012). Topically applied dexamethasone does not have negative effects on corneal cell morphology in tissue culture (Hendrix 2002). Prednisolone and hydrocortisone both caused rounding and shrinkage of the corneal epithelial cells. Dexamethasone and hydrocortisone did not inhibit corneal epithelial migration over the defect created in the tissue culture monolayer, whereas prednisolone did inhibit cell migration over the defect (Hendrix 2002).

Atropine sulfate is a mydriatic/cycloplegic used for therapeutic purposes and acts by blocking cholinergic receptors of the iris and ciliary body to cause dilation and paralysis of the ciliary body (Plumb 2011). Atropine, while often overlooked for purposes of pain control, can significantly assist in controlling ocular pain secondary to corneal and uveal disease (Williams 2010). Atropine can be combined with 10% phenylephrine for purposes of pupil dilation, however phenylephrine does not contribute to pain control (Plumb 2011). Atropine is contraindicated in glaucoma. Atropine can be administered by sub conjunctival injection, either alone or in combination with phenylephrine (Martins 2012).

Another non-conventional analgesic technique that has been gaining popularity is therapeutic soft contact lenses/bandage contact lenses. These fit to the cornea and protect

the cornea from further damage, provide pain relief by covering exposed nerve endings, and accelerate healing by helping corneal epithelium to adhere to the stroma (Robertson 2004).

4.0 Evaluation of Short-Term Topical 1% Morphine Sulfate Application on the Healthy Equine Eye

4.1 Introduction

The use of topical opioid analgesia in treating ophthalmic disease has been gaining interest recently in both human and veterinary medicine (Fanciullacci 1984, Chast 1991, Peyman 1994, Wenk 1999, Acheampong 2002, Stiles 2003, Wenk 2003, Aquino 2005, Zollner 2008, Wotman 2010, Clark 2011, Thomson 2013). This is partly due to recognition that these patients can remain in significant discomfort despite maximal doses of systemic pain medications being administered (Wotman 2010, Clark 2011). The cornea is one of the most densely innervated tissues in the body (Brooks 2000, Stiles 2003, Lwigale 2007, Thomson 2013). Sensory innervation derives from the trigeminal nerve and the density of nerves in the cornea is 300-600 times greater than in the skin (Rozsa 1982, Brooks 2000). Acquired corneal disease, particularly ulcerative keratitis, is common in horses (Wotman 2010).

Currently available systemic analgesics include steroidal and non-steroidal anti-inflammatory drugs, opioids, α_2 -agonists and local anesthetics (Muir 2010, Sanchez 2014). Potential side effects of steroidal and non-steroidal drugs include nephrotoxicity and gastrointestinal toxicity which can even occur at clinically appropriate doses (Sanchez 2014). In addition to analgesia, α_2 -agonists cause sedation, ataxia, respiratory depression, sweating, diuresis and ileus (Muir 2010). Opioids are considered fairly effective when used systemically in horses although there are concerns for potential side

effects including ataxia and hyper-excitability. They also come with significant legal record keeping requirements due to their potential for human abuse and are considered to predispose to ileus, constipation and colic (Muir 2010, Sanchez 2014).

A range of topical analgesic medications is currently available, including NSAIDs, steroids, and local anesthetics. Unfortunately, no currently available drug is suitable for repeated therapeutic use. Local anesthetics have been shown to cause punctate keratitis and delay healing (Carney 1984) and are therefore only appropriate for intermittent diagnostic purposes. Topical NSAIDs, while effective in providing corneal analgesia, are contraindicated when the surface of the cornea is not intact (Guidera 2000, Robertson 2004). Steroidal medications are also contraindicated when epithelial defects are present (Plumb 2011).

Morphine is one of the most commonly administered opioids in equine medicine. It is a preferential mu agonist although at high doses it can also activate delta receptors (Wenk 2003). When administered intramuscularly at 0.1mg/kg it has a terminal half life of 1.5 hours and peak plasma concentration of 21.6ng/ml which occurred 4 minutes after administration (Devine 2013). In addition to systemic application, opioids can produce potent analgesia in peripheral tissues by acting at local opioid receptors (Joris 1987, Wenk 1999, Sheehy 2001, Bennett 2002, Hunter 2015). Local peripheral use allows a smaller total dose to be used, potentially decreasing the risk of systemic side effects (Buus Frost 2011). An additional benefit to local intra-articular use of morphine in horses is that it has local anti-inflammatory effects (Lindegaard 2010). Mu receptors have also

been found to be present on corneal epithelium, granulocytes (Stiles 2003), and nervous tissue (Joris 1987, Wenk 1999). In addition, delta receptors have been demonstrated in skin, cornea, eyelids, lip and blood vessels (Wenk 1999).

Topical morphine has been used experimentally in rabbits, people and dogs and has in some papers been found to have a rapid onset of action (decreased aesthesiometry reading and decreased blepharospasm) and provide notable analgesia without delaying epithelial wound healing (Robertson 2004, Plumb 2011). Topical morphine has not previously been evaluated in horses. In humans, morphine applied topically was found to reduce post-operative pain without negative side effects (Faktorovich 2010). In dogs, Stiles et al., found morphine treated dogs with experimentally created ulcers had reduced blepharospasm and lower aesthesiometer scores without affecting healing (Stiles 2003), however Thomson et al. found topical morphine to be ineffectual in both dogs and cats (Thomson 2013). Topically administered morphine in rabbits has been shown to be systemically absorbed rapidly and to levels that are compatible with pharmacologic activity. This appears to be the only species that systemic absorption of topical morphine has been analyzed in (Chast 1991).

Our first hypothesis was corneal epithelial cell integrity would not be detrimentally affected by short-term administration of 1% morphine sulfate based on histological examination. Our second hypothesis was that topical 1% morphine applied to the equine corneal would result in ocular but not systemic absorption.

4.2 Materials and Methods

4.2.1 Animals and Treatments

All animal procedures were approved by the Oregon State University Animal Care and Use Committee (IACUC) (ACUP # 4527). Six client-owned horses were donated to Oregon State University for enrollment in this study. All six horses were donated due to chronic unresolvable lameness that made it impossible for them to continue to be performance horses.

Prior to inclusion, each horse was subjected to a full physical examination followed by full ophthalmic examination of both eyes to ensure the horse was healthy with normal eyes and in particular normal corneas. The ophthalmic examination included assessment of reflexes (dazzle, palpebral and presence of direct and indirect pupillary light reflexes) as well as evaluation of a menace response. The gross appearance of the eye was evaluated using a Finoff trans illuminator, followed by slit-lamp biomicroscopy of the cornea and anterior chamber. Indirect ophthalmoscopy was utilized for fundic evaluation without application of mydriatic agents to avoid medication interference with study results. A schirmer tear test¹ was done, followed by fluorescein stain² to evaluate corneal epithelial integrity. Intra-ocular pressures were obtained from both eyes³.

A normal physical examination and normal ophthalmic exam in both eyes made a horse eligible for study inclusion. The exam was conducted without sedation or perineural anesthesia. The study group consisted of five geldings and one mare ranging

in age from eight to 23 years with a mean age of 13 years. Included breeds were Quarter Horse (5), and Dutch Warmblood (1). See table 2.

During corneal histology evaluation post euthanasia, both treated and control corneas of one horse had evidence of underlying, chronic, Equine Recurrent Uveitis (ERU). Due to the presence of underlying microscopic ocular disease not identified during ophthalmic examination. This horse was removed from the study, along with all data generated by its' inclusion. A seventh horse was then enrolled based on the previously stated inclusion criteria to bring the final tally of horses completing the study to seven. Further details of the excluded horse are found in section 4.5.

Horse Number	Age (years)	Breed	Gender	Included in final results?
1	8	Quarter Horse	Gelding	Yes
2	23	Quarter Horse	Gelding	Yes
3	12	Quarter Horse	Gelding	Yes
4	15	Quarter Horse	Gelding	Yes
5	18	Quarter Horse	Gelding	No
6	9	Quarter Horse	Gelding	Yes
7	11	Dutch Warmblood	Mare	Yes

Table 2. Descriptive details of horses included in the study.

After study admission, an intravenous jugular catheter⁴ was placed in the left

jugular vein of all horses to allow administration of medication such as sedation, as well as blood sample collection for morphine pharmacokinetic analysis. Several horses required sedation for placement of the jugular venous catheter and sub-palpebral lavage system. When utilized, sedation consisted of xylazine hydrochloride iv (0.4mg/kg)⁵, a short acting alpha 2 adrenergic agonist.

Placement of the jugular venous catheter was done as such:

A 2 inch square area of hair was clipped over the left jugular vein using electric handheld Clippers⁶. Surgical preparation of the skin was done with betadine scrub⁷ followed by an alcohol rinse⁸ before the skin at the site of catheter placement was anesthetized with a subcutaneous injection of 2ml mepivacaine local anesthetic agent (Carbocaine)⁹. The area was prepped a second time followed by a second alcohol rinse⁸. A 14 gauge, 5 1/4 inch Abbocath⁴ catheter was placed aseptically into the jugular vein. An injection cap¹⁰ was attached to the hub of the catheter and the catheter was sutured to the skin using 2-0 non-absorbable suture (Ethilon)¹¹. The injection cap was changed daily. The catheter was flushed four times daily with sterile heparinized saline¹² as well as after every sample collection to prevent blood clotting in the catheter.

Following placement of the jugular catheter, a sub-palpebral lavage system (SPL)¹³ was placed in the left eyelid of each horse, using the same sedation as for the jugular venous catheter. The SPL system was placed using the following technique: Proparacaine hydrochloride¹⁴, a topical ophthalmic anesthetic agent, was applied to the cornea to desensitize it to any contact made to the cornea during tubing placement. A

subcutaneous injection of 1cc of mepivacaine⁹ local anesthetic was injected subcutaneously over the auriculopalpebral nerve near the base of the ear. This nerve innervates the orbicularis oculi muscle in the upper eyelid that is responsible for closure of the eyelid. Temporary blockage of this blink reflex facilitates easier insertion of the tubing. A 2cm square area was clipped⁶ over the upper eyelid at the site of entry of the tubing and cleaning was again performed with betadine, using solution¹⁵ instead of scrub. Scrub can be irritating to the eye, so solution is a safer alternative when the area is located close to the cornea. A subcutaneous injection of 1cc carbocaine⁹ was placed in the clipped and prepped area of the upper eyelid where the SPL¹³ catheter was placed. Wearing sterile gloves, the index finger of one hand was placed under the upper eyelid and against the cornea to guide the passage of the needle under the eyelid while protecting the cornea. The needle was passed with the other hand under the eyelid and through the desensitized area of the upper eyelid. The needle was gently pushed through the desensitized area and then the silastic rubber tubing, which is attached to the needle, was pulled through the anesthetized area until the footplate was seated under the eyelid. The tubing was sutured to the forehead in two areas before being passed through braids in the mane to the level of the middle of the neck. The tubing was secured to a portion of braided mane. The injection port was changed daily.

Following intravenous catheter placement and sub-palpebral lavage placement, 0.25ml of 1% (2.5mg) preservative free morphine sulfate solution¹⁶ was applied to the treated eye via the sub-palpebral lavage tubing. This was slowly pushed through the tubing using 1ml of air injected via syringe, following injection of morphine solution.

The 25mg/ml commercial product was diluted to 10mg/ml using LiquiTears¹⁷ diluent. A volume of 0.25ml of 1% morphine solution was administered to the treated eye every 4 hours for 72 hours. This was a total of 19 morphine treatment applications per treated eye. The control eye was untouched.

4.2.2 Ocular and Systemic Side Effects

In order to assess systemic absorption of morphine following topical ophthalmic administration, serial blood sampling was performed via the intravenous catheter.

Samples following administration of the first morphine treatment assessed systemic absorption following a single application. Sampling on subsequent days was intended to assess whether accumulation of morphine occurs. See Table 3 for sampling times post morphine administration.

On Day One, serum samples were collected after the first morphine application of the experiment. On Day Two, serum samples were collected after administration of the morphine scheduled 24 hours after starting the experiment. On Day Three, serum samples were collected after administration of the morphine scheduled 48 hours after starting the experiment.

Day 1	0	0.5	5	10	15	25	35	45	55	65	75	85	95	155	215
Day 2	0	0.5	5	10	15	25	35	45	55	65	75	85	-	-	-
Day 3	0	0.5	5	10	15	25	35	45	55	65	75	85	-	-	-

Table 3. Serum sampling time points. Numbers are in minutes post morphine application. Time 0 was drawn before morphine was applied. Due to financial constraints, not all samples collected were analyzed.

At each blood sampling time point, 12ml of waste blood was drawn, followed by 10ml of sample blood. The waste blood was then promptly returned to the horse via the catheter and the catheter was flushed with 12ml of heparinized saline¹². The blood sample was placed into two red top vacutainer tubes¹⁸ containing no anti-coagulant and allowed to clot. Clotted blood in vacutainers was centrifuged¹⁹ at 3000rpm for 5 minutes. The serum was then transferred by pipette to individual eppendorf tubes²⁰ and immediately frozen at -80C. For the duration of the study period, all horses had physical examinations performed twice daily and an ophthalmic examination performed once daily.

Following administration of the final morphine solution at 72 hours, horses were euthanized according to AVMA guidelines by overdose of Beuthanasia²¹ (phenytoin and pentobarbital sodium salts) at 10ml per 100 lbs bodyweight.

Immediately following euthanasia, a 3ml sample of aqueous humor was obtained from both treated and control eye. Similarly, a 5ml sample of vitreous humor was obtained from both the treated and control eye. These samples were transferred into individual eppendorf tubes²⁰ and immediately frozen at -80°C.

4.2.3 Corneal Histology

Following sampling of the aqueous and vitreous humor, the cornea from morphine treated and untreated control eyes were removed at the level of the limbus and placed into 10% neutral buffered formalin at a 1:10 ratio of specimen to fixative. Samples were processed at the Oregon Veterinary Diagnostic Laboratory using standard histological procedures. The cornea was sectioned at 3-4µm and all sections were stained with Hematoxylin and Eosin for light

microscopy. All slides were examined by a board certified veterinary pathologist who was unaware of treatment status for each sample.

4.2.4 Enzyme Linked Immunosorbent Assay (ELISA) Quantification of Ocular and Systemic Morphine Absorption.

Serum, aqueous and vitreous morphine concentrations were quantified using a commercial direct ELISA kit²².

The procedure for doing the assay, as provided by the manufacturer is as follows. These instructions were followed exactly for all ELISA plates completed in this project.

1. Bring all specimens and kit reagents to room temperature and mix.
2. Dilute all specimens to the necessary range with PBS²³.
3. Add 20µl of standards into designated wells in duplicate.
4. Add 20µl of the diluted specimens in duplicate into designated wells
5. Add 100µl of the enzyme conjugate to each well. Tap the sides of the plate holder to ensure proper mixing.
6. Incubate for 60 minutes at room temperature preferably in a dark room at a temperature of 20-25C after addition of enzyme conjugate to the last well.
7. Wash wells six times with 350µl distilled water using a suitable plate washer or wash bottle, taking care not to cross contaminate wells.
8. Invert wells and vigorously slap dry on absorbent paper to ensure all residual moisture is removed. This step is critical to ensure the residual enzyme conjugate does not skew

results.

9. Add 100µl of substrate reagent to each well and tap sides of the plate holder to ensure proper mixing.

10. Incubate for 30 minutes at room temperature (20-25C), in the dark.

11. Add 100µl of stop solution to each well, changing the color from blue to yellow.

12. Measure the absorbance²⁴ at a dual wavelength of 450nm and 650nm. Compare average absorbance readings obtained from each unknown specimen with the average absorbance obtained from the Positive Reference Standard.

13. Wells should be read within one hour of color development.

The assay is sensitive to 1ng/ml.

The assay had been previously validated in human whole blood, serum, plasma and urine. A previous study at Oregon State University validated this assay for use in equine plasma (Hunter 2015). For the purposes of this study, the assay was validated for horse serum, aqueous and vitreous humor. Validation was performed using standard curves with a concentration range of 0-50ng/ml. These were created by adding known quantities of morphine to samples of serum, aqueous, and vitreous. The quantity of morphine added was the same as the standards supplied with the kit. Serum samples for validation curves were obtained from clinically healthy horses in the university teaching herd. Aqueous and vitreous humor samples were obtained from euthanized horses donated to the university for teaching for reasons such as chronic lameness. The standard curve made from serum, aqueous and vitreous were essentially identical to the standard curve produced by the kit standard controls that were supplied with the ELISA assay kit. See Figure 3.1-3.4.

Due to viscosity of aqueous and vitreous humor, further validation was performed to ensure sample accuracy when diluted. All aqueous humor samples were diluted in a ratio of 1:4. All vitreous humor samples were diluted in a ratio of 1:2 and 1:4. Dilution was performed using 1% phosphate buffered saline (PBS)²³. Serum and aqueous samples that provided high morphine concentration values were also diluted with PBS and re-run to achieve values within the standard curves. All samples were done in duplicate. Intra-assay consistency was evaluated by co-efficients of variation that were generated by the computer program for variation within the duplicate samples²⁵. Inter-assay validity was ensured by running the same sample on each plate to ensure consistency. Absorbances were read at 450nm and 650nm using an automated plate reader²⁴. Concentrations were determined using linear regression from absorbance by extrapolating sample concentrations from the individual standard curve that was run on each ELISA plate. Absorbance values obtained at 650nm were subtracted from absorbance values at 450nm to give a final absorbance value. This data was then entered into My Assays.com,²⁶ which converted absorbance into concentration reading based on the plate standard curve.

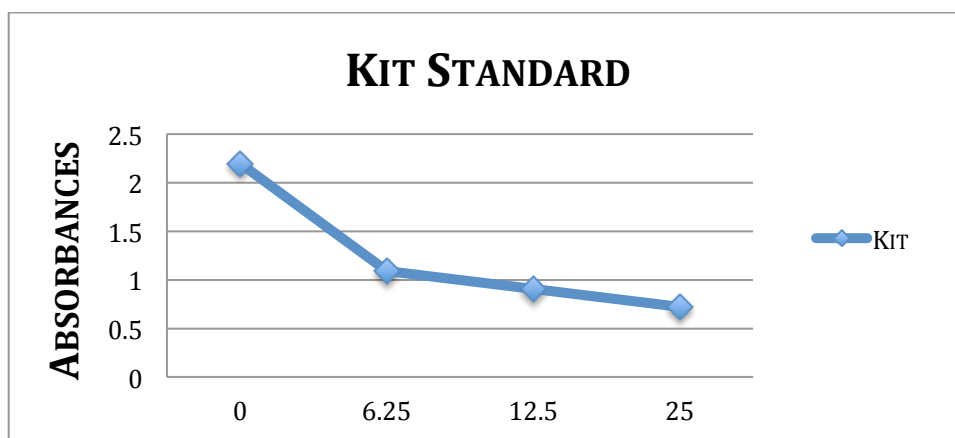


Figure 3.1 Graphical representation of the morphine standard curve (ng/ml) plotted using the kit standard reagents on the ELISA plate.

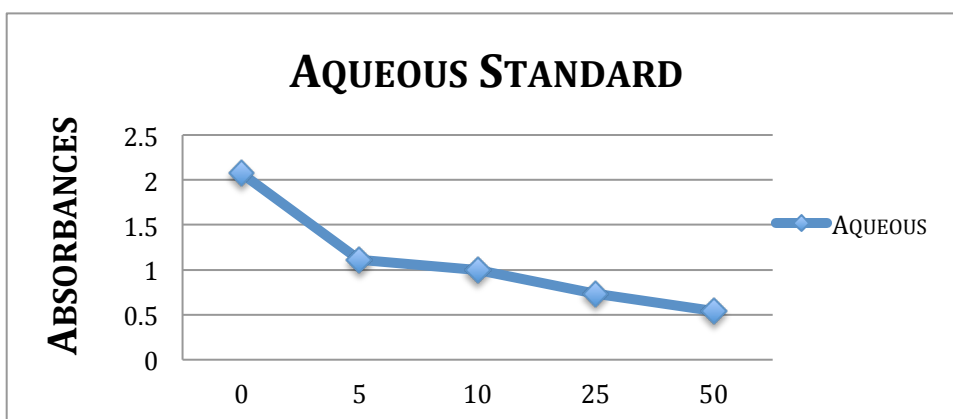


Figure 3.2 Graphical representation of the morphine standard curve (ng/ml) plotted using aqueous humor spiked with morphine on the ELISA plate.

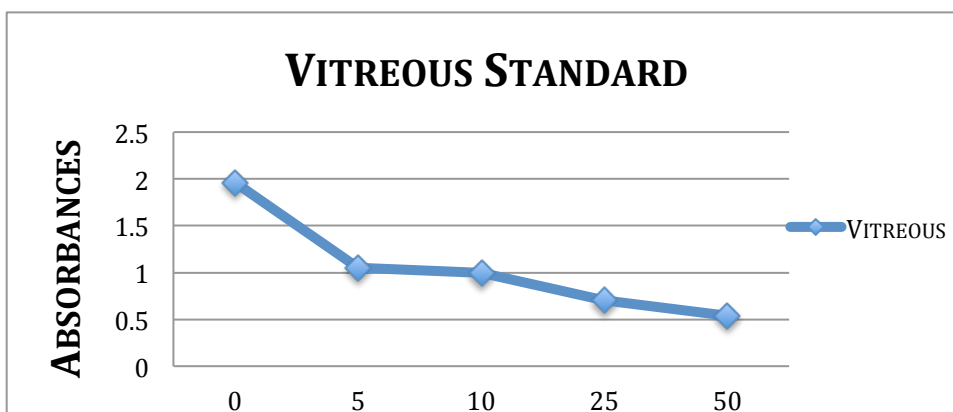


Figure 3.3 Graphical representation of the morphine standard curve (ng/ml) plotted using vitreous humor spiked with morphine on the ELISA plate.

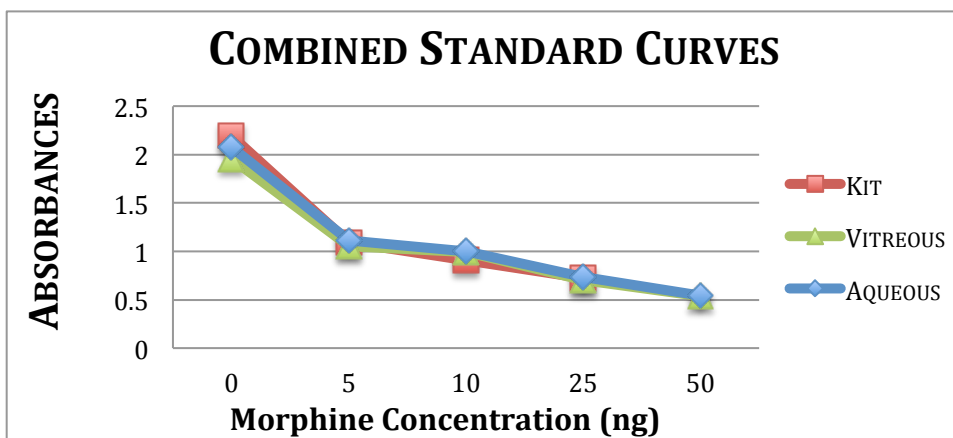


Figure 3.4 Graphical representation of the morphine standard curves of the kit standard, spike aqueous and vitreous humor. The close correlation of the standard curves was used in demonstrating the ELISA kit was valid for use in aqueous and vitreous humor. Due to the close correlation of the standard curves, the reading from the humors could be read on the kit standard curve.

4.3 Statistical Analysis

Results of aqueous, vitreous and serum concentrations are reported as mean \pm standard deviation. Physical examination parameters including heart rate and respiratory rate values were analyzed using One Way-Repeated Measures ANOVA after data passed a test for normality and equal variance. Intraocular pressure data was not normally distributed, but did have equal variance. This data was analyzed using Two Way-Repeated Measures ANOVA. Morphine concentrations in aqueous and vitreous humor were analyzed using a paired t-test. Statistical significance was set at $P \leq 0.05$ and data analysis was performed using commercial SigmaStat software²⁷. Graphical representation

was done using Microsoft Excel²⁸.

4.4 Results

Physical Examinations

Temperatures were within normal limits ($99 \pm 1.1^{\circ}\text{F}$) for all horses at all examination points with exception of horse four and horse six. Horse four had a low temperature of 97.7°F at initial examination, which was considered insignificant. Horse six had several temperatures elevated out of this range. Day one evening temperature was 100.8°F and day three morning temperature was 100.4°F , both of which may be considered normal. On day four however, morning temperature was 101.5°F and evening temperature was 102.3°F , which coincided with development of a significant sub-palpebral lavage infection.

Heart rates ($p=0.19$) and respiratory rates ($p=0.09$) did not differ significantly between days.

Horses had normal gastrointestinal sounds throughout the study and subjectively produced normal volumes of normally formed manure. Attitude and appetite of all horses remained normal. No signs of colic were observed at any time. Cardiovascular parameters assessed on physical examination were unaffected (mucous membrane color, capillary refill time, jugular fill and pulse quality).

Ocular Examinations

Gross ophthalmic examination of both treated and control eyes was normal at all examination time points with the exception of significant lid swelling and purulent

discharge from the horse with the SPL infection. All horses remained fluorescein negative. Schirmer tear test values remained within normal limits in treated and control eyes on all days. All horses developed mild to moderate mucoid ocular discharge in the treated eye, but not in the control eye. Morphine application had no effect on intra-ocular pressures ($P=0.615$).

Histology Results

With exception of horse five, histological examination of all treated corneas compared to control corneas found no difference between them and no evidence of microscopic damage caused by morphine administration. Horse five was excluded from the study due to treated and control corneal histology revealing mild, peripheral, lymphoplasmacytic keratitis accompanied by mild conjunctivitis consistent with ERU.

Absorption of Morphine into Aqueous Humor

Morphine was detected in aqueous humor of the treated eye for all six horses with a mean \pm standard deviation of 165.18 ± 87.69 ng/ml. The range was 57.31ng/ml to 296.49ng/ml. Morphine was not detected in aqueous humor in the control eye for any of the six horses. There was a statistically significant difference in aqueous morphine concentration between treated and control eyes ($P=0.006$).

Absorption of Morphine into Vitreous Humor

Morphine was detected in vitreous humor of the treated eye for five out of six

horses with a mean \pm standard deviation of $4.87 \pm$ standard deviation of 4.46ng/ml . The range was 0 to 12.93ng/ml . Morphine was not detected in vitreous humor in the control eye for any of the six horses. There was a statistically significant difference in vitreous morphine concentration between treated and control eyes ($P=0.044$).

Systemic Morphine Absorption in Serum

Morphine was detected in serum of five out of six horses at varying time points. All samples collected prior to the first morphine administration were negative for presence of morphine. As shown in Table 4, horse two did not have morphine present at detectable levels at any time point. There was significant variability in serum morphine concentrations between horses. Systemic concentration peak values were fairly low, with the average concentrations ranging from $0\text{-}2.98\text{ng/ml}$, and the individual concentration readings ranging from $0\text{-}6.98\text{ng/ml}$. Graphs were cut off at 125 minutes as all results for other time points were zero, and this allowed more accurate visualization of earlier data (Figures 4-9).

Time Point	Horse 1	Horse 2	Horse 3	Horse 4	Horse 6	Horse 7	Average	SD
Day One								
Pre	0.00	0.00	0.00	0.00	0.00	0.00	0.00	0.00
5 min	3.10	0.00	3.22				2.10	1.49
10 min	3.19	0.00	1.10	0.00	1.71	6.61	2.10	2.29
15 min	1.05	0.00	0.00				0.35	0.49
25 min	0.00	0.00	0.00	0.00	0.00	0.00	0.00	0.00
45 min	0.00	0.00					0.00	0.00
65 min	0.00	0.00	0.00	0.00	0.00	0.00	0.00	0.00
3.35 hour	0.00	0.00	0.00	0.00	0.00	0.00	0.00	0.00
Day Two								
Pre	1.13	0.00	1.00	0.00	0.00	0.00	0.36	0.50
5 min	4.94	0.00	6.98	0.00			2.98	3.07
10 min	3.50	0.00	3.96	3.31	3.95	1.88	2.77	1.42
15 min	2.99	0.00	5.66				2.88	2.31
25 min	3.52	0.00	3.20	1.48	3.41	2.07	2.28	1.26
45 min	2.46	0.00					1.23	1.23
65 min	2.91	0.00	0.00	N/A	1.83	0.00	0.95	1.35
1.35 hour	1.35	0.00	4.34	0.00	1.83	0.00	1.25	1.56
Day Three								
Pre	1.19	0.00	0.00	0.00	0.00	0.00	0.20	0.44
5 min	3.35	0.00	5.23				2.86	2.16
10 min	2.12	0.00	5.54	1.45	1.34	2.97	2.24	1.73
15 min			4.09					
25 min	1.87	0.00	2.71	1.19	0.00	0.00	0.96	1.06
45 min	2.38	0.00					1.19	1.19
65 min	2.85	0.00	1.49	0.00	0.00	0.00	0.72	1.10
1.35 hour	3.02	0.00	1.21	0.00	0.00	0.00	0.70	1.12

Table Four. Serum morphine concentrations (ng/ml) for horses treated with topical ophthalmic morphine. Blank boxes indicate that sample was not tested by ELISA.

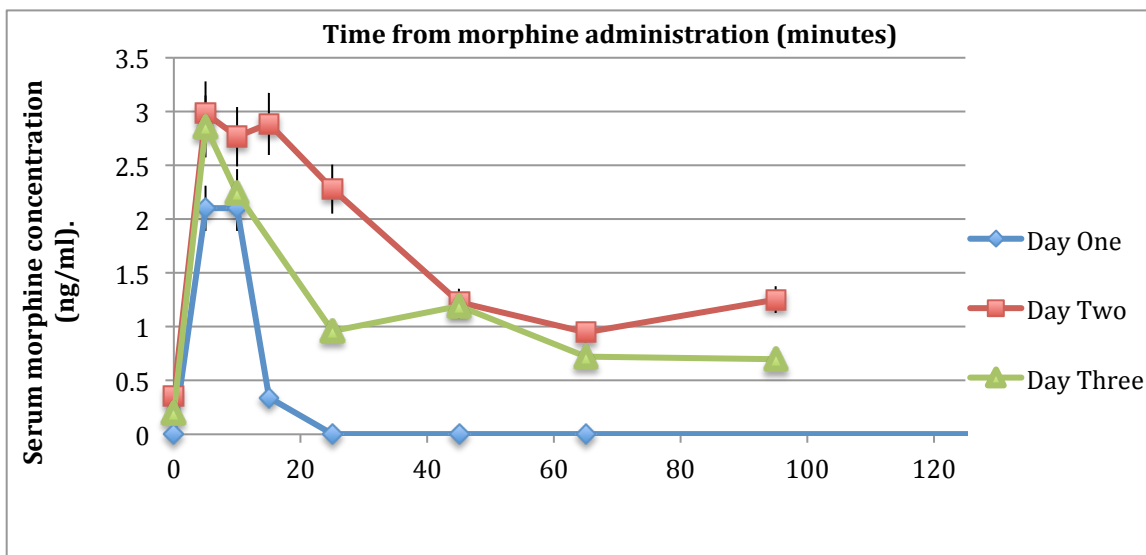


Figure 4. Systemic morphine concentrations after topical ocular administration:

Plot of averaged data for six horses. Error bars represent 90% confidence intervals.

Graphs below show individual horse data for systemic absorption for each of three days.

This is intended to show between horse variation. All data points from horse two were zero, therefore a graph is not included from this horse. Graphs were cut off at 125 minutes as all results for later time points were zero, and this allowed more accurate visualization of earlier data.

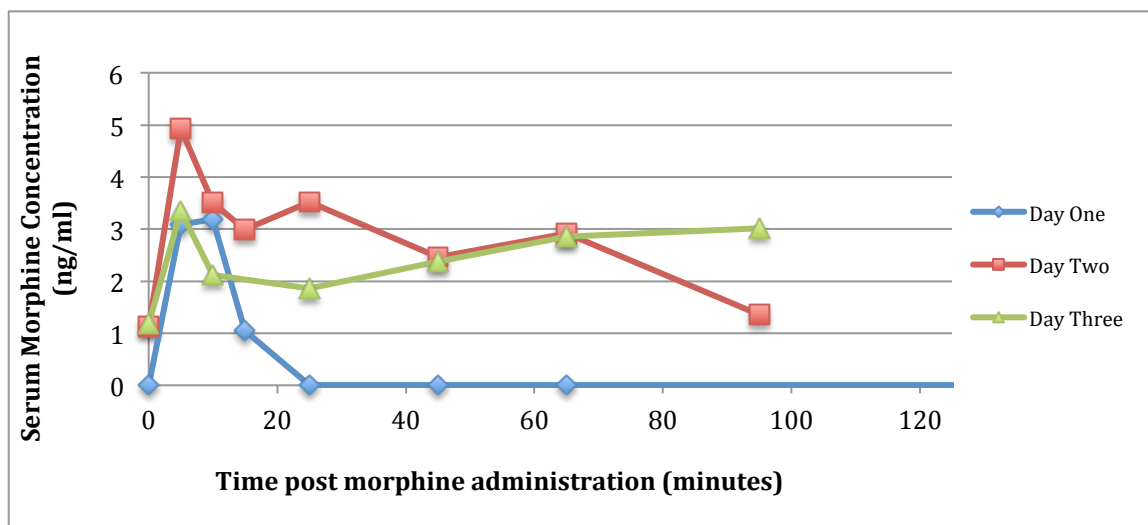


Figure 5. Systemic morphine absorption for horse one.

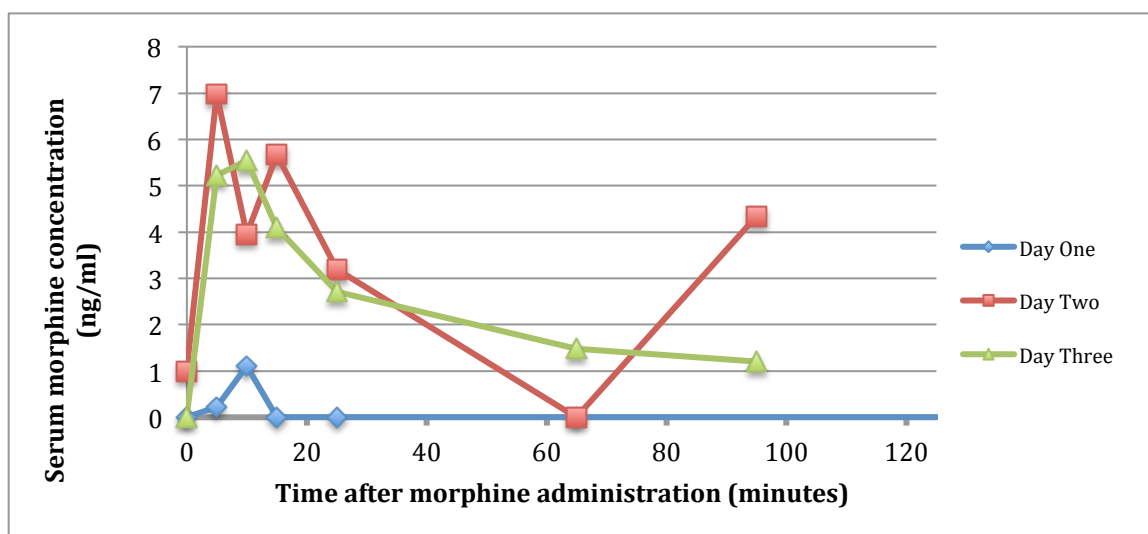


Figure 6. Systemic morphine absorption for horse three

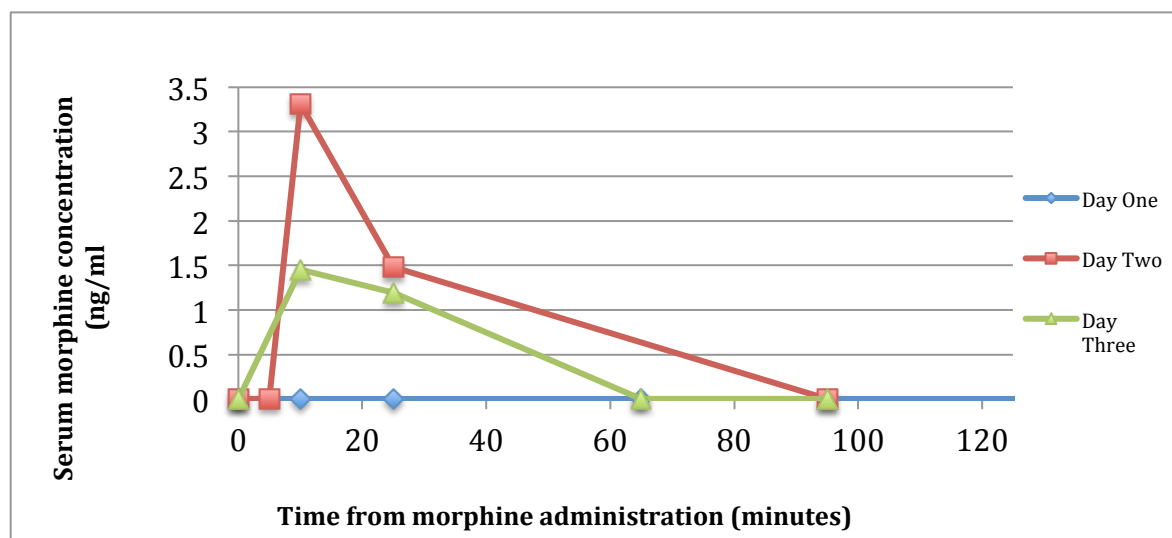


Figure 7. Systemic morphine absorption for horse four.

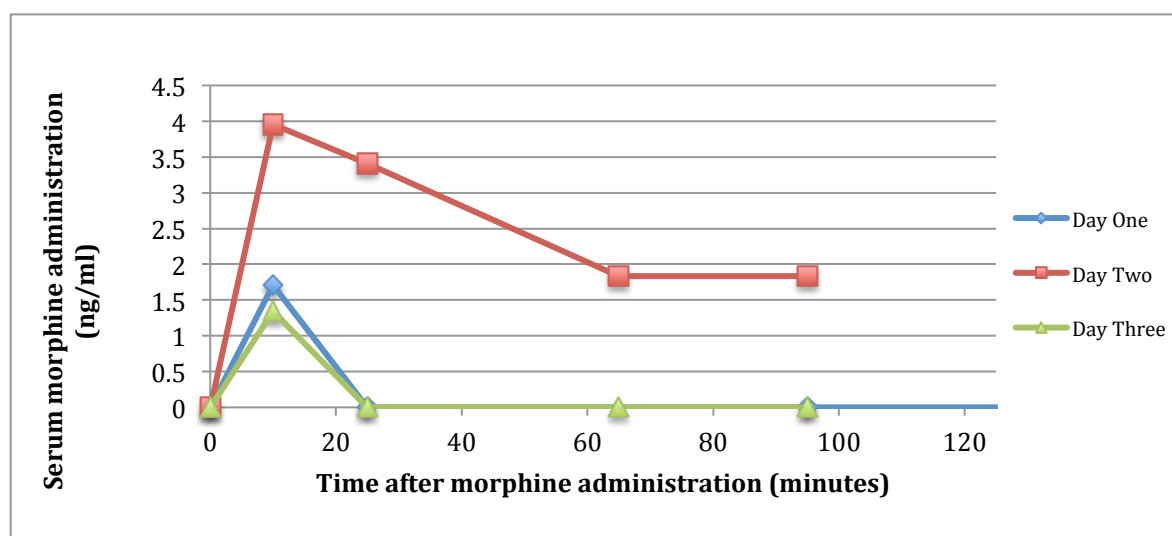


Figure 8. Systemic morphine absorption for horse six.

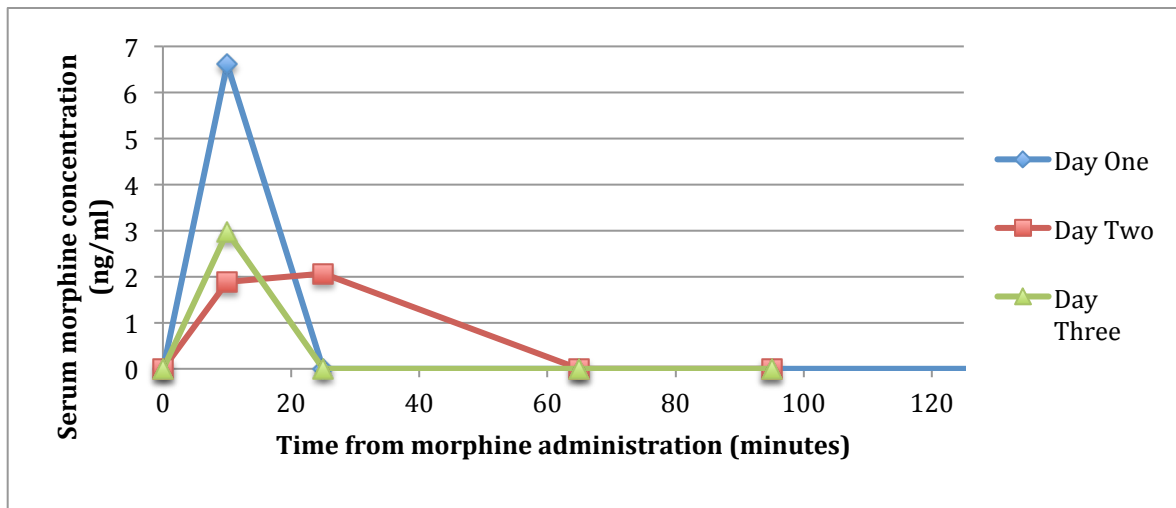


Figure 9. Systemic Morphine Absorption for horse seven.

4.5 Excluded Study Participant

The 5th horse that underwent the study protocol was excluded following abnormal corneal histology in both the treated and control cornea. This horse was an 18-year old Quarter Horse gelding and no medical history was available at the time the horse was donated, other than he was donated due to chronic lameness. Physical examination was normal. Ophthalmic examination detected a small, circular, very faint clouding on the dorsal aspect of both the left and right corneas, however the remainder of the ophthalmic examination was normal. The lesion was suspected to be a historical healed ulcer and the decision was made to include the horse in the study. The horse completed the study normally, however histological examination of the untreated control cornea found it to be significantly abnormal with mild lympho-plasmacytic keratitis consistent with equine recurrent uveitis. The same was found in the cornea from the treated eye. As this horse

did not have a normal control cornea, all data from this horse was removed from analysis.

See Figure 10.




Figure 10. H&E stained histology images at 4x magnification. Comparison of normal and affected cornea. The lympho-plasmacytic infiltrate can clearly be seen in the abnormal cornea as a blue coloration immediately below the corneal epithelium. This is not present on the normal control cornea. Images were taken on different light microscopes.

The histopathology report is as follows:

Overall Impression: Both corneas have a mild, peripheral, lymphoplasmacytic keratitis, accompanied by mild conjunctivitis.

Left cornea: There is a prominent accumulation of mixed lymphocytes and plasma cells, along with a few histiocytes, in the sub conjunctival fibrovascular connective tissue of the sclera, peripheral to the cornea. This inflammatory infiltrate extends uninterrupted into

the cornea, consisting primarily of lymphocytes and plasma cells, with a rare neutrophil. The majority of the inflammatory response lies within the corneal stroma, beneath Bowman's membrane. A few clusters of the mixed inflammatory cells extend into the epithelium in a few areas. The inflammation extends approximately to the level of the rim of the iris.

Right cornea: An inflammatory response extends into the sub epithelial stroma of the right cornea, similar to that in the left. It is composed of mixed lymphocytes and plasma cells. It is less intense than in the left cornea, and extends minimally into the cornea.

4.6 Discussion

In the study presented here, 1.0% morphine sulfate was shown to be safe in this population of healthy horses for short-term topical ophthalmic use. The treatments were well tolerated by all horses with no systemic effects detectable on repeated physical examinations with the exception of horse six. Histologically, no evidence of lesions in any component of the corneas was identified in treated eyes. All horses developed mild to moderate mucoid ocular discharge in the treated eye. In the absence of treating the control eye with the LiquiTears diluent, it is impossible to determine whether the mucoid discharge occurred in response to application of LiquiTears, application of morphine sulfate, secondary to presence of an SPL, or simply occurred in response to repeated instillation of a foreign substance regardless of its composition. We did not buffer the 1% morphine sulfate solution as has previously been done in other studies (Stiles 2003). Although our final pH of 6.3 is in keeping with commercially available ophthalmic antibiotic solutions, the pH may have contributed to the mucoid ocular discharge. The

two horses that developed infections around the SPL insertion site also had the most significant ocular discharge. Ocular discharge in these two horses significantly decreased upon removal of the SPL (one horse) and resolution of the SPL infection and associated upper lid swelling after treatment with topical ice pack application (one horse). Horse six developed significantly elevated rectal temperatures on the last day of the study. This coincided with development of a significant SPL site infection and significant upper lid swelling with purulent discharge from the SPL insertion site. While this is the likely source of the fever, morphine administration has been associated with elevation in body temperature (Weed 2006).

Morphine, as well as other opiates, affect thermoregulation, which appears to be separate from effects of morphine induced locomotor activity on body temperature (Weed 2006). Thermoregulatory disruption does appear to be dose related (Weed 2006), however it is unknown if it occurs in horses. Figueiredo et al did not detect a change in rectal temperature in horses treated with morphine at doses of 0.05 and 0.1 mg/kg, nor did Devine et al. at a dose of 0.1mg/kg (Figueiredo 2012, Devine 2013). Morphine effects on intraocular pressure (IOP) in horses have not previously been investigated (Robertson 2004). A combination of acepromazine and butorphanol did not effect intra-ocular pressure in canids (Robertson 2004). Intravenous xylazine in horses causes a significant decrease in IOP and does not appear to be strictly dose dependent (Robertson 2004). Intraocular pressures were measured daily and although there was significant variation in day to day pressure measurements, there was no statistical effect of morphine administration, suggesting changes in IOP measurements were due to other factors such

as head position or stress induced hypertension (Robertson 2004).

Morphine was absorbed into the aqueous humor reaching quite significant concentrations, although there was a notable amount of variation between horses. To the author's knowledge, it is unknown what concentration of morphine is necessary to provide analgesia. In human medicine, Klepstad et al found the range of effective plasma concentrations was 8.58 to 34ng/ml for the 25th to 75th percentile respectively (Klepstad 2003). A separate study by Dahlstrom et al. using patient controlled morphine for analgesia in humans found effective plasma morphine concentrations with a mean \pm standard deviation of 16 ± 9 ng/ml (Dahlstrom 1982). If this value was to be applied to equine medicine, it potentially could be assumed that therapeutic levels were reached in the aqueous humor of all treated eyes. Apparent therapeutic concentrations were not reliably achieved in vitreous humor, with significantly lesser concentrations obtained than in aqueous humor. Therefore, in addition to potential use of topical morphine for corneal analgesia, it may also prove to provide analgesia in diseases affecting the anterior chamber such as Equine Recurrent Uveitis.

Aqueous absorption of morphine has not been previously measured to the authors knowledge. Corneal permeability is the most important determining factor to the drug concentration that is reached inside the eye (Sasaki 1996). A large portion of instilled drug is eliminated via the conjunctival and scleral pathway into systemic circulation (Sasaki 1996, Kaur 2004). The conjunctival and scleral route can also deliver drug to the aqueous chamber in addition to the corneal diffusion (Schoenwald 1997). The

predominance for each of these pathways in delivering drug to the anterior chamber appears to be drug dependent (Schoenwald 1997). In humans, the majority of an instilled drug will be eliminated from the precorneal area within 90 seconds, although this is influenced by tear turnover rate and blinking (Sasaki 1996). It is estimated that 1% or less of instilled medication is ocularly absorbed (Kaur 2004).

The corneal epithelium, composed of tightly fitted squamous cells contribute the greatest resistance to drug penetration (Burstein 1985, Sasaki 1996, Kaur 2004). Drug penetration through the lipophilic cornea is also largely dependent on the pH of the solution and molecular weight of the substance (Lee 1986, Sasaki 1996). Lipophilic drugs are more readily absorbed (Sasaki 1996). When corneal epithelium is not intact, corneal permeability increases greatly, especially for hydrophilic drugs (Lee 1986, Sasaki 1996). This may have important implications for aqueous absorption of morphine in horses with corneal ulcers, as these corneas will be more permeable and therefore may absorb significantly more morphine. It is also unknown how long morphine can be expected to remain within the aqueous or vitreous humor. The cornea can act as a sustained release device because it can become saturated with a lipophilic following topical application and then release drug slowly into the aqueous humor (Burstein 1985). Absorption of drug across the cornea will also be affected by the characteristics of other concurrently administered ocular medications. It is common in equine veterinary medicine to treat ocular disease with frequent application of multiple medications. Calcium ethylenediaminetetraacetic acid (EDTA) for example, affects corneal penetration and can enhance drug uptake (Sasaki 1996, Kaur 2004).

Increasing viscosity of a formulation can increase contact time of the medication with the cornea, and thus potentially lead to increased ocular absorption (Burstein 1985). The fluoroquinolones ciprofloxacin and moxifloxacin reach therapeutic concentrations in horses in both tears and corneal tissue, but not in aqueous humor when intact corneal epithelium is present. Varying results have been obtained with a similar study in humans and dogs. Differences may reflect study protocol differences, but could also be an example of differing absorption with species differences in corneal thickness, anterior chamber volume and tear turnover rate (Westermeyer 2011).

Few studies have been performed in veterinary species to analyze absorption of topical ophthalmic medications into aqueous, vitreous and systemic circulation. Distribution of verapamil in the eye and systemic circulation of rabbits has been assessed with results that are in keeping with this study. They observed the highest peak concentrations in aqueous, followed by vitreous and serum (Siegener 1998). Peak concentrations were achieved more rapidly in aqueous and serum samples than in vitreous samples (Siegener 1998). Time to peak morphine values was not assessed in this study. Peak concentrations were higher when a greater percentage solution of verapamil was applied to the eye and it is likely the same would occur with morphine application. Other drugs have been found to distribute rapidly and reach similar concentrations in aqueous, iris and ciliary body but with lesser values in the vitreous (Siegener 1998). Some of these studies found the vitreous to have a longer elimination half life compared to aqueous or serum, which may arise from pooling in the vitreous from the anterior

chamber, systemic circulation, or from continuous release from intraocular tissues such as retina or choroid (Siegener 1998). The uveal tract influences drug metabolism and bioavailability by drug binding to pigments (Lee 1986). This metabolism and binding process is saturable, and the rate that drug is released and absorbed can markedly affect the concentration of drug inside the eye (Lee 1986). Elimination of drug from the aqueous humor primarily occurs with aqueous humor turnover (Sasaki 1996). In humans, aqueous humor has been reported to turnover at a rate of 1-1.5% of chamber volume every minute. In addition to clearance by turnover, drug metabolism and systemic uptake will cause decline of aqueous concentrations (Sasaki 1996).

Absorption of morphine into systemic circulation following topical application has not previously been evaluated in horses. Morphine was detected in serum of five out of six horses, although there was significant variation between horses. In some horses, morphine was only detectable at a few time points, whereas in others it was consistently detected at numerous time points. It is unknown why morphine was not detected in serum from horse two at any time point. In general terms, topical morphine sulfate applied to the eye every four hours, can be expected to result in measurable systemic absorption, with peak systemic concentrations occurring approximately five-ten minutes after administration. In addition, morphine concentrations above 1.0 ng/ml (lower limit of assay detection), were more consistently detected on days two and three, than day one of administration. It is possible that repeated application of morphine may result in accumulation over time, similar to that demonstrated with oral tramadol administration in horses. Tramadol was found to accumulate considerably over time, although more so

when given at the higher doses (Guedes 2013).

The peak level of systemic morphine reached is unlikely to have analgesic effects systemically. As discussed, in human medicine, effective plasma concentrations have been found to be 8.58 to 34 ng/ml in one study and 16 ± 9 ng/ml in a second study (Dahlstrom 1982, Klepstad 2003). Comparable studies have not been performed in horses. The lower limit of 7ng/ml in Dahlstroms study was almost achieved in this study, but it is unlikely that this will provide systemic analgesia (Dahlstrom 1982). The plasma concentration necessary to cause adverse systemic effects in horses have not been determined although the levels achieved in this study did not cause side effects of decreased gut sounds, decreased manure production, or increased locomotor activity. These effects appear to be dose dependent (Figueiredo 2012). Figueiredo et al reported a decrease in abdominal auscultation scores or borborygmus frequency when plasma morphine concentrations were between four and eight ng/ml. Therefore it is conceivable that the systemic levels reached in this study could potentially cause gastrointestinal side effects (Figueiredo 2012). Systemic absorption of atropine following topical ophthalmic administration has been evaluated in horses (Williams 2000). Williams et al found decreased gastrointestinal sounds in all experimental horses and signs of abdominal pain occurred in four out of six horses. This suggests significant systemic absorption can occur after ophthalmic administration and is in keeping with results of this study. Topical administration of verapamil in rabbits has also been evaluated (Siegnier 1998). Similar to this morphine study, peak concentrations of verapamil were found to be highest in aqueous humor, followed by vitreous humor and finally serum. Significant metabolism to

norverapamil also occurred following hepatic metabolism in systemic circulation (Siegener 1998).

Previous reports have shown that some topical ophthalmic medications can be systemically absorbed to the extent that the non treated eye can contain measurable levels of the medication (Lee 1986). This was not observed, as the non-treated eye was negative for morphine in both the aqueous and vitreous in six horses. This is important to note considering the untreated eye was used as a normal control in this study. Whether this would hold true when uveitis is present and therefore the blood-aqueous barrier is disrupted, is unknown. To the author's knowledge, systemic absorption of morphine following ocular administration has only been previously evaluated in rabbits (Chast 1991). After ocular administration, morphine was found to rapidly reach high blood levels compatible with pharmacological activity. The dose administered was extremely high in comparison to clinical use at 1.0mg/kg. Ocular bioavailability of morphine was found to be 44% of the administered dose (Chast 1991). With no intravenous administration in our study, bioavailability could not be calculated.

There are limitations to this study, the primary one being the small number of horses that participated. With significant inter-horse variation, including one outlier that did not have measureable morphine in the serum at any time point, a larger study would remove bias due to that small number of test animals. The observer performing the physical and ocular examinations was aware of the treatment performed, as well as which

eye was the treated and control eye which may have influenced their clinical evaluations. In addition, the study was performed in healthy horses with an intact blood-aqueous barrier and it is therefore difficult to speculate what level of ocular compared to systemic absorption may occur in the presence of uveitis or other inflammation. Differences in absorption when other medications are co-administered are also likely. Another limitation is only morphine itself was identified by ELISA. Identification of the primary morphine metabolites 3-morphine-glucuronide and 6-morphine-glucuronide, both of which are considered to be pharmacologically active, can also be measured in future work to better understand ophthalmic pharmacokinetics (Knych 2013). High performance liquid chromatography is the preferred quantification method for compounds in a liquid but was unavailable due to cost.

In conclusion, ocular administration of morphine sulfate on the healthy equine eye was determined to be safe for short-term use. Topical application results in appreciable absorption into the aqueous chamber with minimal absorption into the vitreous chamber and systemic circulation. Further studies need to be performed in a greater number of horses and in horses with naturally occurring ophthalmic disease. Further evaluation for corneal epithelial damage could include exposure of corneal cells to morphine in cell culture.

5.0 Evaluation of Corneal Analgesia After Application of 1% Morphine Sulfate by use of Aesthesiometry in Normal Horses

5.1 Introduction

The cornea is one of the most densely innervated tissues in the body, with a neuronal density that is 300-600 times that of skin epithelium (Rozsa 1982, Brooks 2000). For this reason, damage to corneal epithelium can be exquisitely painful. Horses, with their flighty nature, and laterally located protruding eyeball location, are very prone to corneal damage, in particular corneal ulcers. Sensory innervation originates from the ophthalmic branch of the trigeminal nerve (Brooks 2000, Gilger 2011). The equine cornea has been shown to be most sensitive in the center and least sensitive in the periphery (M.Millodot 1973, Brooks 2000). Corneal sensitivity has been shown to be greater in younger horses than older horses (Miller 2013). Horses with pituitary pars intermedia dysfunction also have significantly decreased corneal sensitivity, leaving them at risk of non-healing or recurrent ulcers (Miller 2013).

Corneal sensitivity can be assessed by using a aesthesiometer, the most commonly used is the Cochet-Bonnet aesthesiometer (Brooks 2000). This hand-held aesthesiometer has a tiny diameter nylon filament of adjustable length. Pressure applied to the cornea via this filament elicits a blink reflex when the corneal touch threshold (CTT) sufficient to stimulate corneal sensory nerve endings is reached (Brooks 2000, Kaps 2003).

Horses in pain with ophthalmic disease show signs including decreased appetite, elevated heart rate, decreased interest in environment, dullness and a low head carriage (Robertson 2010, Gleerup 2016). Subtle changes in facial expressions have also recently

been associated with pain in horses (Gleerup 2014). Pain medications currently available for use in horses with ophthalmic disease include systemic medications such as steroidal and non-steroidal anti-inflammatory drugs, opioid, alpha-2 agonists, ketamine and gabapentin (Muir 2010, Sanchez 2014). All come with potential side effects such as renal and gastrointestinal mucosal damage with NSAID use (Sanchez 2014). Topical pain medications currently used in horses involve local anesthetics and topical NSAIDs. Topical anesthetics are only suitable for intermittent diagnostic use due to corneal epithelial toxicity (Marr 1957, Carney 1984, Plumb 2011). Topical NSAIDs have been associated with delayed healing and epithelial toxicity and are therefore contraindicated when corneal ulceration is present (Shimazaki 1995, Guidera 2000, Robertson 2004, Plumb 2011). Due to potential side effects of current medications, and the fact that many horses being treated with maximum doses of pain medications still experience significant discomfort, alternative ocular pain relieving medications are needed.

Topical nalbuphine has been investigated in horses and rabbits without significant systemic side effects, but it did not provide sufficient analgesia (Wotman 2010, Clark 2011, Silva 2012). Topical nalbuphine in canids found mixed results (Aquino 2005, Clark 2011). Topical fentanyl in humans also did not provide measurable analgesia (Zollner 2008). Topical morphine has been used experimentally in rabbits, people, rats and dogs (Stiles 2003, Wenk 2003, Faktorovich 2010, Robertson 2010). Solutions of 0.5% morphine following corneal surgery in humans was safe and reduced post-operative pain (Faktorovich 2010). In rabbits it has been shown to not delay healing of corneal ulcers, in contrast to proparacaine (Peyman 1994). In this study, morphine was found to be

analgesic when corneal disease was present, but not when the corneal epithelium was intact (Peyman 1994).

In dogs with experimentally induced corneal ulcers, those treated with morphine showed reduced blepharospasm and lower aesthesiometer scores than control dogs, without affecting healing time (Stiles 2003). In contrast, Thomson et al. evaluated topical 1% morphine in dogs and cats with clinical ophthalmic disease and found no analgesic effects. In rabbits following lamellar keratectomy, morphine provided analgesia without delaying healing (Ribeiro 2012). Overall, of the topical medications attempted to date, morphine appears to hold the most promise for corneal analgesia. To the author's knowledge, this is the first study assessing the use of topical morphine in horses.

The purpose of this study was to evaluate whether topically applied 1% morphine sulfate would change the corneal touch threshold compared to a control solution as measured by a Cochet-Bonnet aesthesiometer. Secondly, this study also aimed to identify the duration of action of a single application in order to guide recommended dosing intervals.

5.2 Materials and Methods

5.2.1 Animals and Treatments

The Oregon State University Animal Care and Use Committee (IACUC) (ACUP # 4773) approved all animal procedures. Eight horses from Oregon State University Veterinary Teaching Hospitals teaching herd were enrolled in the study.

Prior to inclusion, each horse was subjected to a full physical examination followed by full ophthalmic examination of both eyes to ensure the horse was healthy with normal ocular health and function. The ophthalmic examination included assessment of reflexes (dazzle, palpebral and presence of direct and indirect pupillary light reflexes) as well as evaluation of the menace response. The gross appearance of the eye was evaluated using a Finhoff trans illuminator, followed by slit-lamp biomicroscopy of the cornea and anterior chamber. Indirect ophthalmoscopy was utilized to evaluate the fundus, without application of mydriatic agents in case of medication interference with study results. The Schirmer tear test¹ was applied, followed by fluorescein² staining to evaluate corneal epithelial integrity.

A normal physical examination and two normal eyes made a horse eligible for study inclusion. The study was conducted without sedation or perineural anesthesia. The study group consisted of eight mares ranging in age from 13 to 20 (Table six) with a mean age of 15.8 years. Included breeds consisted of Quarter Horse (3), thoroughbred

(1), Warm blood (1), Paint (2) and crossbred (1).

5.2.2 Measurement of Corneal Sensitivity

Corneal touch threshold (CTT) was measured for one randomly selected eye of each horse (4 right eyes, 4 left eyes) by use of the Cochet-Bonnet aesthesiometer²⁹. This aesthesiometer contains a thin nylon filament measuring 0.12 mm (0.0113mm²) in section. The length of the filament was adjustable from 5mm to 60mm. The filament was applied centrally to the cornea to determine corneal sensitivity. The center of the cornea has been shown to be the most sensitive area in multiple species. (M.Millodot 1973, Chan-Ling 1989, Brooks 2000, Gilger 2011). The readings produced from the aesthesiometer in millimeters can be converted to a force measurement (Table five).

Briefly, the filament is first applied at 60mm (maximum length, minimum force) and then decreased by 5mm increments at a time until a positive response occurs indicating touch threshold has been reached. A positive response was considered to be a blink response that occurred three out of five touches with the aesthesiometer to ensure a single blink at time of filament application was not a coincidence, but truly indicative of corneal sensation.

Table Five Aesthesiometer pressure conversion as provided with the purchased aesthesiometer.

Nylon Length in mm	60	55	50	45	40	35	30	25	20	15	10	5
Pressure in mg/S	5	5.5	6	8	9.5	11.5	15.5	20.5	31.5	58	116	180
Pressure in g/mm ²	0.4	0.5	0.55	0.7	0.8	1	1.4	1.8	2.8	5.1	10.3	15.9

5.2.3 Treatment (Morphine) and Control (LiquiTears) Application

Immediately following baseline CTT measurement, 0.3ml of 1.0% preservative free morphine sulfate¹⁶ was applied to the treated eye by way of a 25-gauge needle broken off at the hub to allow liquid to be instilled into the horses eye. This is equivalent to 3.0 mg of morphine. A volume of 0.3ml of solution is slightly greater in volume that is typically used in our referral veterinary medical teaching hospital (0.2ml). Clinical patients typically have a sub-palpebral lavage in place to ensure accurate and complete delivery of a medication directly to the cornea. Room for delivery error is greater without the use of the lavage system, which is why medication volume was increased slightly.

Immediately after morphine sulfate was applied to the selected treated eye, an equivalent volume (0.3ml) of LiquiTears¹⁷ solution was applied to the control eye by an identical technique. LiquiTears was used to dilute the 2.5% commercial morphine product¹⁶ to the 1.0% solution used for this study. Time of morphine¹⁶ or LiquiTears¹⁷ application was considered time 0. The treated eye was randomly assigned by a computer program (www.random.org/lists). The same person performed all CTT measurements to minimize inter-observer variation. This person was blinded to what eye was treated compared to control until all data had been collected.

Corneal touch threshold was then measured as previously described at one minute after medication application, followed by every 5 minutes until 60 minutes post administration. If the corneal touch threshold had not returned to baseline by 60 minutes measurements were continued at 15 minute intervals until corneal sensitivity returned to

baseline CTT measurement up to 180 minutes post administration if needed. The control eye was treated identically and measurements continued in the control eye until the treated eye sensitivity returned to baseline CTT.

Following completion of CTT measurements bilaterally, fluorescein stain² and evaluation with a cobalt blue filter was repeated to ensure no corneal epithelial damage occurred during the study.

Subject #	Age (years)	Breed	Sex	Coat Color	Treated Eye	Control Eye
1	13	Paint	Mare	Chestnut	Right	Left
2	15	Paint	Mare	Palomino	Right	Left
3	16	QH	Mare	Chestnut	Right	Left
4	20	QH	Mare	Chestnut	Left	Right
5	15	Warmblood	Mare	Chestnut	Left	Right
6	17	QH	Mare	Grey	Right	Left
7	14	TB	Mare	Bay	Left	Right
8	17	Cross	Mare	Bay	Left	Right

Table six. Characteristics of horses enrolled in the corneal sensitivity study.

5.3 Statistical Analysis

Data from CTT measurements were non-normally distributed but did have equal variance. The CTT data were analyzed by use of Two Way Repeated Measures ANOVA using a general linear model. Data were analyzed for effects of treatment administered, measurement time point, and to assess differences between baseline CTT values and those measured at each subsequent time point. Analysis was performed using commercial statistical software SigmaStat²⁷ with α set at 0.05. Significance was set at a value of $P \leq 0.05$. Microsoft Excel²⁸ was used for graphical representation.

5.4 Results

Values of CTT were obtained for eight morphine treated eyes and eight control eyes in the study horses at baseline (time 0) and at 1, 5, 10, 15, 20, 25, 30, 35, 40, 45, 50, 55 and 60 minutes after solution administration. All but three horses were considered to be at baseline values at 60 minutes therefore further time points collected in those three horses included a 75 minute reading in 3 horses and 90 minute reading in one horse. These time points past 60 minutes were eventually excluded from the final model for uniformity. Horse five was non-compliant at the 45-minute time point, resulting in inability to collect this sample. Values were collected successfully for all horses at every other time point. The statistical model²⁷ rejected data from horse number two, therefore data from only seven horses was included in data analysis.

Mean baseline CTT of both the control eye and treated eye was 21.8mm with an identical range of 15mm to 30mm ($p=1.0$ using t-Test). Corneal touch threshold was not

significantly different between morphine treated and control eyes at any time point ($p=0.21$). This is demonstrated in Figure 11. Although some readings were lower than baseline, there was no overall morphine treatment effect ($p=0.39$). The most significant finding was that individual horses varied in their response pattern but this was not statistically significant ($P=0.051$). This was not related to time point of treatment administered. The apparently random deviation from baseline corneal touch thresholds is demonstrated in figures 12a-g. This is demonstrated in Figures 12a-g. Each graph represents data points for one individual horse, clearly showing the unpredictability of each time point. None of the horses developed signs of ocular discomfort or corneal epithelial damage as a consequence of CTT testing, as determined by fluorescein staining and direct ophthalmoscopy.

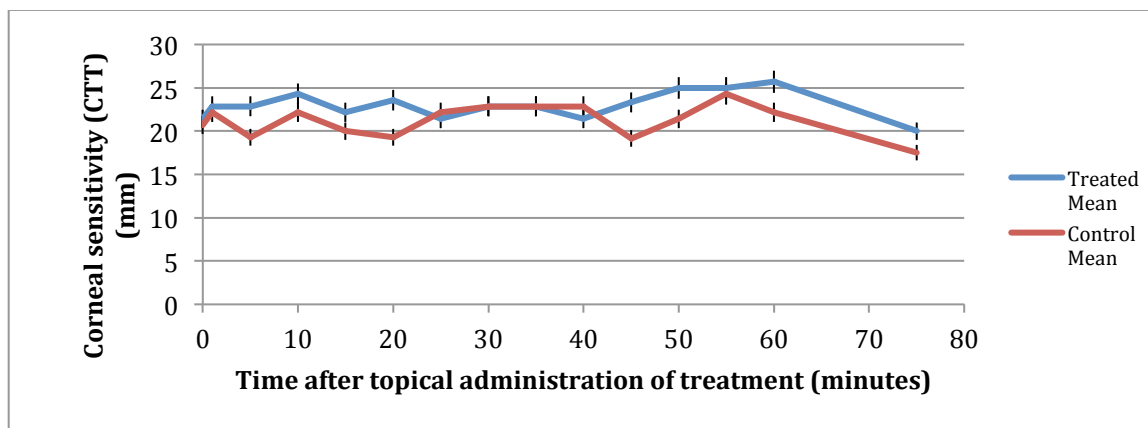


Figure 11. Corneal touch threshold measurements after topical administration of 1.0% Morphine Sulfate ophthalmic solution. Aesthesiometer filament length were used to determine CTT in seven horses before (time 0) and after topical administration of 0.3ml of 1.0% morphine¹⁶ (treated) or LiquiTears¹⁷ (control). Data points represent mean CTT (mms) and error bars are +/- 95% confidence interval.

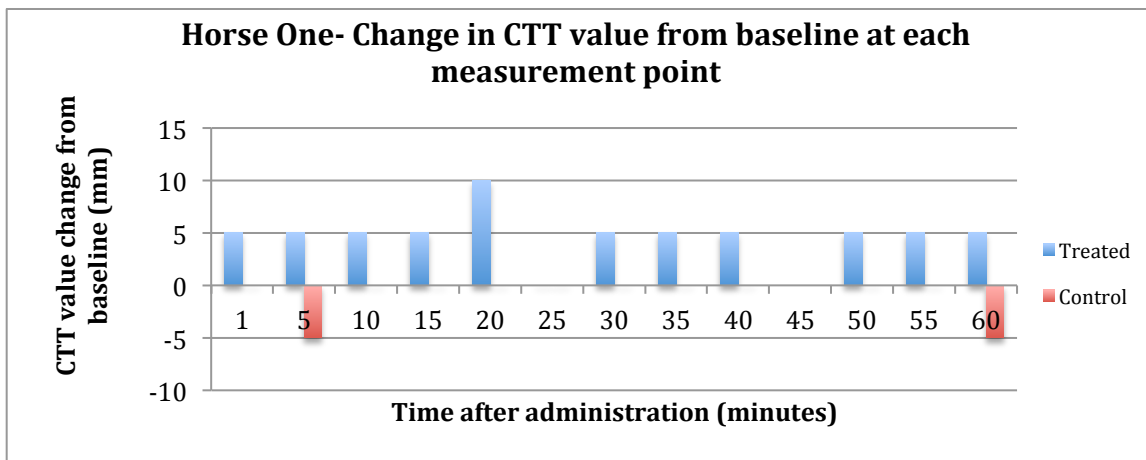


Figure 12a. Figure showing how corneal touch thresholds for horse one deviated from the baseline reading at time 0. Time points with no bar indicate the measurement at that time point was equal to the baseline value and therefore the change from baseline was zero.

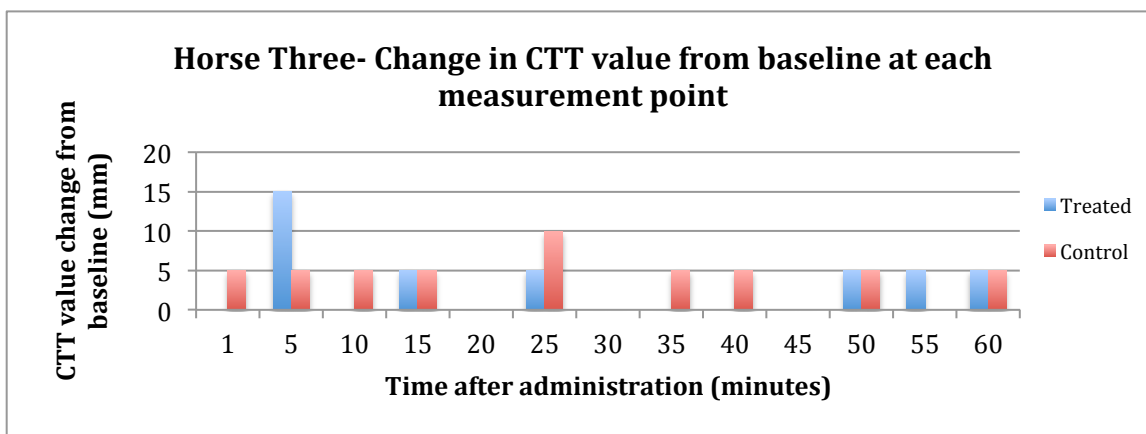


Figure 12b. Figure showing how corneal touch thresholds for horse three deviated from the baseline reading at time 0. Time points with no bar indicate the measurement at that time point was equal to the baseline value and therefore the change from baseline was zero.

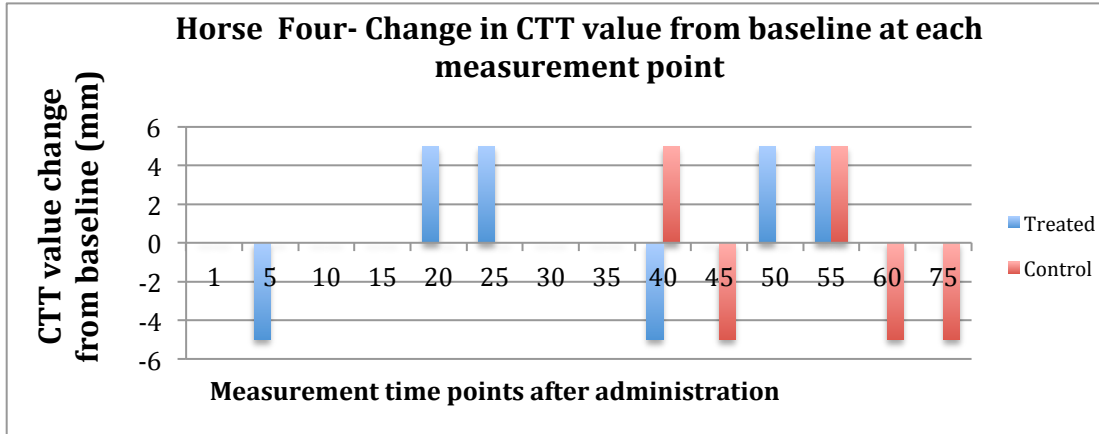


Figure 12c. Figure showing how corneal touch thresholds for horse four deviated from the baseline reading at time 0. Time points with no bar indicate the measurement at that time point was equal to the baseline value and therefore the change from baseline was zero.

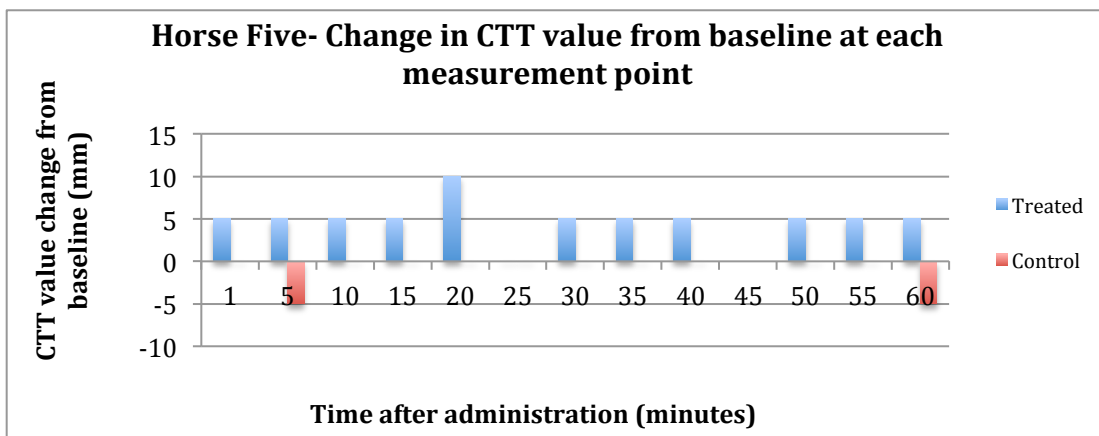


Figure 12d. Figure showing how corneal touch thresholds for horse five deviated from the baseline reading at time 0. Time points with no bar indicate the measurement at that time point was equal to the baseline value and therefore the change from baseline was zero.

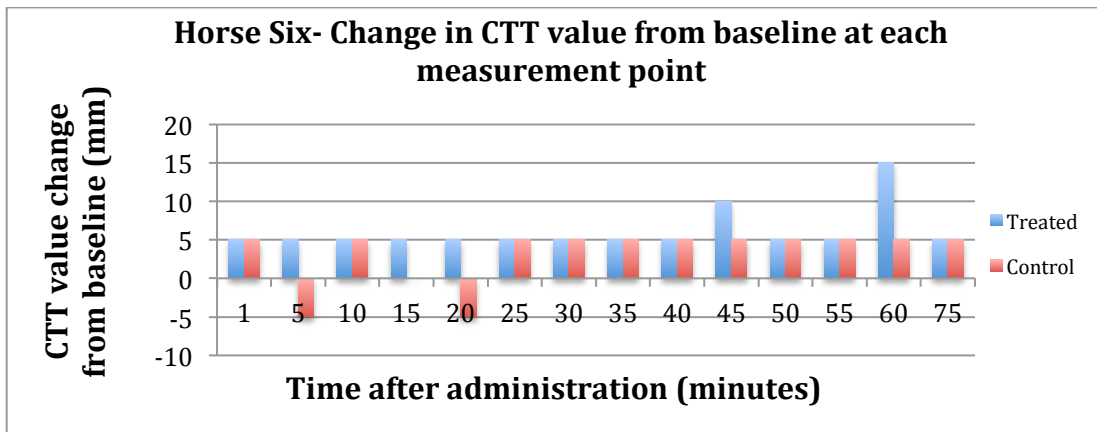


Figure 12e. Figure showing how corneal touch thresholds for horse six deviated from the baseline reading at time 0. Time points with no bar indicate the measurement at that time point was equal to the baseline value and therefore the change from baseline was zero.

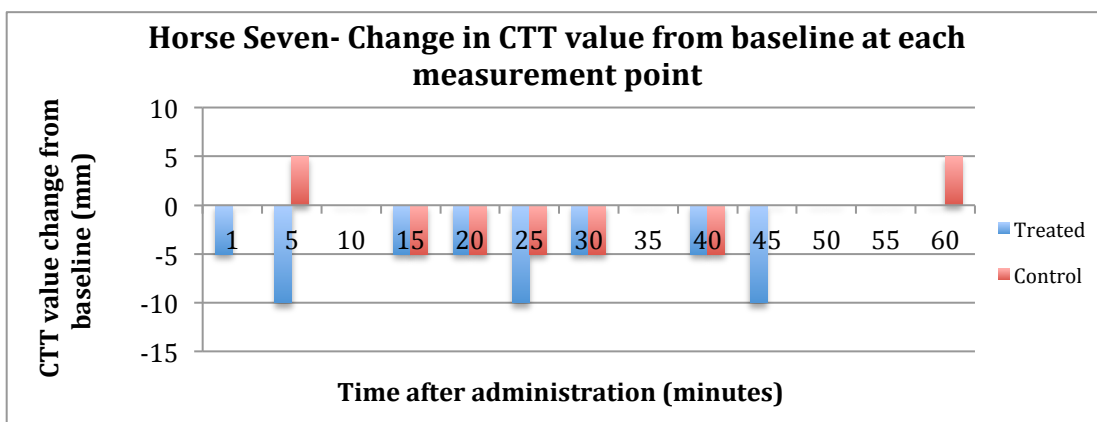


Figure 12f. Figure showing how corneal touch thresholds for horse seven deviated from the baseline reading at time 0. Time points with no bar indicate the measurement at that time point was equal to the baseline value and therefore the change from baseline was zero.

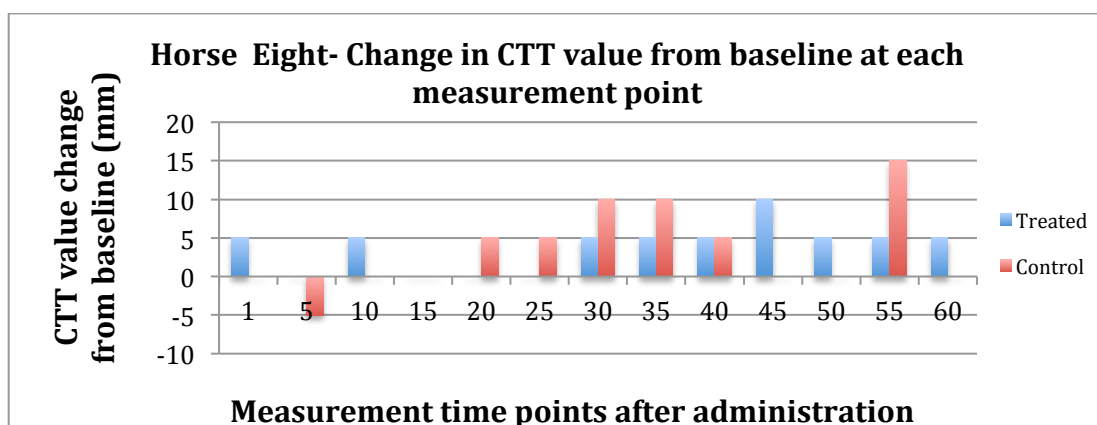


Figure 12g. Figure showing how corneal touch thresholds for horse eight deviated from the baseline reading at time 0. Time points with no bar indicate the measurement at that time point was equal to the baseline value and therefore the change from baseline was zero.

5.5 DISCUSSION

The results from this study are a first step to study topical analgesic options for horses with ocular pain as current options are limited or associated with significant systemic side effects (Marr 1957, Carney 1984, Muir 2010, Sanchez 2014). In this study, baseline corneal sensitivity was lower (21.8mm) than in studies performed by Brooks (Brooks 2000) (48.2mm) and Kalf (Kalf 2008) (48mm). However, our values were comparable to Kaps et al (Kaps 2003) who reported a mean baseline value of 21.15mm in the central region of the cornea. This central region is considered to be the most sensitive area of the equine cornea, which is why measurements were taken from this region in the study reported here (Brooks 2000, Kaps 2003).

Horses showed significant variation in their responses to CTT testing, with no significant relationship between treatment administered and corneal sensitivity as shown in Figure 11. Corneal sensitivity appeared to be variable from baseline randomly. It is unlikely morphine application made the cornea more sensitive as might be suggested by an increasing CTT (increasing filament length and corresponding decrease in pressure applied to the cornea). Increasing sensitivity might occur if corneal damage or inflammation is induced, however there was no evidence for this. Although some readings were lower than baseline, suggesting corneal sensitivity may be decreased from that at baseline at several time points, there was no treatment effect suggesting this difference is due to random sampling variability and not due to treatment effect. Overall, mean CTT values essentially did not differ between treated and control eyes, and minimally changed from baseline, suggesting that in this study group, corneal sensitivity is not reduced by topical 1.0% morphine sulfate application in healthy horses. As morphine is an analgesic, as opposed to an anesthetic, it may be that use of an aesthesiometer to evaluate for changes in corneal sensitivity is an inappropriate method of analgesic assessment for topical opioids. Due to the small number of horses used in this pilot study, studies should potentially include greater participant numbers. It is also essential to assess morphine as an analgesic in horses with corneal disease. In general, studies assessing efficacy of peripherally applied opioids have produced variable results (Schramm 2010).

In dogs with experimentally induced corneal epithelial defects, topical morphine at the same concentration, produced both clinical evidence of analgesia as well as reduction

of CTT values as measured by an aesthesiometer (Stiles 2003). This was in contrast to Thomason et al. who demonstrated topical ocular morphine showed no measurable analgesic effect in clinically diseased dogs and cats (Thomson 2013). Topical 1.0% nalbuphine was shown to have no analgesic effect in healthy equine corneas (Wotman 2010). Variable results have been reported with nalbuphine in clinically normal dogs found to decrease corneal sensitivity for 30 minutes after administration (Aquino 2005). This difference could reflect differences in study procedures or could potentially relate to differences in opioid receptor distribution between species. Other canine nalbuphine studies have found no analgesic effect (Clark 2011). While few mu and greater numbers of delta receptors have been identified in canine corneas (Stiles 2003), this has yet to be published for equine corneas.

In canine corneas, mu receptors were infrequent and were primarily located in the stroma, whereas the more numerous delta receptors were located in stroma, sub-epithelial stroma and within corneal epithelium. In rat and monkey peripheral tissues, including cornea, delta opioid immunoreactivity appeared to be restricted to thin unmyelinated fibers and free nerve endings (Wenk 2003). The human cornea also contains both mu and delta opioid receptors (Zollner 2008). The function of delta receptors is at times still considered to be unclear, and from a behavior aspect, delta agonists typically produce weak analgesic effects (Ma 2006). Although morphine is a mixed mu and delta receptor agonist (Wenk 2003) it has a higher affinity for mu receptors, which is the main pathway by which it mediates its analgesic effect. However, at a high enough concentration, morphine will interact with delta and kappa receptors in addition to mu receptors (Kruger

2001). It is unknown whether the morphine administered is primarily interacting with the few mu receptors or the more numerous delta receptors and whether species differences in these receptor distributions may explain the discrepancies in results.

Up-regulation of opioid receptors, particularly mu receptors, with inflammation has been well documented at peripheral sites (Stein 1988, Stein 1988, Stiles 2003, van Loon 2013). Van Loon et al. demonstrated that acute inflammation will up-regulate mu receptors in synovium, but NSAID treatment will attenuate this response (van Loon 2013). Wenk et al. demonstrated that this effect is also seen in the rat cornea (Wenk 2003). Rats with inflamed eyes induce by cautery, responded to topical morphine with decreased pain signs. Yet when morphine was applied to the normal healthy cornea of these rats, it did not reduce pain sensation below baseline (Wenk 2003). Similarly, Peyman et al. showed morphine to be analgesic when applied to inflamed rabbit cornea, but not when applied to intact rabbit cornea (Peyman 1994). It has also been shown long-term morphine treatment actually induces presence of functional delta opioid receptors and accompanying delta opioid receptor mediated analgesia (Ma 2006). An additional benefit of topical morphine, is the potential for anti-inflammatory effects. Wenk et al. demonstrated that topically applied morphine decreased development of corneal inflammation and proposed this may be due to attenuation of the release of pro-inflammatory neuropeptides such as Substance P. Neutrophil infiltration in inflamed cornea was significantly reduced in eyes treated with topical morphine (Wenk 2003). This may potentially provide a benefit of using topical morphine regardless of whether analgesic effect is present.

Importantly, in the study performed by Stiles et al. no change in corneal sensitivity was found on the first day of morphine treatment and the reduction in corneal sensitivity was only identified in that study after 24 hours of 3 times daily morphine administration (Stiles 2003, Thomson 2013). In contrast, humans receiving one dose of topical morphine demonstrated a difference in corneal sensitivity (Peyman 1994). Therefore, this also may be species specific and further investigation is warranted.

Limitations of the study included difficulties in obtaining accurate corneal aesthesiometry readings. This occurred for several reasons but the most significant contributor was the numerous lengthy cilia in the periocular region. These cilia interfered with accurate placement of the aesthesiometer filament on the center of the cornea by catching on the filament. The cilia were also prone to being stimulated by the hand holding the aesthesiometer. This caused a blink response independent of the filament contacting the cornea. Ideally these could have been trimmed prior to study inclusion, but they are an important innate defense mechanism for horses to avoid ocular debris and trauma.

The filament length eliciting a blink reflex was also variable. Further complicating compliance by the study horses were noise distractions in the surrounding area of the study area. Measurements taken while a horse was distracted were then repeated in 20 seconds once the distraction had passed due to significant variability not thought to be a treatment effect. Every effort was made to be aware of this and to time measurement

data collection appropriately. Data collection from all horses was performed in the same area, using the same stocks to minimize environmental variation.

Evaluation of the blink response in the study horses was also open to observer interpretation. The same investigator performed all CTT measurements in an effort to minimize effect. Some horses would clearly blink in response to sensing a touch of the filament with a definitive tight closing of the lid. Others would blink repeatedly in quick succession. Harder to interpret were the horses that just performed a single normal blink. In order to be sure the correct threshold was recorded in these cases, the measurement was immediately repeated to ensure a blink occurred again at the same threshold. Several of the study participant horses began to anticipate the stimulus and would begin blinking as the device approached their face, making measurements impossible to obtain. In these horses, a second investigator was utilized to provide a minor distraction such as making a noise or waving a paper, such that ears pricked up and eyes opened, allowing a measurement to be obtained. The aesthesiometer appears to be a less than ideal tool for reliably measuring corneal sensitivity, however it remains the most practical and available and with careful use can produce reliable results. It delivers an imprecise stimulus application and this has led to development of the CRCERT-Belmonte aesthesiometer, which delivers a jet of air to the cornea (Golebiowski 2008).

Results of this study suggest that topical application of 1.0% morphine sulfate to the equine cornea may not provide analgesia in the healthy equine eye, when assessed by Cochet-Bonnet aesthesiometry. Further work to evaluate topical morphine as an analgesic

in diseased corneas needs to be undertaken as well as work to investigate effects of repeated dosing, potentially with use of a Belmonte aesthesiometer. It would also be valuable to assess a higher concentration of morphine sulfate such as 2%.

6.0 Conclusions

The study described here found that horses treated with short term topical ophthalmic morphine sulfate did not show adverse systemic or ocular side effects. Corneal histopathology confirmed there was no difference in microscopic appearance between morphine treated and control corneas. Morphine was detected by ELISA in aqueous and vitreous humor, with significantly greater concentrations in aqueous humor. Topical morphine can be expected to result in systemic absorption with peak systemic concentrations approximately 5-10 minutes after administration. Corneal touch thresholds were found to be not significantly different between morphine treated and control eyes at any time point, therefore topical ophthalmic 1.0% morphine does not provide and anesthetic effect on the intact cornea.

Further investigations should assess a possible analgesic effect of morphine on diseased equine corneas. The equine cornea should be examined for presence of opioid receptors as well as whether receptor up-regulation occurs in inflammation as has been demonstrated in other tissues. Identification of primary morphine metabolites 3-morphine-glucuronide and 6-morphine-glucuronide should also be measured in serum and possibly aqueous and vitreous humor to better understand ophthalmic pharmacokinetics. Future studies should also include a greater number of study participants.

Appendix 1

Footnotes

1. Schirmer Tear Test. Schering-Plough Animal Health (Merck). Kenilworth, New Jersey, USA.
2. Fluorescein sodium. Fluoret strip, Akorn Inc, Lake Forest, Illinois, USA.
3. TonoVET. Jorgensen Labs, Loveland, Colorado, USA.
4. Abbocath. Abbott, North Chicago, Illinois, USA.
5. Xylazine hydrochloride. AnaSed. Lloyd laboratories, Shenandoah, Iowa, USA.
6. Clippers. Lazor Clip, Oxnard, California, USA.
7. Betadine Scrub. Pivodine Scrub, VetOne (MWI), Boise, Idaho, USA.
8. Isopropyl alcohol 70%. Vedco, St Joseph, Missouri, USA.
9. Mepivacaine hydrochloride. Carbocaine-V. Zoetis inc, Kalamazoo, Michigan, USA.
10. Injection cap. Covidien, Mansfield, Massachusetts, USA.
11. Ethilon 2-0 suture. Johnson and Johnson, New Brunswick, New Jersey, USA.
12. Heparinized saline. Hospira, Lake Forest, Illinois, USA.
13. Sub-palpebral Lavage. Mila International, Florence, Kentucky, USA.
14. Proparacaine. Alcon Laboratories Inc. Fort Worth, Texas.
15. Betadine Solution. VetOne (MWI Animal Health), Boise, Idaho, USA.
16. Morphine Sulfate 25mg/ml preservative free. Hospira, Lake Forest, Illinois, USA.
17. LiquiTears. Major Pharmacauticals, Livonia, Michigan, USA.
18. Red Top vacutainer. Covidien, Mansfield, Massachusetts, USA.

19. Centrifuge. ThermoFisher Scientific, Sorvall legend XTR. Waltham, Massachusetts, USA.
20. Eppendorf Tubes. Sigma-Aldrich, St Louis, Minnesota, USA.
21. Beuthanasia-D Special. Intervet INC, Madison, New Jersey, USA.
22. Morphine Specific Direct ELISA, Bio-Quant, San Diego, California, USA.
23. Phosphate Buffered Saline. OminPur 10x Liquid Concentrate, VWR, Visalia, California, USA. 137mM NaCl, 2.7mM Potassium Chloride, 10mM Phosphate buffer.
24. Thermo Scientific MultiSkan Go automated plate reader.
25. Thermo Scientific Skanit Software version 3.2.
26. www.myassays.com: Four Parameter Logistic Fit.
27. SigmaStat 2.0. SPSS Inc, Chicago, Illinois, USA.
28. Excel Spreadsheet. Microsoft Office 2011.

References

- Acheampong, A. A., Small, D., Baumgarten, V., Welty, D., Tang-Liu, D. (2002). "Formulation Effects on Ocular Absorption of Brimonidine in Rabbit Eyes." Journal of Ocular Pharmacology and Therapeutics **18**(4): 325-337.
- Annear, M. J., Gemensky-Metzler, A.J., Wilkie, D.A. (2012). "Uveitic glaucoma in the horse." Equine Veterinary Education **24**(2): 97-105.
- Aquino, S., van der Woerd, A., Eaton, J.S. (2005). "The effect of topical nalbuphine on corneal sensitivity in normal canine eyes." Proc Am Coll Vet Ophthalmol **36**(43).
- Barnhart, M. D., Hubbell, J.A.E., Muir, W.W., Sams, R.A., Bednarski, R.M. (2000). "Pharmacokinetics, pharmacodynamics and analgesic effects of morphine after rectal, intramuscular and intravenous administration in dogs." American Journal of Veterinary Research **61**(1): 24-28.
- Barrett, K. E., Barman, S.M., Boitano, S., Brooks, H.L. (2012). Ganong's Review of Medical Physiology, McGraw-Hill.
- Barrett, P. M., Scagliotti, R.H., Merideth, R.E., Jackson, P.A., Alarcon, F.L. (1991). "Absolute Corneal Sensitivity and Corneal Trigeminal Nerve Anatomy in Normal Dogs." Progress in Veterinary and Comparative Ophthalmology **1**(4): 245-254.
- Beckwith-Cohen, B., Elad, D., Bdolah-Abram, T., Ofri, R. (2014). "Comparison of tear pH in dogs, horses and cattle." American Journal of Veterinary Research **75**(5): 494-499.
- Bennett, R. C., Steffey, E.P. (2002). "Use of opioids for pain and anesthetic management in horses." Veterinary Clinics of North America: Equine **18**: 47-60.
- Binder, D. R., Herring, I.P. (2006). "Duration of corneal anesthesia following topical administration of 0.5% proparacaine hydrochloride solution in clinically normal cats. ." American Journal of Veterinary Research **67**(10): 1780-1782.
- Boscan, P., Van Hoogmoed, L.M., Farver, T.B., Snyder, J.R. (2006). "Evaluation of the effects of the opioid agonist morphine on gastrointestinal tract function in horses." American Journal of Veterinary Research **67**(6): 992-997.
- Brooks, D. E. (2012). "Calcium degeneration and ocular surface failure in the horse." Equine Veterinary Education **24**(1): 8-11.
- Brooks, D. E., Clark, C.K., Lester, G.D. (2000). "Cochet-Bonnet aesthesiometer determined corneal sensitivity in neonatal foals and adult horses." Veterinary Ophthalmology **3**: 133-137.
- Burford, J. H., Corley, K.T. (2006). "Morphine-associated pruritis after single extradural administration in a horse." Veterinary Anaesthesia and Analgesia **33**: 193-198.
- Burstein, N. L., Anderson, J.A. (1985). "Review: Corneal Penetration and Ocular Bioavailability of Drugs." Journal of Ocular Pharmacology and Therapeutics **1**(3): 309-326.
- Bussieres, G., Jacques, C., Lainay, O., Beauchamp, G., Leblond, A. Cadore, J.L., Desmaizieres, L.M., Cuveilliez, S.G., Troncy, E. (2008). "Development of a composite orthopaedic pain scale in horses. ." Research in Veterinary Science **85**: 294-306.

- Buus Frost, A., Lindegaard, C., Larsen, F., Ostergaard, J., Weng Larsen, S., Larsen, C. (2011). "Intra-articular injection of morphine to the horse: establishment of an in vitro-in vivo relationship." Drug Development and Industrial Pharmacy **37**(9): 1043-1048.
- Carney, L. G., O'Leary, D.J., Millodot, M. (1984). "Effect of topical anaesthesia on corneal epithelial fragility." International Ophthalmology **7**: 71-73.
- Caspi, R. R. (2013). "Immunology of the eye-Inside and Out." Int Rev Immunol **32**(1): 1-3.
- Caudle, L. E., Williams, K.A., Pesudovs, K. (2007). "The eye sensation scale: an ophthalmic pain severity measure." Optometry and Vision Science **84**(8): 752-762.
- Chan-Ling, T. (1989). "Sensitivity and Neural Organization of the Cat Cornea." Investigative Ophthalmology and Visual Science **30**(6): 1989.
- Chast, F., Bardin, C., Sauvageon-Martre, H., Callaert, S., Chaumeil, J-C. (1991). "Systemic Morphine Pharmacokinetics after Ocular Administration." Journal of Pharmaceutical Sciences **80**(10): 911-917.
- Childers, R., Everson, R., Hooser, S.B (1995). "Use of Ocular Fluids and Retina in Postmortem Analysis." Retrieved 4/27/2016, 2016, from <https://www.addl.purdue.edu/newsletters/1995/ocular.shtml>.
- Clark, J. S., Bentley, E., Smith, L.J. (2011). "Evaluation of topical nalbuphine or oral tramadol as analgesics for corneal pain in dogs: a pilot study. ." Veterinary Ophthalmology **14**(6): 358-364.
- Clark, L., Clutton, R.E., Blissitt, K.J., Chase-Topping, M.E. (2005). "Effects of peri-operative morphine administration during halothane anaesthesia in horses." Veterinary Anaesthesia and Analgesia **32**: 10-15.
- Clutton, R. E. (2010). "Opioid Analgesia in Horses." Veterinary Clinics of North America. Equine **26**: 493-514.
- Dahlstrom, B., Tamsen, A., Paalzow, L. (1982). "Patient Controlled ANalgesic Therapy, Part IV: Pharmacokinetics and Analgesic PLasma Concentrations of Morphine. ." Clin Pharmacokinet **7**: 266-279.
- Devine, E. P., KuKanich, B., Beard, W.L. (2013). "Pharmacokinetics of intramuscularly administered morphine in horses. ." Journal of the American Veterinary Medical Association **1**: 105-112.
- Faktorovich, E. G., Basbeum, A.I. (2010). "Effect of Topical 0.5% Morphine on Postoperative Pain after Photorefractive Keratectomy." Journal of Refractive Surgery **26**(12): 934-941.
- Fanciullacci, M., Cangi, F., Gatto, G., Boccuni, M., Pietrini, U. (1984). "Morphine eye-drops reduce homatropine induced mydriasis in man." Experientia **40**: 731-733.
- Figueiredo, J. P., Muir, W.W., Sams, R. (2012). "Cardiorespiratory, gastrointestinal and analgesic effects of morphine sulfate in conscious healthy horses." American Journal of Veterinary Research **73**(6): 799-807.
- Freitas, G. C., Carregaro, A.B., Gehrcke, M.I, De La Corte, F.D., Lara, V.M., Pozzobon, R., Brass, K.E. (2011). "Epidural analgesia with morphine or buprenorphine in ponies with lipopolysaccharide (LPS)-induced carpal synovitis. ." Canadian Journal of Veterinary Research **75**(2): 141-146.
- Gilger, B. C. (2012). "The Search for causes of nonhealing or recurrent ulcerative keratitis in horses." Equine Veterinary Education **24**(11): 561-562.
- Gilger, B. C., Clode, A.B, Matthews, A. (2011). Equine Ophthalmology: Diseases and Surgery of the Cornea, Saunders.

Gilger, B. C., Davis, J.L. (2011). Equine Ophthalmology: Ocular Manifestations of Systemic Disease, Saunders.

Gilger, B. C., Deeg, C. (2011). Equine Ophthalmology: Equine Recurrent Uveitis, Saunders.

Gilger, B. C., Stoppini, R. (2011). Equine Ophthalmology: Equine Ocular Examination: Routine and Advance Diagnostic Techniques, Saunders.

Gilger, B. C., Wilkie, D.A. (2011). Equine Ophthalmology: Diseases of the Ocular Posterior Segment, Saunders.

Gleerup, K. B., Forkman, B., Lindegaard, C., Andersen, P.H. (2014). "An Equine Pain Face." Veterinary Anaesthesia and Analgesia **42**: 103-114.

Gleerup, K. B., Lindegaard, C. (2016). "Recognition and quantification of pain in horses: A tutorial review." Equine Veterinary Education **28**(1): 47-57.

Golebiowski, B., Papas, E.B., Stapleton, F. (2008). "Factors affecting corneal sensitivity and conjunctival sensitivity measurement." Optometry and Vision Science **85**(4): 241-246.

Guedes, A. G. P., Knych, H.K., Soares, J.H.N., Brosnan, R.J. (2013). "Pharmacokinetics and physiological effects of repeated oral administrations of tramadol in horses." Journal of Veterinary Pharmacology and Therapeutics **37**: 269-278.

Guidera, A. C., Luchs, J.I., Udell, I.J. (2000). "Keratitis, Ulceration and Perforation Associated with Topical Nonsteroidal Anti-inflammatory Drugs." Ophthalmology **108**: 936-944.

Habacher, G., Pittler, M.H., Ernst, E. (2006). "Effectiveness of Acupuncture in Veterinary Medicine: Systematic Review." Journal of Veterinary Internal Medicine **20**: 480-488.

Hellyer, P. W., Bai, L., Supon, J., C.Quail, C., Wagner, A.E., Mama, K.R., Magnusson, K.R. (2003). "Comparison of opioid and alpha-2 adrenergic receptor binding in horse and dog brain using radioligand autoradiography." Veterinary Anaesthesia and Analgesia **30**: 172-182.

Hendrix, D. V. H., Ward, D.A., Barnhill, M.A. (2002). "Effects of anti-inflammatory drugs and preservatives on morphologic characteristics and migration of canine corneal epithelial cells in tissue culture." Veterinary Ophthalmology **5**(2): 127-135.

Henriksen, M. D. L., Andersen, P.H., Pummer, C.E., Mangan, B., Brooks, D.E. (2013). "Equine Corneal Stromal Abscesses: An Evolution in the understanding of pathogenesis and treatment during the past 30 years." Equine Veterinary Education **25**(6): 315-323.

Herring, I. P., Bobofchak, M.A., Landry, M.P., Ward, D.L. (2005). "Duration of effect and effect of multiple doses of topical ophthalmic 0.5% proparacaine hydrochloride in clinically normal dogs. ." American Journal of Veterinary Research **66**(1): 77-80.

Hilton, H. G., Magdesian, K.G., Groth, A.D., Knych, H., Stanley, S.D., Hollingsworth, S.R. (2011). "Distribution of Flunixin Meglumine and Firocoxib into Aqueous Humor of Horses." Journal of Veterinary Internal Medicine **25**: 1127-1133.

Hunter, B. G., Parker, J.E., Wehrman, R., Stang, B., Cebra, C.K. (2015). "Morphine Synovial Fluid Concentrations After Intravenous Regional Limb Perfusion in Standing Horses." Veterinary Surgery **44**: 679-686.

Joris, J. L., Dubner, R., Hargreaves, K.M. (1987). "Opioid Analgesia at Peripheral Sites." Anesthesia and Analgesia **66**: 1277-1281.

Kalchofner, K. S., Kummer, M., Price, J., Bettschart-Wolfensberger, R. (2007). "Pruritis in two horses following epidurally administered morphine." Equine Veterinary Education **19**(11): 590-594.

Kalf, K. L., Utter, M.E., Wotman, K.L. (2008). "Evaluation of duration of corneal anesthesia induced with ophthalmic 0.5% proparacaine hydrochloride by use of a Cochet-Bonnet aesthesiometer in clinically normal horses." American Journal of Veterinary Research **69**(12).

Kaps, S., Richter, M., Spiess, B.M. (2003). "Corneal Esthesiometry in th Healthy Horse." Veterinary Ophthalmology **6**(2): 151-155. .

Kaur, I. P., Gag, A., Singla, A.K., Aggarwal, A. (2004). "Vesicular systems in ocular drug delivery: an overview." International Journal of Pharmaceutics **269**: 1-14.

Klepstad, P., Dale, O., Kaasa, S., Zahlsen, K., Aamo, T., Fayers, P., Borchgrevnik, P.C. (2003). "Influences on Serum Concentrations of Morphine, M6G and M3G during Routine Clinical Drug Monitoring: A Prospective Survey in 300 Adult Cancer Patients. ." Acta Anaesthesiol Scand **47**: 725-731.

Knych, H. K., Steffey, E.P., Mckemie, D.S. (2013). "Preliminary pharmacokinetics of morphine and its major metabolites following intravenous administration of four doses to horses." Journal of Veterinary Pharmacology and Therapeutics **37**: 374-381.

Komaromy, A. M., Garg, C.D., Ying, G.S. (2006). "Effect of head position on intraocular pressure in horses." American Journal of Veterinary Research **67**: 1232-2006.

Kramer, S. G. (1980). "Corneal Cytotoxicity of Topically Applied Drugs, Vehicles and Preservatives." Survey of Ophthalmology **25**(1): 15-26.

Kruger, L. (2001). Methods in Pain Research, CRC Press.

Labelle, A. L., Clark-Price, S.C. (2013). "Anesthesia for Ophthalmic Procedures in the Standing Horse." Veterinary Clinics of North America: Equine **29**: 179-191.

Labelle, A. L., Hamor, R.E., Townsend, W.M., Mitchell, M.A., Zarfoss, M.K., Breaux, C.B., Thomasy, S.M., Hall, T. (2011). "Ophthalmic lesions in neonatal foals evaluated for nonophthalmic disease at referral hospitals." Journal of the American Veterinary Association **239**(4): 486-492.

Lacerda, R. P., Obon, E., Pena, M.T., Costa, D., Rios, J., Leiva, M (2014). "A Comparative study of corneal sensitivity in birds of prey." Veterinary Ophthalmology **17**(3): 190-194.

Lee, V. H. L., Robinson, J.R. (1986). "Review: Topical Ocular Drug Delivery: Recent Develoments and Future Challenges." Journal of Ocular Pharmacology **2**(1): 67-108.

Lindegaard, C., Gleerup, K.B., Thomsen, M.H., Martinussen, T., Jacobsen, S., Andersen, P.H. (2010). "Anti-inflammatory effects of intra-articular administration of morphine in horses with experimentally induced synovitis." American Journal of Veterinary Research **71**(1): 69-75.

Lindegaard, C., Vaabenggaard, D., Christophersen, M.T., Ekstom, C.T., Ejeldborg, J. (2009). "Evaluation of pain and inflammation associated with hot iron branding and microchip transponder injection in horses. ." American Journal of Veterinary Research **70**: 840-847.

Love, E. J., Lane, J.G, Murison, P.J. (2006). "Morphine administration in horses anaesthetized for upper respiratory tract surgery." Veterinary Anaesthesia and Analgesia **33**: 179-188.

Lwigale, P. Y., Bronner-Fraser, M. (2007). "Lens-derived Semaphorin3A regulates senosry innervation of the cornea." Developmental Biology **306**: 750-759.

- M.Millodot (1973). "Objective Measurement of Corneal Sensitivity." Acta Ophthalmologica **51**: 325-334.
- Ma, J., Zhang, Y., Kalyuzhny, A.E., Pan, Z.Z. (2006). "Emergence of functional delta-opioid receptors induced by long-term treatment with morphine." Molecular Pharmacology **69**: 1137-1145.
- Mama, K. R., Pascoe, P.J., Steffey, E.P. (1992). "Evaluation of the interaction of Mu and Kappa Opioid Agonists on Locomotor Behavior in the Horse." Canadian Journal of Veterinary Research **57**: 106-109.
- Marfurt, C. F., Murphy, C.J., Florczak, J.L. (2001). "Morphology and Neurochemistry of Canine Corneal Innervation." Investigative Ophthalmology and Visual Science **42**(10): 2242-2250.
- Marr, W. G., Wood, R., Senterfit, L., Sigelman, S. (1957). "Effect of Topical Anesthetics on Regeneration of Corneal Epithelium." American Journal of Ophthalmology **43**(4): 606-610.
- Martins, B. C., Brooks, D.E. (2012). "Subconjunctival drug administration in horses." Equine Veterinary Education **24**(10): 493-495.
- McGee, H. T., Fraunfelder, F.W. (2007). "Toxicities of topical ophthalmic anesthetics." Expert Opinion Drug Safety **6**(6): 637-640.
- Menozzi, A., Pozzoli, C., Zullian, C., Poli, E., Serventi, P., Bertini, S. (2012). "Inhibition of motility in isolated horse small intestine is mediated by k but not u opioid receptors." Equine Veterinary Journal **44**: 368-370.
- Miller, C., Utter, M.L., Beech, J. (2013). "Evaluation of the effects of age and pituitary pars intermedia dysfunction on corneal sensitivity in horses." American Journal of Veterinary Research **74**(7): 1030-1035.
- Millodot, M. (1977). "The influence of age on the sensitivity of the cornea." Investigative Ophthalmol Visual Sci: 240-242.
- Monclin, S. J., Farnir, F., Grauwels, M. (2011). "Determination of tear break-up time reference values and ocular tolerance of tetracaine hydrochloride eyedrops in healthy horses." Equine Veterinary Journal **43**(1): 74-77.
- Muir, W. W. (2010). "Pain: Mechanisms and Management in Horses." Veterinary Clinics of North America: Equine **26**: 467-480.
- Naderland, M. H., Riis, R.C., Rebhun, W.C., Erb, H.N. (1987). "Healing of experimentally induced corneal ulcers in horses. ." American Journal of Veterinary Research **48**: 427-430.
- Pate, D. O., Clode, A.B., Olivry, T., Cullen, J.M., Salmon, J.H., Gilger, B.C. (2012). "Immunohistochemical and immunopathologic characterization of superficial stromal immune-mediated keratitis in horses. ." American Journal of Veterinary Research **73**(7): 1067-1073.
- Patipa, L. A., Sherlock, C.E., Witte, S.H., Pirie, G.D., Berghaus, R.D., Peroni, J.F. (2012). "Risk factors for colic in equids hospitalized for ocular disease." Journal of the American Veterinary Association **240**(12): 1488-1493.
- Peyman, G. A., Rahimy, M.H., Fernandes, M.L. (1994). "Effects of morphine on corneal sensitivity and epithelial wound healing: implications for topical ophthalmic analgesia." British Journal of Ophthalmology. **78**: 138-141.
- Peyman, G. A., Rahimy, M.H., Fernandes, M.L. (1994). "Effects of morphine on corneal sensitivity and epithelial wound healing: implications for topical ophthalmic analgesia. ." British Journal of Ophthalmology. **78**: 138-141.

Pirie, C. G., Alario, A.F., Barysaukas, C.M., Gradil, C., Uricchio, C.K. (2014). "Manual corneal thickness measurements of healthy equine eyes using a portable spectral-domain optical coherence tomography device. ." Equine Veterinary Journal **46**: 631-634.

Plumb, D. C. (2011). Plumb's Veterinary Drug Handbook. Stockholm, Wisconsin, Wiley-Blackwell.

Pucket, J. D., Allbaugh, R.A., Rankin, A.J., Q.Ou., Bello, N.M. (2013). "Comparison of efficacy and duration of effect on corneal sensitivity among anesthetic agents following ocular administration in clinically normal horses." American Journal of Veterinary Research **74**(3): 459-464.

Raekallio, M., Taylor, P.M., Bennett, R.C. (1997). "Preliminary investigations of pain and analgesia assessment in horses administered phenylbutazone or placebo after arthroscopic surgery. ." Veterinary Surgery **26**: 150-155.

Ramselaar, J. A. M., Boot, J.P., van Haeringen, N.J., van Best, J.A., Oosterhuis, J.A. (1988). "Corneal epithelial permeability after installation of ophthalmic solutions containing local anesthetics and preservatives." Current Eye Research **7**(9): 947-950.

Ramsey, D., Hauptman, J., Petersen-Jones, S. (1999). "Corneal thickness, intraocular pressure, and optical corneal diameter in Rocky Mountain horses with cornea globosa or clinically normal corneas." American Journal of Veterinary Research **60**: 1317-1321.

Ribeiro, A. P., Silva, M.L., Araujo, R.L., Ferrucci, D.L., Mineo, T., Thiesen, R., Bandarra, M.B., Laust, J.L. (2012). "Expression of matrix metalloproteinases, type IV collagen and interleukin-10 in rabbits treated with morphine after lamellar keratectomy." Veterinary Ophthalmology **15**(3).

Robertson, S. A. (2004). "Standing sedation and pain management for ophthalmic patients." Veterinary Clinics of North America: Equine **20**: 485-497

Robertson, S. A., Sanchez, L.C. (2010). "Treatment of Visceral Pain in Horses." Veterinary Clinics of North America: Equine **26**: 603-617.

Rozsa, A. J., Beuerman, R.W. (1982). "Density and Organization of Free Nerve Endings in the Corneal Epithelium of the Rabbit." Pain **14**: 105-120.

Sanchez, L. C., Robertson, S.A. (2014). "Pain Control in Horses: What do we really know?" Equine Veterinary Journal **46**: 517-523.

Sasaki, H., Yamamura, K., Nishida, K., Nakamura, J., Ischikawa, M. (1996). "Delivery of Drugs to the Eye by Topical Application." Progress in Retinal and Eye Research **15**(2): 583-620.

Schoenwald, R. D., Deshpande, G.S., Rethwisch, D.G., Barfknecht, C.F. (1997). "Penetration into the Anterior Chamber Via the COnjunctival/Scleral Pathway." Journal of Ocular Pharmacology and Therapeutics **13**(1): 41-51.

Schramm, C. L., Honda, C.N. (2010). "Co-administration of delta and mu-opioid receptor agonists promotes peripheral opioid receptor function." Pain **151**: 763-770.

Sharrow-Reabe, K. L., Townsend, W.M. (2012). "Effects of action of proparacaine and tetracaine topical ophthalmic formulations on corneal sensitivity in horses." Journal of the American Veterinary Association **241**(12): 1645-1649.

Sheehy, J. G., Hellyer, P.W., Sammonds, G.E., Mama, K.R., Powers, B.E., Hendrickson, D.A., Magnusson, K.R. (2001). "Evaluation of opioid receptors in synovial membranes of horses." American Journal of Veterinary Research **62**(9): 1408-1412.

Shimazaki, J., Saito, H., Yang, H-Y., Toda, I., Fujishima, H., Tsubota., K (1995). "Persistent Epithelial Defect Following Penetrating Keratoplasty: An Adverse Effect of Diclofenac Eyedrops." Cornea **14**(6): 623-627.

Siegner, S. W., Giovanoni, R.L., Erickson, K.A., Netland, P.A. (1998). "Distribution of Verapamil and Norverapamil in the Eye and Systemic Circulation After Topical Administration of Verapamil in Rabbits." Journal of Ocular Pharmacology and Therapeutics **14**(2): 1998.

Silva, M. L., Piso, D.Y.L., Ribiero, A.P., Laus, J.L. (2012). "Topical 1% Nalbuphine on corneal sensitivity and epithelization after experimental lamellar keratectomy in rabbits." Ciencia Rural, Santa Maria **42**(4).

Stein, C., Millan, M.J., Shippenberg, T.S., Herz, A. (1988). "Peripheral effect of fentanyl upon nociception in inflamed tissue of the rat." Neuroscience Letters **84**: 225-228. .

Stein, C., Millan, M.J., Shippenberg, T.S., Peter, K., Herz, A. (1988). "Peripheral Opioid Receptors Mediating Antinociception in Inflammation. Evidence for involvement of Mu, Delta and Kappa receptors." The Journal of Pharmacology and Experimental Therapeutics **248**(3): 1269-1275.

Stein, C., Pfluger, M., Yassouridis, A. (1996). "No Tolerance to Peripheral Morphine Analgesia in Presence of Opioid Expression in Inflamed Synovia." Journal of Clinical Investigation **98**: 793-799.

Stiles, J., Honda, C., Krohne, S.G., Kazacos, E.A. (2003). "Effect of topical administration of 1% morphine sulfate solution on signs of pain and corneal wound healing in dogs. ." American Journal of Veterinary Research **7**: 813-818.

Stiles, J., Honda, C.N., Krohne, S.G., Kazacos, K.A. (2003). "Effect of topical administration of 1% morphine sulfate solution on signs of pain and corneal wound healing in dogs." American Journal of Veterinary Research **64**(7): 2003.

Thomasy, S. M., Moeller, B.C., Stanley, S.D. (2007). "Comparison of opioid receptor binding in horse, guinea pig, and rat cerebral cortex and cerebellum." Veterinary Anaesthesia and Analgesia **34**: 351-358.

Thomson, S. M., Oliver, J.A., Gould, D.J., Mendl, M., Leece, E.A. (2013). "Preliminary investigations into the analgesic effects of topical ocular 1% morphine solution in dogs and cats. ." Veterinary Anesthesia and Analgesia.: 1-9.

van Loon, J. P. A. M., de Grauw, J.C., A.Brunott, A., Weerts, E.A.W.S., van Weeren, P.R. (2013). "Upregulation of articular synovial membrane mu-opioid-like receptors in an acute equine synovitis model." The Veterinary Journal **196**: 40-46.

Weed, M. R., Hienz, R.D. (2006). "Effects of Morphine on Circadian Rhythms of Motor Activity and Body Temperature in Pig-Tailed Macaques." Pharmacology, Biochemistry and Behavior **84**: 487-496.

Wenk, H. N., Honda, C.N. (1999). "Immunohistochemical Localization of Delta Opioid Receptors in Peripheral Tissues." The Journal of Comparative Neurology **408**: 567-579.

Wenk, H. N., Nannenga, M.N., Honda, C.N. (2003). "Effect of morphine sulphate eye drops on hyperalgesia in the rat cornea." Pain **105**: 455-465.

Westermeyer, H. D., Hendrix, D.V.H., Ward, D.A., Cox, S.K. (2011). "Tear, cornea and aqueous humor concentrations of ciprofloxacin and moxifloxacin after topical ocular application in ophthalmologically normal horses." American Journal of Veterinary Research **72**(3): 398-403.

Wieser, B., Tichy, A., Nell, B. (2013). "Correlation between corneal sensitivity and quantity of reflex tearing in cows, horses, goats, sheep, dogs, cats, rabbits and guinea pigs." Veterinary Ophthalmology **16**(4): 251-262.

Williams, D. L. (2010). "Welfare Issues in Farm Animal Ophthalmology." Veterinary Clinicals of North America. Food Animal **26**: 427-435.

Williams, M. M., Spiess, B.M, Pascoe, P.J, O'Grady, M. (2000). "Systemic effects of topical and subconjunctival ophthalmic atropine in the horse." Veterinary Ophthalmology **3**(2): 193-199.

Wong, D. M., Davis, J.L., White, N.A. (2011). "Motility of the equine gastrointestinal tract: Physiology and pharamacotherapy." Equine Veterinary Journal **23**(2): 88-100.

Wotman, K. L., Utter, M.E. (2010). "Effect of treatment with a topical ophthalmic preparation of 1% nalbuphine solution on corneal sensitivity in clinically normal horses." American Journal of Veterinary Research **71**(2): 223-228.

Zhou, R., Caspi, R.R. (2010). "Ocular Immune Privilege." Biol Rep **2**(3).

Zollner, C., Mousa, S., Klinger, A., Forster, M., Schafer, M. (2008). "Topical fentanyl in a randomized, double-blind study in patients with corneal damage." Clinical Journal of Pain **24**(8): 690-696.