

Atypical presentation of pseudomembranous colitis localized in adenomatous polyps

Cristian Hernández-Rocha, Jonathan Barra-Carrasco, Ana María Guzmán, Daniel Paredes-Sabja, Gabriel Lezcano, Pablo Zoroquiain, Manuel Álvarez-Lobos

Cristian Hernández-Rocha, Manuel Álvarez-Lobos, Department of Gastroenterology, Faculty of Medicine, Pontificia Universidad Católica de Chile, Marcoleta 367, Santiago 6510260, Chile
Jonathan Barra-Carrasco, Daniel Paredes-Sabja, Laboratory of Mechanisms of Bacterial Pathogenesis, Department of Biological Sciences, Faculty of Biological Sciences, Universidad Andrés Bello, Santiago 6618000, Chile

Ana María Guzmán, Department of Clinical Laboratory, Faculty of Medicine, Pontificia Universidad Católica de Chile, Marcoleta 367, Santiago 6510260, Chile

Gabriel Lezcano, Pablo Zoroquiain, Department of Anatomopathology, Faculty of Medicine, Pontificia Universidad Católica de Chile, Marcoleta 367, Santiago 6510260, Chile

Daniel Paredes-Sabja, Department of Biomedical Sciences, College of Veterinary Medicine, Oregon State University, Corvallis, OR 97333, United States

Author contributions: Hernández-Rocha C, Barra-Carrasco J, Guzman AM, Paredes-Sabja D and Álvarez-Lobos M wrote the paper; Lezcano G and Zoroquiain P reviewed the histopathological slides.

Correspondence to: Dr. Manuel Álvarez-Lobos, Department of Gastroenterology, Faculty of Medicine, Pontificia Universidad Católica de Chile, Marcoleta 367, Santiago, Chile. manalvarezl@gmail.com

Telephone: +56-2-3543820 Fax: +56-2-6397780

Received: July 17, 2012 Revised: September 30, 2012

Accepted: October 16, 2012

Published online: January 14, 2013

Abstract

The most frequent cause of pseudomembranous colitis is *Clostridium difficile* (*C. difficile*) infection. This type of colitis is characterized by an endoscopic pattern of numerous small, yellowish or whitish plaques diffusely distributed, which typically compromises the rectum extending to proximal colon. Occasionally, the pseudomembranes compromise only the transverse or right colon, but their exclusive localization over polyps has not been reported. In this case report we have described a patient with symptoms compatible with *C. difficile* infection and positive for *C. difficile* toxigenic culture.

Colonoscopy examination showed two small polyps with a whitish surface, and histopathological analysis confirmed them to be pseudomembranes over tubular adenomas. The rest of the colonic mucosa was normal and no other cause was demonstrated. We suggest that this particular distribution might be due to a higher affinity for dysplastic cells such as adenomatous polyps of colon by *C. difficile* and/or its toxins.

© 2013 Baishideng. All rights reserved.

Key words: *Clostridium difficile*; Pseudomembranous colitis; Adenomatous polyps; Antibiotic-associated colitis; *Clostridium difficile* infections

Hernández-Rocha C, Barra-Carrasco J, Guzmán AM, Paredes-Sabja D, Lezcano G, Zoroquiain P, Álvarez-Lobos M. Atypical presentation of pseudomembranous colitis localized in adenomatous polyps. *World J Gastroenterol* 2013; 19(2): 316-318 Available from: URL: <http://www.wjgnet.com/1007-9327/full/v19/i2/316.htm> DOI: <http://dx.doi.org/10.3748/wjg.v19.i2.316>

INTRODUCTION

The clinical spectrum of *Clostridium difficile* (*C. difficile*) infections may vary from mild diarrhea to life-threatening pseudomembranous colitis (PMC), which may localize from the proximal colon to the rectum^[1]. Localized forms of PMC have been reported to compromise the transverse and right colon^[2], but to the best of our knowledge, we have not found cases with exclusive localization of PMC over polyps. Below, we report a case with the pseudomembranes only covering the surface of adenomatous polyps.

CASE REPORT

An 86-year-old female receiving anticoagulant therapy due

to an aortic valve prosthesis with auricular fibrillation secondary to aortic stenosis was admitted with an incarcerated umbilical hernia. A hernioplasty was performed without complication, and she was treated with sodium piperacillin-tazobactam (4.5 g *tid*) intravenously for 7 d and discharged 10 d after surgery. Twenty-five days later, she presented hematochezia with hemodynamic compromise. She was admitted to the coronary unit, and an upper endoscopy showed a hiatal hernia with Cameron's ulcers; she was treated with omeprazole. The next day a colonoscopy showed a clean colonic mucosa, absence of blood, and two sessile 6-mm polyps in the transverse colon and in the right colon. The upper surface of both polyps was covered by an adherent and whitish layer and the surrounding mucosa was normal (Figure 1). The polyps were resected with cold biopsy forceps and sent for histopathological study. Strikingly, the day after colonoscopy, the patient developed fever with no apparent cause in the physical exam, while laboratory results showed a hematocrit of 29%, white blood cell count of 8700 cell/ μ L without band forms and C reactive protein was 10.2 mg/dL. The chest X-ray was normal and the blood and urine cultures were negative. She was empirically treated with sodium piperacillin-tazobactam, but three days later she presented frequent loose stools and diffuse abdominal pain. An enzyme immune assay (EIA) for *C. difficile* toxin was positive. The antibiotic was stopped and she was treated with oral metronidazole with an excellent response. Presence of *C. difficile* was further confirmed by real time-polymerase chain reaction (PCR) and toxigenic culture. PCR-ribotyping indicated that the clinical isolate that caused *C. difficile* infection was not an epidemic strain (non-ribotype 027 strain). A few days later, the histopathological study of the polyps showed two tubular adenomas with a low-grade epithelial dysplasia and pseudomembranes on their surface with a typical volcanic appearance (Figure 2).

DISCUSSION

It is our understanding that this is the first documented case in which the pseudomembranes are exclusively localized over adenomatous polyps with the rest of the colonic mucosa being intact. The term PMC is nonspecific and describes an acute mucosal injury characterized by an endoscopic pattern of numerous, discrete and small (2-5 mm), raised, round and yellowish plaques (pseudomembranes) distributed over an erythematous but un ulcerated mucosa^[1]. The rectum is frequently involved, but in a few cases the sigmoid and/or right colon is compromised^[2]. The histological pattern is characterized by a neutrophil-rich edema fluid in the lamina propria that bursts through tiny breaches to the surface epithelium, like a volcanic eruption, to form a characteristic punctate inflammatory pseudomembrane^[1,3]. The PMC is due, in nearly all cases, to *C. difficile*. Other infrequent causes are ischemic or infectious colitis^[4]. Piperacillin-tazobactam has been associated at lower rates with *C. difficile* infection than other antibiotics^[5]; however, in this case report, the

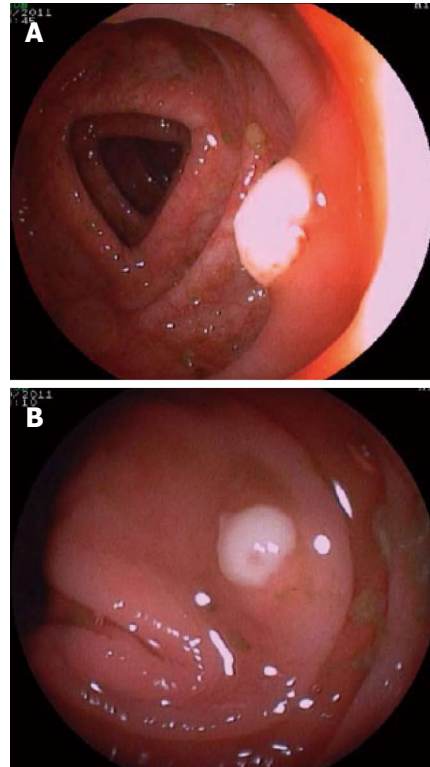


Figure 1 Colonoscopy images showing two polyps, 4 and 6 mm in size, in the right colon with adherent whitish surface. A: Polyp of 6 mm; B: Polyp of 4 mm. The mucosa round the polyps and in the rest of colon is normal.

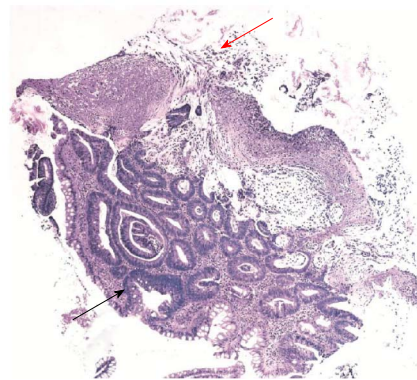

Figure 2 Low power view of a mucosal fragment. Histopathology shows: at the bottom, tubular structures lined by columnar epithelial cells with pseudostratified nuclei, consistent with low grade tubular adenoma (black arrow); at the top, ballooned crypts and intercrypt necrosis, an exudate featuring the classical "volcano" lesion (red arrow) surrounded by a laminated pseudomembrane composed of neutrophils, mucin and fibrin (hematoxylin and eosin, x 100).

clinical course and the study with EIA, PCR and toxigenic culture confirmed an association with *C. difficile* and the response to treatment with oral metronidazole was concordant.

The specific type of colonic cells where *C. difficile* infections starts is unclear, but it is known that at least enterotoxin A, one of its main virulence factors, has remarkable cytotoxicity for cells derived from human or animal cancer, more than for normal colonic epithelial

cells. One possible explanation, but by no means proven, is that the surface of neoplastic cells possesses a greater density of specific receptors for toxin A and/or toxin B as compared to less sensitive cell lines^[6]. Alternatively, it is well known that members of the *Clostridium* genus have a tropism for tumors mainly due to the hypoxic environment as a consequence of poor vascular irrigation^[7,8]. Thus, it seems plausible that colonic neoplastic cells might favor *C. difficile* colonization and PMC formation.

In conclusion, we propose that dysplastic changes of the colonic epithelium occurring as adenomatous polyps might represent a site of greater affinity for *C. difficile* toxin and/or tropism of *C. difficile* cells with the consequent formation of pseudomembranes, which were observed by an early colonoscopy in this patient.

REFERENCES

- 1 **Carpenter HA**, Talley NJ. The importance of clinicopathological correlation in the diagnosis of inflammatory conditions of the colon: histological patterns with clinical implications. *Am J Gastroenterol* 2000; **95**: 878-896 [PMID: 10763932 DOI: S0002-9270(00)00716-4]
- 2 **Tedesco FJ**, Corless JK, Brownstein RE. Rectal sparing in antibiotic-associated pseudomembranous colitis: a prospective study. *Gastroenterology* 1982; **83**: 1259-1260 [PMID: 7129030 DOI: S0016508582002509]
- 3 **Price AB**, Davies DR. Pseudomembranous colitis. *J Clin Pathol* 1977; **30**: 1-12 [PMID: 838865 DOI: 10.1136/jcp.30.1.1]
- 4 **Bartlett JG**. Clinical practice. Antibiotic-associated diarrhea. *N Engl J Med* 2002; **346**: 334-339 [PMID: 11821511 DOI: 10.1056/NEJMcp011603]
- 5 **Mendez MN**, Gibbs L, Jacobs RA, McCulloch CE, Winston L, Guglielmo BJ. Impact of a piperacillin-tazobactam shortage on antimicrobial prescribing and the rate of vancomycin-resistant enterococci and *Clostridium difficile* infections. *Pharmacotherapy* 2006; **26**: 61-67 [PMID: 16509027]
- 6 **Kushnaryov VM**, Redlich PN, Sedmak JJ, Lyerly DM, Wilkins TD, Grossberg SE. Cytotoxicity of *Clostridium difficile* toxin A for human colonic and pancreatic carcinoma cell lines. *Cancer Res* 1992; **52**: 5096-5099 [PMID: 1516066]
- 7 **Wei MQ**, Ren R, Good D, Anné J. Clostridial spores as live 'Trojan horse' vectors for cancer gene therapy: comparison with viral delivery systems. *Genet Vaccines Ther* 2008; **6**: 8 [PMID: 18279524 DOI: 10.1186/1479-0556-6-8]
- 8 **Minton NP**. Clostridia in cancer therapy. *Nat Rev Microbiol* 2003; **1**: 237-242 [PMID: 15035028 DOI: 10.1038/nrmicro777]

P-Reviewer Chiarioni G **S-Editor** Gou SX **L-Editor** Logan S
E-Editor Zhang DN

